

CASE REPORT

Metastatic adamantinoma responds to treatment with receptor tyrosine kinase and Aurora A kinase inhibitor

Imran Unal¹, Odile David², Arkadiusz Z. Dudek³

1. Cancer Center, University of Illinois at Chicago, Chicago, Illinois, USA. 2. Department of Pathology, College of Medicine, University of Illinois at Chicago, Chicago, Illinois, USA. 3. Division of Hematology/Oncology, College of Medicine, University of Illinois at Chicago, Chicago, Illinois, USA.

Correspondence: Arkadiusz Z. Dudek, MD, PhD. Address: Division of Hematology/Oncology, College of Medicine Research Building, University of Illinois at Chicago, M/C 713, 909 S. Wolcott Ave. Chicago, IL 60612-3725, USA. Email: adudek@uic.edu

Received: February 12, 2015

Accepted: April 8, 2015

Online Published: May 14, 2015

DOI: 10.5430/jst.v5n2p27

URL: <http://dx.doi.org/10.5430/jst.v5n2p27>

Abstract

Adamantinoma is to be known as the one of the least common low-grade malignant bone tumors, commonly arising in the center of long bones, mostly in the tibial mid shaft. Adamantinomas are usually managed with wide local excision and reconstruction, unless unresectable or locally recurrent. Even though adamantinomas are managed as locally aggressive tumors, they usually recur and metastasize to sites including the lymph nodes, lungs, skeleton, liver and brain. Radiotherapy and chemotherapy do not seem to be effective treatment modalities for adamantinoma; recently published case reports suggest tyrosine kinase inhibitors as an alternative therapeutic strategy. We report a case of a patient with metastatic adamantinoma who progressed after first line therapy with doxorubicin and cisplatin, and responded to pazopanib (selective multi-targeted receptor tyrosine kinase inhibitor that inhibits angiogenesis) and alisertib (small molecule Aurora A kinase inhibitor) combination therapy. Tumor response to pazopanib and alisertib in combination as a third line therapy has led us to conclude that tyrosine kinase therapy could be considered in this setting.

Key words

Adamantinoma, Tyrosine kinase inhibitor, Pazopanib, Alisertib, Angiogenesis, Metastatic cancer

1 Introduction

Adamantinoma is to be known as the one of the least common low-grade malignant bone tumors, representing less than 1% of them. It usually starts in the center of long bones, particularly the tibial mid shaft known to be most commonly involved with the adamantinoma (80%-85%)^[1].

Adamantinomas eventually recur locally or distally. After 5 years of first line treatment, recurrence rate is reported to be 9% and after 10 years it is 18.6%^[2]. If initial excision is incomplete, recurrence rate reaches about 30%. The metastasis rate is reported to be around 10% to 20%, and lungs are most commonly affected^[3,4].

Initial treatment includes wide local excision combined reconstruction, and if the local tumor is unresectable or locally recurrent, extremity amputation may be considered^[5,6]. When adamantinomas recur years after treatment for primary

tumors, they are either a synchronous or metachronous metastatic lesions, and some of them respond to systemic chemotherapy [7, 8].

We report a case of a patient with metastatic adamantinoma who progressed after first line therapy with doxorubicin and cisplatin, and second line therapy, with experimental IGF-methotrexate conjugate, but responded to pazopanib (selective multi-targeted receptor tyrosine kinase inhibitor that inhibits angiogenesis) and alisertib (small molecule Aurora A kinase inhibitor that arrest cells in mitosis) combination therapy. It has been shown that at highest non-toxic concentrations, mitosis targeting agents may kill endothelial cells by reducing endothelial activity and consequently exhibit antiangiogenic activity [9].

2 Case presentation

A 33-year-old asymptomatic man presented 11 years ago with pain in his left lower extremity. He was found by magnetic resonance imaging (MRI) to have a lobulated heterogenous mass that destroyed and replaced his distal left fibula. A biopsy sample revealed an epithelioid neoplasm with a typical Basaloid and spindle cell pattern consistent with an adamantinoma diagnosis. He was treated with below-knee amputation of the left lower extremity. The patient was followed routinely with imaging studies, without adjuvant chemotherapy or radiotherapy. His clinical course was uneventful until March 2011, when he was found to have a lobulated, non-calcified anterior mediastinal mass revealed by computed tomography (CT) of the chest. Positron emission tomography-computed tomography (PET-CT) confirmed the presence of a mediastinal mass with high radionuclide uptake. A mediastinoscopy with excisional biopsy established the diagnosis of recurrence of adamantinoma (see Figure 1).

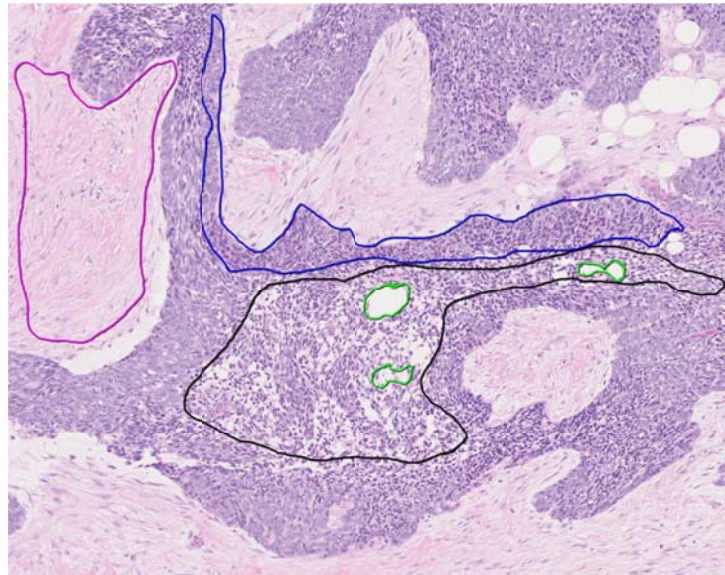


Figure 1. Section of resected mediastinal recurrence of adamantinoma. Figure demonstrates basaloid nests of tumor with peripheral palisading (representative area outlined in blue) and central regions (outlined in black) of smaller more uniform cells and microcystic change (microcysts outlined in green). The background consists of dense fibrous stroma (representative area outlined in pink). As expected of this malignancy, there is no significant nuclear pleomorphism. The basaloid pattern of adamantinoma is the classic pattern and most closely resembles that of ameloblastoma. Other patterns include spindle cell, tubular, and squamous. The prognosis of adamantinoma is unpredictable and histologic features do not seem to correlate with prognosis. (H+E, 100 × magnification)

Systemic chemotherapy was initiated with doxorubicin (25 mg/m²) and cisplatin (100 mg/m²) given every 21 days. His initial left ventricle ejection fraction (LVEF) measured with a multi-gated acquisition scan (MUGA) was 77%. He completed six cycles of doxorubicin and cisplatin therapy after documentation of maximal response (stable disease). He was followed with chest CT scans, and in March 2013, presented with a new pleural-based left lower lung mass. On the following PET-CT scan, increased activity in the left lung field as well as in his left second and posterior eight ribs was reported. CT-guided lung biopsy revealed recurrent adamantinoma. Since the patient responded well to previous doxorubicin and cisplatin chemotherapy, this same treatment was resumed. After cycle seven, the patient developed neutropenia and thrombocytopenia, and was started on prophylactic antibiotic therapy and peg-filgrastim. He continued the same regimen with 25% reduced dose of cisplatin and 20% reduced dose doxorubicin, due to neutropenic fever and

moderately decreased LVEF (to 59% on MUGA scan). He completed a total 12 cycles of doxorubicin and cisplatin that achieved stable disease as the best response achieved. Three months later, progressive disease was manifested by left sided anterior chest pain and back pain, and his chest CT scan revealed progressive disease in all areas.

Following a month, the patient was enrolled to phase I insulin-like growth factor 1 (IGF)-methotrexate conjugate therapy after the tumor was found to be type 1 insulin-like growth factor receptor (IGF-1R) positive. Treatment was discontinued after 2 cycles (each 21 days) of intravenous therapy, since he continued to have worsening chest pain, which was correlated with progressive disease on a chest CT scan in June, 2014. Due to hypercalcemia he started on zoledronic acid. An opioid analgesic and radiation therapy were given to treat anterior chest wall and back pain. After second-line therapy had failed, the patient consented to a phase I pazopanib (600 mg daily for 21 days) and alisertib (20 mg twice a day for 7 days) study and received a total of 5 (21 days) cycles of experimental oral treatment. Shortly after treatment was initiated, he reported symptom relief and a follow-up CT scan of the chest, abdomen, and pelvis in July, 2014 showed significant decreased central enhancement of metastasis in the lungs and chest wall (see Figure 2). Frequent alanine aminotransferase elevations led to treatment interruptions and delays, which caused him to be taken off the study as per study guidelines in November, 2014 and he could no longer receive alisertib. However due to significant improvement during pazopanib and alisertib combination therapy, the patient continued to receive single agent pazopanib treatment (600 mg) per day. He continues to have stable disease and tolerates single agent pazopanib therapy very well. However, pazopanib dose has been decreased to 400 mg due to mild fatigue and diarrhea.

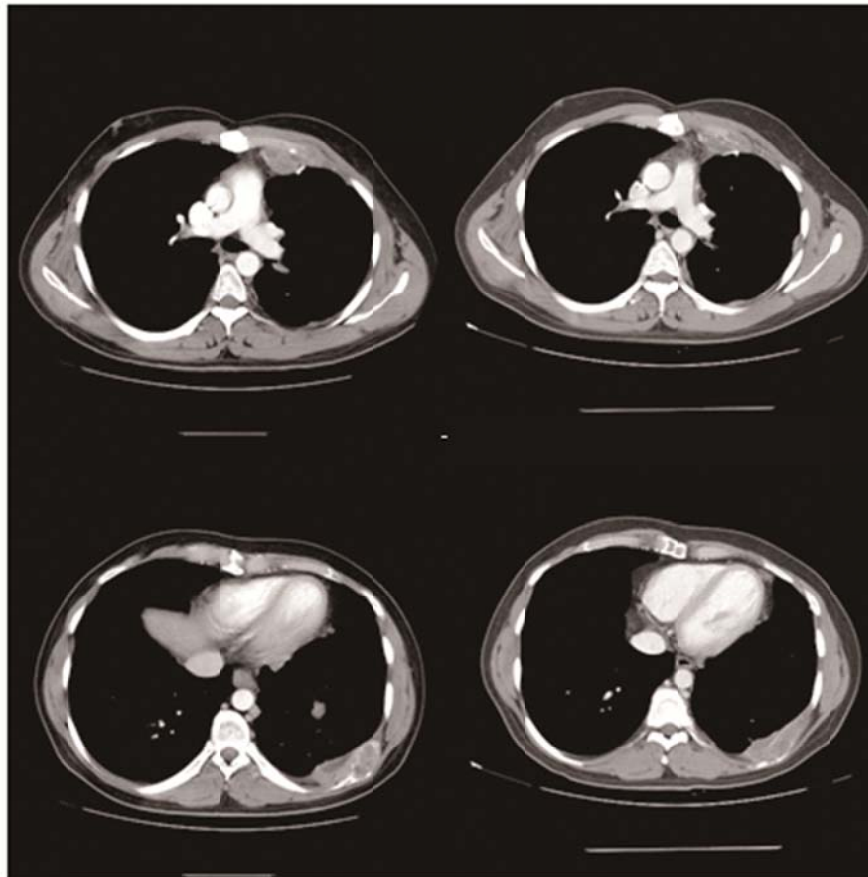


Figure 2. Computed tomography of chest demonstrating anterior mediastinal and left chest wall mass in the beginning of treatment and seven months later. Anterior mediastinal tumor measured initially (left upper frame) 6.5 by 3.5 cm, it decreased to 5.8 by 2.5 cm (right upper frame). Left chest wall mass improved from 8.2 by 3 cm (left lower frame) to 7.7 cm by 2.2 cm to (right lower frame). This improvement was associated with resolution of chest wall pain.

3 Discussion

Our report describes a case of adamantinoma of the tibia which metastasized to the mediastinum, both lungs, and to the ribs. In general, adamantinoma presents locally as an insidious onset of swelling and edema, and within a period of time it gradually enlarges in size. Sometimes pain, pathological fractures or bone deformities may be present as alert symptoms along with other symptoms ^[10].

Adamantinoma is known for its late recurrences and metastases which usually occur at the lymph nodes, lungs, skeleton, liver and brain. According to the extant literature, male gender, pain at presentation, short duration of symptoms, younger age than 20 years old, and lack of squamous differentiation of the tumor have been found to be associated with poor prognosis ^[11].

As with other locally aggressive soft tissue tumors, there is still no consensus about the safest and most effective treatment modality for adamantinoma. Especially locally aggressive and distant recurrent types need to be addressed with systemic therapy; either chemotherapy, radiotherapy or a combination of the two. Recently published case reports ^[8, 12] suggested tyrosine kinase inhibitors as an alternative therapeutic strategy to radiotherapy and chemotherapy. Molecular profiling of adamantinoma has also been suggested as a means to select an appropriate intervention ^[12]. In our case, single agent pazopanib continued to have clinical effect, perhaps because the tumor before therapy already had low vascular density (see Figure 3). Recently a phase III clinical trial (PALETTE) also showed efficacy of pazopanib treatment after progression on cytotoxic therapy in soft tissue sarcomas ^[13]. In this trial pazopanib (800 mg) compared with placebo was found to significantly increase the median progression-free survival (PFS) (20 weeks with pazopanib as compared to 7 weeks with placebo). Pazopanib was shown to be beneficial regardless of the number of prior systemic therapies, the performance status at baseline, or the type of soft tissue sarcoma.

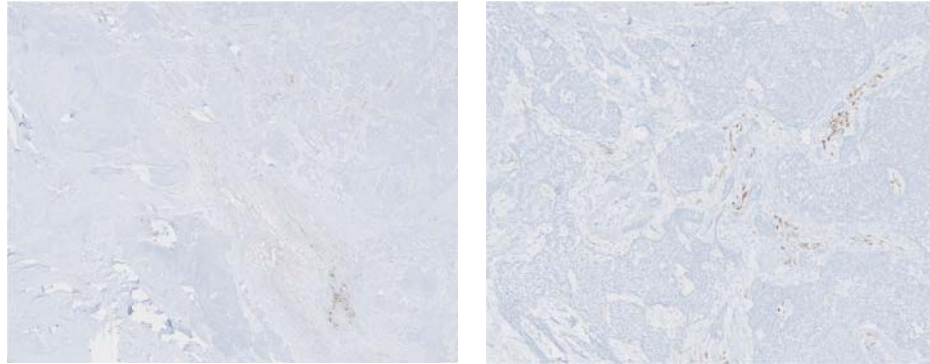


Figure 3. Left: overview of CD31 immunostained section demonstrating relative paucity of vessels. (CD31 immunostain, 19.7×magnification). Right: The vessels highlighted by CD31 are present only in the stroma surrounding tumor nests, not within tumor cell nests (CD31 immunostain, 74.7× magnification).

4 Conclusion

Our patient is a young male who had progressive, metastatic adamantinoma after first line chemotherapy (doxorubicin and cisplatin). His good response to pazopanib and alisertib in combination as a third line therapy has led us to conclude that tyrosine kinase therapy should be considered in this setting.

Acknowledgement

We thank James Zacny, PhD for editorial support.

References

- [1] Kitsoulis P, Charchanti A, Paraskevas G, et al. Adamantinoma. *Acta Orthop Belg.* 2007; 73: 425-431. PMID:17939469. Available from: <http://www.ncbi.nlm.nih.gov/pubmed/17939469>
- [2] Qureshi AA, Shott S, Mallin BA, et al. Current trends in the management of adamantinoma of long bones. An international study. *J Bone Joint Surg Am.* 2000; 82: 1122-31. PMID:10954102. <http://jbjs.org/content/82/8/1122.full.pdf+html?>
- [3] Nouri H, Jaafoura H, Bouaziz M, et al. Dedifferentiated adamantinoma associated with fibrous dysplasia. *Orthop Traumatol Surg Res.* 2011; 97: 770-5. <http://dx.doi.org/10.1016/j.otsr.2011.05.005>
- [4] Papagelopoulos PJ, Mavrogenis AF, Galanis EC, et al. Clinicopathological features, diagnosis, and treatment of adamantinoma of the long bones. *Orthopedics.* 2007; 30: 211-5. PMID:17375547.
- [5] Jain D, Jain VK, Vasishta RK, et al. Adamantinoma: a clinicopathological review and update. *Diagn Pathol.* 2008; 3: 8. <http://dx.doi.org/10.1186/1746-1596-3-8>.
- [6] Filippou DK, Papadopoulos V, Kiparidou E, et al. Adamantinoma of tibia: a case of late local recurrence along with lung metastases. *J Postgrad Med.* 2003; 49: 75-77. <http://dx.doi.org/10.4103/0022-3859.923>
- [7] Lokich J. Metastatic adamantinoma of bone to lung. A case report of the natural history and the use of chemotherapy and radiation therapy. *Am J Clin Oncol.* 1994; 17: 157-159. PMID:7511328. <http://dx.doi.org/10.1097/00000421-199404000-00013>
- [8] Dudek AZ, Murthaiah P, Franklin M, et al. Metastatic adamantinoma responds to treatment with receptor tyrosine kinase inhibitor. *Acta Oncol.* 2010; 49: 101-104. <http://dx.doi.org/10.3109/02841860902913579>.
- [9] Hanahan D, Bergers G, Bergsland E. Less is more, regularly: metronomic dosing of cytotoxic drugs can target tumor angiogenesis in mice. *J Clin Invest.* 2000 Apr; 105(8): 1045-7. PMID:10772648. <http://dx.doi.org/10.1172/JCI9872>
- [10] Cohn TB, Brahm MA, Froimson AI. Metastasis of adamantinoma sixteen years after knee disarticulation. *J Bone Joint Surg Am.* 1986; 68: 772-776. PMID:3722237.
- [11] Hogendoorn PC, Adamantinoma H. In *Pathology and genetics of tumours of soft tissue and bone*. Edited by Fletcher CD, Unni KK, Mertens F. Lyon: IARC Press; 2002. 332-4.
- [12] Cohen Y, Cohen JE, Zick A, et al. A case of metastatic adamantinoma responding to treatment with pazopanib. *Acta Oncol.* 2013; 52: 1229-1230. <http://dx.doi.org/10.3109/0284186X.2013.770921>
- [13] van der Graaf WT, Blay JY, Chawla SP, et al. EORTC Soft Tissue and Bone Sarcoma Group; PALETTE study group. Pazopanib for metastatic soft-tissue sarcoma (PALETTE): a randomised, double-blind, placebo-controlled phase 3 trial. *Lancet.* 2012; 379: 1879-1886. [http://dx.doi.org/10.1016/S0140-6736\(12\)60651-5](http://dx.doi.org/10.1016/S0140-6736(12)60651-5)