

CASE REPORT

Control of brain metastases for HER2-positive breast cancer with bevacizumab: a report of three patients

Monique Sajjad¹, Edward Pan², Susan Minton³, Roohi Ismail-Khan³

1. Department of Internal Medicine, University of South Florida, Tampa, Florida, USA. 2. Department of Neuro-Oncology, The University of Texas Southwestern Medical Center, Dallas, Texas, USA. 3. Department of Women's Oncology, Comprehensive Breast Program, H. Lee Moffitt Cancer Center and Research Institute, Tampa, Florida, USA

Correspondence: Roohi Ismail-Khan. Address: Division of Breast Oncology & Experimental Therapeutics, H. Lee Moffitt Cancer Center and Research Institute, 12902 Magnolia Drive, Tampa, FL 33612 (MCC-BR PROG), USA.

E-mail: Roohi.Ismail-Khan@moffitt.org

Received: March 7, 2013

Accepted: April 22, 2013

Online Published: June 21, 2013

DOI: 10.5430/jst.v3n4p1

URL: <http://dx.doi.org/10.5430/jst.v3n4p1>

Abstract

Introduction: Brain metastases are diagnosed in approximately 6% to 16% of all metastatic breast cancer patients. The incidence of brain metastases is much higher for patients with human epidermal growth factor receptor 2 (HER2)-positive breast cancers, in the range of 25% to 34%. More patients are presenting with uncontrolled brain metastases since trastuzumab-based therapy has improved survival in this population. However, treatment options in these patients are limited after whole brain radiation therapy (WBRT) has failed.

Case presentation: In an effort to control brain metastases, three patients who had progression of HER2-positive breast cancer after WBRT received the angiogenesis-inhibiting drug bevacizumab, a humanized monoclonal antibody against the vascular endothelial growth factor (VEGF) ligand. The patients showed clinical improvement and regression of tumor growth. After initial diagnosis of brain metastases, patient 1 survived 14 months, patient 2 survived 32 months, and patient 3 survived 45 months. Bevacizumab controlled brain metastases for 6, 13, and 19 months, respectively, after progression on WBRT.

Conclusion: This subset of patients with brain metastases and HER2/neu-positive breast cancer clearly responded to an anti-VEGF regimen, suggesting the need for a prospective clinical trial of bevacizumab with lapatinib or other HER2-targeted therapy in this patient group.

Key words

HER2-positive breast cancer, CNS metastasis, Brain metastasis, Lapatinib, Bevacizumab

1 Introduction

Breast cancer is the most common solid tumor malignancy in women, with the second highest mortality rate. Infiltrating ductal carcinoma is the most common type of breast cancer, accounting for 70-80% of cases, of which approximately 30% are HER2 positive^[1]. The oncogene HER2 is a member of the epidermal growth factor receptor family and is responsible for epithelial cell growth, proliferation, and angiogenesis^[2]. HER2 over-expression is useful for determining candidates for targeted therapy^[3]. Tumors that express HER2 have been found to respond better to anthracycline-based

chemotherapy^[4,5]. Trastuzumab (Herceptin®) is a monoclonal antibody that inhibits the HER2/neu receptor. Since the advent of HER2/neu receptor inhibitors like trastuzumab, patients with HER2-positive breast cancer are doing as well as their counterparts with HER2-negative disease^[6].

In addition to the high incidence and mortality rate associated with breast cancer, it is also the second most common cause of brain metastases, with melanoma having the highest propensity for spread. Brain metastases are diagnosed in approximately 6% to 16% of all metastatic breast cancer patients and in 25% to 34% of patients with HER2-positive breast cancer^[7]. With the significant improvements and control of systemic disease from HER2/neu receptor-based therapy, patients are surviving longer but increasingly presenting with uncontrolled brain metastasis. Options are very limited in patients who have central nervous system (CNS) involvement. Whole brain radiation therapy (WBRT), the current standard of care, has only been found to prolong life expectancy by 4-6 months compared with 1-2 months for brain metastases treated with steroids alone^[8]. Surgery minimally improves mortality and is typically only performed in patients with less than 3 CNS lesions. Systemic chemotherapy is ineffective because of failure to cross the blood brain barrier^[9,10]. Intrathecal chemotherapy, although useful in hematologic malignancies, has not been shown to increase overall survival in solid tumors^[11]. Evidence has shown that the monoclonal antibody trastuzumab is also unable to enter the cerebrospinal fluid^[9,10]. Another HER2-targeting tyrosine kinase inhibitor, lapatinib, has shown some evidence of superiority with regard to progression of brain metastases when used with adjuvant in a phase II trial^[12]. This study, however, was closed early due to excessive toxicity and lack of efficacy in the lapatinib plus topotecan arm^[12].

In this report, we present a series of patients who had progression of HER2-positive breast cancer after WBRT. Since these patients had well-controlled systemic disease, the prognosis was driven by the lack of control of their CNS metastases. We made the clinical decision to treat with bevacizumab after standard of care had failed in these patients. Bevacizumab is a humanized monoclonal antibody against the vascular endothelial growth factor (VEGF) ligand, which acts to inhibit angiogenesis. Bevacizumab was approved for treatment of metastatic breast cancer at the time of our study; however, in 2011, it lost FDA approval after failing to show survival benefit and causing significant adverse events of hemorrhage and hypertension. It is currently approved for metastatic colon or renal cell cancers, locally advanced, recurrent, and metastatic non-small cell lung cancer, and recurrent glioblastomas^[13]. In the three cases described here, bevacizumab resulted in improved quality of life, tumor regression, and increased overall survival in patients with brain metastases from HER2/neu-positive breast cancer.

2 Case presentation

2.1 Case 1

Patient 1 (Figure 1) was diagnosed with metastatic hepatic lesions in November 2009 at age 36. A breast biopsy at that time was consistent with a poorly differentiated 2.5 cm infiltrating ductal carcinoma. Immunohistochemistry showed estrogen receptor (ER)/progesterone receptor (PR) negativity and 3+ HER2/neu positivity. Fluorescence in situ hybridization (FISH) was positive for HER2/neu amplification at a ratio of 6.73. Liver biopsy confirmed metastatic disease from a breast primary. She was started on paclitaxel, carboplatin, and trastuzumab, which were discontinued after one cycle secondary to hospitalization for bacteremia. Treatment was then switched to nabpaclitaxel with trastuzumab for a total of five doses. After completion, imaging showed a complete response of her systemic disease. She was maintained on trastuzumab. In September 2010, she developed headaches and ataxia; magnetic resonance imaging (MRI) of the brain in October 2010 showed metastases that were too numerous to count (Figure 1). At this time, she received WBRT. In November 2010, lapatinib 1250 mg daily was added to trastuzumab 6 mg/kg every 3 weeks. A repeated brain imaging in February 2011 showed a decrease in the size of the metastases, but another MRI in April 2011 showed increases in the size and number of lesions (not shown), and the patient underwent WBRT a second time. However, MRI in June 2011 (Figure 1) did not show radiographic response of the metastatic lesions. She was started on bevacizumab 15 mg/kg every 3 weeks in May 2011.

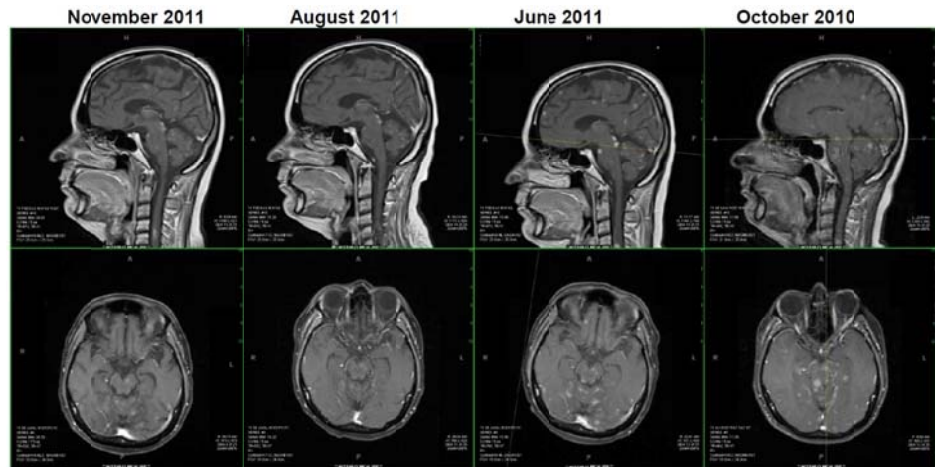

Figure 1. Patient 1: started bevacizumab May 2011

Repeat imaging in August 2011 (Figure 1) showed significant improvement in her CNS disease, as well as symptomatic relief of her neurologic symptoms. Her quality of life improved significantly. The patient was again scheduled for an MRI in November 2011 (Figure 1), which revealed slightly larger lesions and no evidence of new metastases. She was continued on bevacizumab since she was still asymptomatic at that time. However, her condition worsened, and she expired in December 2011 after a 25-month overall survival from diagnosis of breast cancer. She survived 14 months with brain metastases, and CNS disease was controlled on bevacizumab for 6 months.

2.2 Case 2

Patient 2 (Figure 2) was diagnosed with a T3N0M0 infiltrating moderately differentiated ductal carcinoma in April 2003 at 55 years of age. Immunohistochemistry showed 3+ estrogen receptor (ER) positivity, 1+ progesterone receptor (PR) positivity, and 3+ HER2/neu positivity. FISH was positive for HER2/neu amplification at a ratio of 10.8. She underwent lumpectomy followed by treatment with adjuvant radiation and chemotherapy with adriamycin and cytoxan for four cycles and was placed on tamoxifen for 2 years followed by anastrozole for 3 years. She did well until May 2008 when she began experiencing lumbar spine and hip pain. She was found to have extensive lytic bone lesions involving the entire spine, multiple ribs, and bilateral pelvis. Biopsy of a pelvic lesion proved to be ER/PR-negative, HER2/neu-positive metastatic breast carcinoma. She was started on systemic therapy with paclitaxel, carboplatin, and trastuzumab. After 5 cycles, restaging scans showed significant improvement in systemic disease. She continued on trastuzumab 6 mg/kg every 3 weeks, and lapatinib 1250 mg daily was added.

The patient began having headaches in August 2009, and MRI of the brain showed multiple enhancing lesions consistent with metastatic disease. She underwent WBRT and initially had good response with decreased size and number of lesions, as shown by an MRI in December 2009 (not shown). MRI remained stable until June 2010 when the lesions showed progression. She underwent stereotactic radiosurgery to those lesions that were felt to be causing the most symptoms. However, in February 2011 (Figure 2), MRI of the brain again showed increased tumor size with surrounding edema. The patient was started on bevacizumab 15 mg/kg every 3 weeks. Repeat imaging in April 2011 showed a decrease in the size of brain metastases and no new lesions (Figure 2). Imaging in July 2011 showed decreased prominence of the infratentorial lesions and no new lesions (not shown). In January 2012, her MRI showed increased size of lesions but no new lesions (not shown). However, she began to develop short-term memory loss in February 2012 and MRI at that time showed further increase in size of the metastases (Figure 2). Bevacizumab therapy was discontinued in March 2012 given the evidence of disease progression. She expired in April 2012 after a 108-month overall survival from diagnosis of breast cancer. She survived 32 months with brain metastases, which were controlled on bevacizumab for 13 months.

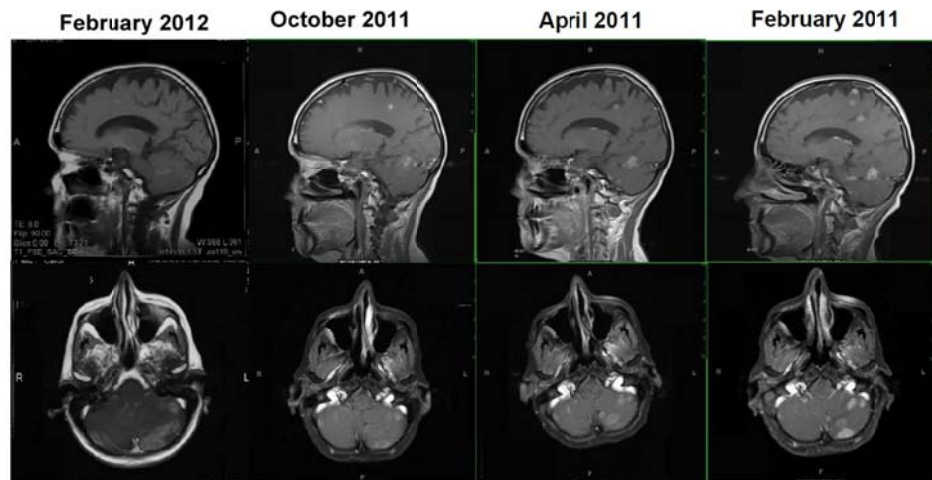


Figure 2. Patient 2: started bevacizumab February 2011

2.3 Case 3

Patient 3 (Figure 3) was diagnosed with a 1.1-cm infiltrating ductal carcinoma with metastasis to 1 of 6 lymph nodes in April 2001 at 36 years of age. Immunohistochemistry showed 2+ ER positivity, 1+ PR positivity, and 3+ HER2/neu positivity. FISH was positive for HER2/neu amplification at a ratio of 6.73. She underwent mastectomy and received adjuvant cyclophosphamide, doxorubicin, and 5-fluorouracil until November 2001. She was briefly on tamoxifen and then leuprolide, which had to be stopped secondary to menopausal symptoms. She began to have gait disturbance and headaches in August 2007 and was found to have a biopsy-proven metastatic brainstem lesion that was not amenable to surgery. She underwent fractionated stereotactic radiation but developed recurrent disease to the same area in June 2008. This recurrence was treated with repeat fractionated stereotactic radiation. Imaging at that time showed no other metastatic disease. After completion of radiation, she was started on lapatinib 1250 mg daily. CT imaging remained stable until November 2008 when the pontine lesion grew and two new lesions were found. She underwent stereotactic radiosurgery to the larger lesion and was asymptomatic on steroids. In early 2009, capecitabine 1000 mg twice daily for 2 weeks on and 1 week off was added to lapatinib 1250 mg daily.

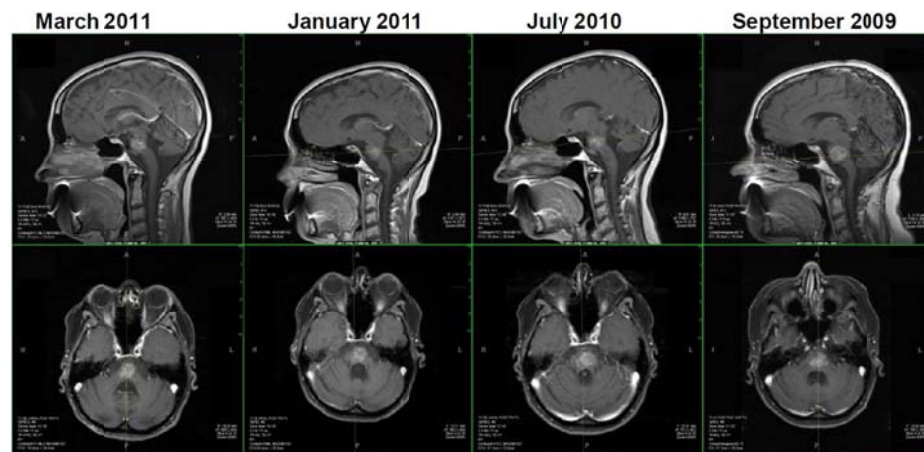


Figure 3. Patient 3: started bevacizumab August 2009

In July 2009, she began having vision changes and extreme fatigue and myopathy felt to be steroid induced. Imaging showed a slight increase in the size of the pontine metastasis. In August 2009, the patient was started on bevacizumab 10 mg/kg every 3 weeks in addition to lapatinib. Capecitabine was stopped. By September 2009, the patient had significant improvement in her neurologic symptoms, and her MRI showed no progression (Figure 3). Her CNS disease remained stable until March 2010. In July 2010 (Figure 3), while on bevacizumab and lapatinib, there was slight improvement in metastatic lesions by MRI. The lesions remained stable until March 2011 (Figure 3).

In May 2011, the patient began to have diplopia and dysphagia and was found to have leptomeningeal disease, which was treated with intrathecal liposomal cytarabine (DepoCyt[®]). Her condition worsened and she expired in May 2011 after a 121-month overall survival from diagnosis of breast cancer. She survived 45 months with brain metastases, and her CNS disease was controlled on bevacizumab for 19 months.

3 Discussion

The need for investigational agents with CNS bioavailability is clear. The risk for brain metastases is becoming an increasing problem with improved survival and systemic disease control through the use of targeted agents. Brain metastasis from HER2-positive breast carcinoma represents a subset of patients who will have a better response to an anti-VEGF regimen, as seen in the above cases. Bevacizumab received accelerated approval for treatment of metastatic breast cancer in February 2008^[13]. It lost this indication on November 18, 2011, when additional trials failed to show improved survival benefit^[14-16]. This therapy could, however, have potential to slow down tumor growth and proliferation, which was seen in our three patients. Other studies have similarly shown that bevacizumab can be used safely in specific patient populations^[17, 18].

The three patients discussed in this report (Figure 4) showed clinical improvement and documented radiological regression of tumor growth after WBRT on bevacizumab for 6, 13, and 19 months, respectively, which is essentially unheard of in this population. After diagnoses of brain metastases, patient 1 survived for 14 months, patient 2 survived for 32 months, and patient 3 survived for 45 months. The overall survival from initial diagnosis of breast cancer for these patients was 25, 108, and 121 months, respectively.

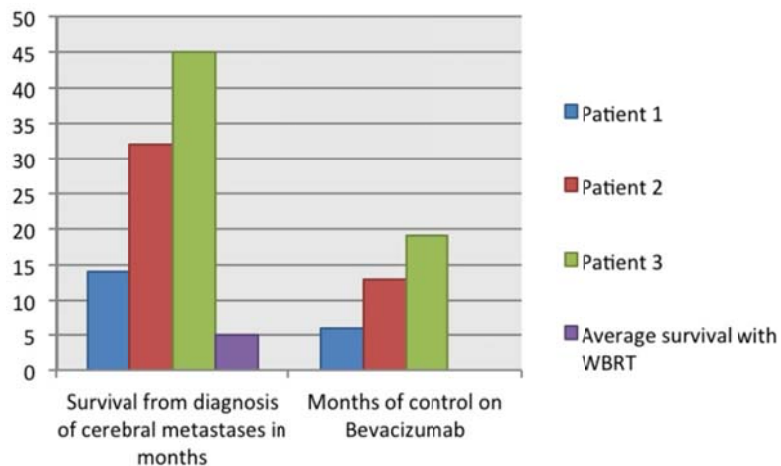


Figure 4. Summary of patient survival

4 Summary

The above cases demonstrate improved overall survival and morbidity benefits with the use of bevacizumab in conjunction with HER2-targeted therapy. Since the advent of more recent HER2-targeted treatments, patients like those illustrated in our study have shown improved control of systemic disease, with their prognosis being limited only by the presence of CNS metastases. Given the limited options for control of CNS disease, VEGF inhibitor therapy should be considered after other options have failed. The benefits of bevacizumab outweigh the risks in these individuals who have such poor prognosis. The above cases suggest the need for a prospective clinical trial of bevacizumab with HER2-targeted therapy in this subset of patients with controlled systemic disease, uncontrolled brain metastases, and HER2/neu-positive breast cancer.

Acknowledgements

We thank Rasa Hamilton (Moffitt Cancer Center) for editorial assistance.

References

- [1] Jemal A, Siegel R, Xu J, Ward E. Cancer statistics, 2010. *CA Cancer J Clin.* 2010; 60: 277-300. <http://dx.doi.org/10.3322/caac.20073>
- [2] Klapper LN, Glathe S, Vaisman N, Hynes NE, Andrews GC, Sela M, et al. The ErbB-2/HER2 oncoprotein of human carcinomas may function solely as a shared coreceptor for multiple stroma-derived growth factors. *Proc Natl Acad Sci USA.* 1999; 96: 4995-5000. PMID:10220407 <http://dx.doi.org/10.1073/pnas.96.9.4995>
- [3] Slamon DJ, Godolphin W, Jones LA, Holt JA, Wong SG, Keith DE, et al. Studies of the HER-2/neu proto-oncogene in human breast and ovarian cancer. *Science.* 1989; 244: 707-712. PMID:2470152 <http://dx.doi.org/10.1126/science.2470152>
- [4] Guarneri V, Giovannelli S, Ficarra G, Bettelli S, Maiorana A, Piacentini F, et al. Comparison of HER-2 and hormone receptor expression in primary breast cancers and asynchronous paired metastases: impact on patient management. *Oncologist.* 2008; 13: 838-844. PMID:18650259 <http://dx.doi.org/10.1634/theoncologist.2008-0048>
- [5] Muss HB, Thor AD, Berry DA, Kute T, Liu ET, Koerner F, et al. c-erbB-2 expression and response to adjuvant therapy in women with node-positive early breast cancer. *N Engl J Med.* 1994; 330: 1260-1266. PMID:7908410 <http://dx.doi.org/10.1056/NEJM199405053301802>
- [6] Taylor C, Hershman D, Shah N, Suci-Foca N, Petrylak DP, Taub R, et al. Augmented HER-2 specific immunity during treatment with trastuzumab and chemotherapy. *Clin Cancer Res.* 2007; 13: 5133-5143. PMID:17785568 <http://dx.doi.org/10.1158/1078-0432.CCR-07-0507>
- [7] Bendell JC, Domchek SM, Burstein HJ, Harris L, Younger J, Kuter I, et al. Central nervous system metastases in women who receive trastuzumab-based therapy for metastatic breast carcinoma. *Cancer.* 2003; 97: 2972-2977. PMID:12784331 <http://dx.doi.org/10.1002/cncr.11436>
- [8] Suh JH: Stereotactic radiosurgery for the management of brain metastases. *N Engl J Med.* 2010; 362: 1119-1127. PMID:20335588 <http://dx.doi.org/10.1056/NEJMct0806951>
- [9] Lai R, Dang CT, Malkin MG, Abrey LE. The risk of central nervous system metastases after trastuzumab therapy in patients with breast carcinoma. *Cancer.* 2004; 101: 810-816. PMID:15305414 <http://dx.doi.org/10.1002/cncr.20418>
- [10] Stemmler HJ, Schmitt M, Willems A, Bernhard H, Harbeck N, Heinemann V. Ratio of trastuzumab levels in serum and cerebrospinal fluid is altered in HER2-positive breast cancer patients with brain metastases and impairment of blood-brain barrier. *Anticancer Drugs.* 2007; 18: 23-28. PMID:17159499 <http://dx.doi.org/10.1097/01.cad.0000236313.50833.ee>
- [11] DeAngelis LM. Current diagnosis and treatment of leptomeningeal metastasis. *J Neurooncol.* 1998; 38: 245-252. PMID:9696379 <http://dx.doi.org/10.1023/A:1005956925637>
- [12] Bachelot T, Romieu G, Campone M, Diéras V, Cropet C, Dalenc F, et al. Lapatinib plus capecitabine in patients with previously untreated brain metastases from HER2-positive metastatic breast cancer (LANDSCAPE): a single-group phase 2 study. *Lancet Oncol.* 2013; 4: 64-71.
- [13] Genentech: Bevacizumab package insert. San Francisco, Genentech, Inc, 2011.
- [14] Miles DW, Chan A, Dirix LY, Cortes J, Pivot X, Tomczak P, et al. Phase III study of bevacizumab plus docetaxel compared with placebo plus docetaxel for the first-line treatment of human epidermal growth factor receptor 2-negative metastatic breast cancer. *J Clin Oncol.* 2010; 28: 3239-3247. PMID:20498403 <http://dx.doi.org/10.1200/JCO.2008.21.6457>
- [15] Miller KD, Chap LI, Holmes FA, Cobleigh MA, Marcom PK, Fehrenbacher L, et al. Randomized phase III trial of capecitabine compared with bevacizumab plus capecitabine in patients with previously treated metastatic breast cancer. *J Clin Oncol.* 2005; 23: 792-799. PMID:15681523 <http://dx.doi.org/10.1200/JCO.2005.05.098>
- [16] Miller K, Wang M, Gralow J, Dickler M, Cobleigh M, Perez EA, et al. Paclitaxel plus bevacizumab versus paclitaxel alone for metastatic breast cancer. *N Engl J Med.* 2007; 357: 2666-2676. PMID:18160686 <http://dx.doi.org/10.1056/NEJMoa072113>
- [17] Smith IE, Pierga JY, Biganzoli L, Cortes-Funes H, Thomssen C, Pivot X, et al. First-line bevacizumab plus taxane-based chemotherapy for locally recurrent or metastatic breast cancer: safety and efficacy in an open-label study in 2,251 patients. *Ann Oncol.* 2011; 22: 595-602. PMID:20819780 <http://dx.doi.org/10.1093/annonc/mdq430>
- [18] Biganzoli L, Di Vincenzo E, Jiang Z, Lichinitser M, Shen Z, Delva R, et al. First-line bevacizumab-containing therapy for breast cancer: results in patients aged ≥ 70 years treated in the ATHENA study. *Ann Oncol.* 2012; 23: 111-118. PMID:21444356 <http://dx.doi.org/10.1093/annonc/mdr043>