

## CASE REPORT

# Oesophageal pain: A tough nut to crack the role of high resolution manometry guided segmental oesophageal myotomy

Santosh Balakrishnan, Robert C Mason

Department of General Surgery, St Thomas' hospital, London, UK.

**Correspondence:** Santosh Balakrishnan. Address: Department of General Surgery, St Thomas' hospital, Guy's and St Thomas' NHS foundation trust, Lambeth Palace Road, London, SE1 7EH, UK. Email: santosurg@yahoo.com.

**Received:** May 24, 2012

**Accepted:** July 23, 2012

**Published:** December 1, 2012

**DOI:** 10.5430/jbgc.v2n2p104

**URL:** <http://dx.doi.org/10.5430/jbgc.v2n2p104>

## Abstract

**Introduction:** Oesophageal motility disorders (OMDs) are a recognized cause of pain in 25-33% of patients with non-cardiac chest pain. The understanding of these disorders based on standard multichannel oesophageal manometry has improved with high resolution oesophageal manometry (HROM). This could facilitate selection of treatment modality including identifying those suitable for surgical myotomy while preserving oesophageal function.

**Material and methods:** This discussion is based on a 65 year old lady with a 17 year history of oesophageal pain due to Nutcracker oesophagus. Persistence of symptoms despite medical management using proton pump inhibitors, calcium channel blockers, nitrates, endoscopic pneumatic dilatation & Botulinum toxin injection prompted re-referral to our specialist unit and analysis of residual oesophageal function using HROM. This revealed a segment of nutcracker oesophagus in the mid oesophagus with significant supine reflux.

**Result:** Surgical treatment with trans-hiatal open focused oesophageal myotomy with preservation of lower oesophageal sphincter and floppy Nissen fundoplication led to satisfactory and complete resolution of symptoms.

**Discussion:** HROM provides a clearer classification of the functional abnormalities and their co-relation to symptoms. This allows application of the best available treatment modality including surgery to achieve symptomatic relief with preservation of residual oesophageal function.

**Conclusion:** Limited evidence is currently available on the comparative benefits of available treatment modalities for OMDs. HROM provides greater insight into OMDs and the benefits of available treatment modalities allowing selection of optimal treatment modality and preserving oesophageal function while achieving relief of the patients distressing symptoms.

## 1 Introduction

Oesophageal dysmotility and related conditions are a recognised cause of chest pain of non-cardiac origin. Katz et al found oesophageal manometric abnormalities in 33% of adults and Glassman et al found oesophageal dysmotility in 21 out of 83 (25.3%) of children under investigations for non-cardiac chest pain<sup>[1, 2]</sup>. Conventional classification and treatment based on standard manometry improved the understanding and guided selection of treatments<sup>[3]</sup>. The evolution

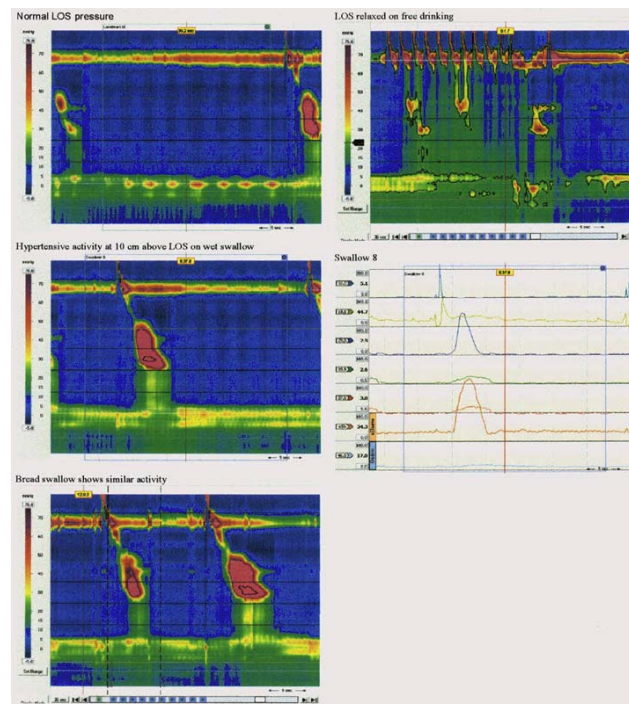
of high resolution oesophageal manometry (HROM) has facilitated real time analysis with visual representation of oesophageal function [4]. This additional data has allowed detailed classification of the spectrum of disorders and has potential to guide selection of available treatment modalities especially surgical treatment. This could improve treatment outcomes and importantly prevent functional and symptomatic deterioration from the interventions.

## 2 Case presentation

This discussion is based on the case of a 65 year old lady with intractable central chest pains of over 17 years. Initial investigations by her family practitioners and physicians for cardiac, respiratory and musculoskeletal causes were inconclusive. An evaluation by medical gastroenterology raised suspicion of oesophageal origin of the symptoms. Following an Upper GI endoscopy which revealed a small hiatus hernia she was treated with proton pump inhibitors. She was diagnosed with oesophageal hypersensitivity at her local hospital where she underwent endoscopic oesophageal balloon dilatation on three occasions with little relief. She was referred to our tertiary referral Oesophago-gastric unit seven years ago where a diagnosis of Nutcracker oesophagus was made based on clinical symptoms and standard 24 hour oesophageal pH & manometry study.

The medical gastroenterologists at her local hospital treated this condition escalating from proton pump inhibitors to calcium channel blockers, amitriptyline and endoscopic Botox injections. Persistent symptoms and distress despite treatment as described prompted a second referral to the Medical Gastroenterology team at our institute. Treatment was commenced with Glyceryl trinitrate spray and an Oesophago-gastric surgical opinion was requested for intractable and debilitating symptoms of pain and dysphagia.

She underwent an oesophageal ph and manometry study using a high resolution oesophageal manometry (HROM) probe (Sierra Scientific Instruments, Los Angeles, California; USA) for analysis of oesophageal function and relations of symptoms to gastro-oesophageal reflux and oesophageal dysmotility.



**Figure 1.** Pre-operative HROM study trace

Computer aided graphic analysis of the manometry revealed a clearly defined area of abnormally high luminal pressure exceeding 180mm Hg in the mid segment of the oesophagus 10cm above the lower oesophageal sphincter (see Figure 1), with simultaneous spastic contraction in the area in 40% of swallows and failed progression in 60% across an atonic lower oesophagus with distal contractile integrals of 1823.0 mm Hg-cm-s. The study showed a normal lower oesophageal sphincter (LOS) tone with minimal upright reflux and significant supine reflux with a DeMeester score of 85.3 (Normal < 14.72) There was positive co-relation of pain to episodes of mid oesophageal hypertension.

She was offered two avenues of management which were to continue with medical management as was being provided with additional support from a nutritionist or proceed to surgical myotomy. The patient chose to prefer the surgical option owing to the poor quality of life despite best medical care. She was therefore offered a manometry guided segmental mid oesophageal myotomy with preservation of the LOS and a floppy Nissen fundoplication. She was made aware of the unpredictability of results in the treatment of motility disorders of the oesophagus and the need to consider oesophagectomy and replacement with a conduit in the event of a failure.

The patient underwent an uneventful Manometry guided focused mid-oesophageal segmental myotomy through an open trans-hiatal approach with preservation of LOS and a floppy Nissen fundoplication.

At outpatient review six weeks post-operatively the patient was happy to confirm relief from pain and almost normal swallowing. The patient reported a significant improvement in her quality of life without the need for any medications.

### 3 Discussion

William Osler<sup>[5]</sup> in 1892 proposed oesophageal spasms a possible cause of non-cardiac chest pain in patients who were till then largely labeled as hypochondriac. However knowledge about its actual nature or etiology remained obscure till 1934 when Moersh and Camp<sup>[6]</sup> described radiological findings in this group of patients revealing deranged peristaltic activity. Various imaginative terms such as Nutcracker, corkscrew or rosary-bead oesophagus have since been used to describe these entities. They were employed more to reflect the symptoms experienced by the patients and radiologic appearances than the actual functional status of the oesophagus.

Multi-channel Oesophageal manometry and 24 hour pH studies brought about a greater understanding of the spectrum of motility related disorders ranging from those of relative adynamism, those caused by vigorous or ineffective peristaltic activity and those of lack of co-ordinated sphincter activity. A classification evolved which provided greater insight into guiding management of these patients<sup>[3]</sup>.

The recognition that a variety of spastic oesophageal motility disorders were a result of reflux related acid exposure led to the concept of oesophageal hypersensitivity<sup>[7, 8]</sup>. Symptomatic improvement of oesophageal pain has been seen with the use of Proton pump inhibitors and they have been recommended as a safe first line management option<sup>[8, 9]</sup>.

Recognition of the role of derangements of Nitric Oxide (NO) production and degradation in patients with Achalasia and the reproduction of manometric findings in animal models & symptoms in human studies prompted the use of NO donors with variable success<sup>[10-12]</sup>.

Medical treatment was based on the use of Nitrates and NO breakdown inhibitors such as phosphodiesterase inhibitors such as theophylline and more recently selective phosphodiesterase inhibitors such as sildenafil. Symptomatic benefit was also seen with the use of calcium channel blockers such as nifedipine especially in improving dysphagia in patients with Achalasia<sup>[9, 13]</sup>. The efficacy of medical treatment has been reported in a number of comparative studies and case series. There is however a lack of well-structured trials or evidence to support one modality over others. This is in all possibility a reflection of the heterogeneity of presentation of these disorders making comparative trials challenging.

Balloon dilatation using a radiologically placed rigidflex balloon has been effective for the management of Achalasia since 1962 but up to 50% patients need repetition with an inherent perforation rate of around 10<sup>[14]</sup>. A study from Guys Hospital<sup>[15]</sup> in 1992 described the results of treatment of diffuse oesophageal spasm with balloon pneumatic dilatation in 20 patients with initial success in only 6 patients with three of them eventually needing surgical myotomy. One patient developed a perforation.

The simplicity and effectiveness of endoscopic Botulinum toxin (Botox) injection<sup>[16, 17]</sup> has spawned many enthusiasts. The period of remission however is variable and re-injections are needed. The repeated use of Botox however does run the risk of replacing a painful oesophagus with an aperistaltic one with dysphagic symptoms. Further, repeated sub-mucosal injections make future surgical myotomy challenging due to scarring in the sub-mucosal plane.

Surgical myotomy whether conventional open, trans-hiatal or laparoscopic has become the standard for treatment of achalasia with demonstrable and sustainable results. While significant success has been achieved with surgical long oesophageal myotomy for other spastic oesophageal disorders such as nutcracker oesophagus or diffuse oesophageal spasm, certain unpredictability of the extent of symptomatic benefit obtained and its duration continues to persist. Hence it is not yet considered a method suitable for first line management<sup>[9, 18-20]</sup>.

The availability of high resolution oesophageal manometry (HROM) (Sierra scientific instruments) provided new insights into the co-ordinated function of the oesophagus. High resolution oesophageal manometry provides a real time picture of the simultaneous activity of different zones of the oesophagus plotted against time using a colour coded graphical analysis which reflects the pressure changes and progress of the peristaltic wave and the response of the lower oesophageal sphincter. HROM can provide reliable information in all cases where standard manometric study of oesophageal function is indicated and is emerging as the gold standard for oesophageal function assessment. Its widespread use may be limited currently by the cost and the expertise required in assessing the information obtained in the context of the clinical picture. However it would be the investigation of choice in patients where there is ambiguity of diagnosis based on lack of correlation between symptoms, contrast studies and standard manometry. So also it provides a more reliable picture of residual oesophageal function in patients, who like the case in study, have had multiple modalities of treatment.

A new classification has been proposed by Kahrilas, Ghosh and Pandolfino<sup>[4]</sup> based on the HROM findings in various functional oesophageal disorders. The HROM findings applied in the context of this classification allows objective differentiation between the spectrums of known oesophageal motility disorders. Based on these parameters it is also possible to describe the functional status of the oesophagus after previous attempts at treatment with Botox, dilatations or surgery.

The patient under discussion had been diagnosed with a spastic oesophageal condition 17 years ago with pain as her main symptom with minimal intermittent dysphagia. This condition was treated as hypersensitive oesophagus secondary to reflux with proton pump inhibitors (PPI) with little benefit. She also underwent three courses of lower oesophageal dilatation with similar functional results. A revised diagnosis of nutcracker oesophagus following conventional manometric study prompted medical treatment with calcium channel blockers, Amitriptyline, PPIs and later with endoscopic Botox injections into the lower oesophagus just proximal to the lower oesophageal sphincter.

Her symptom of pain continued despite these treatments, significantly affecting her quality of life. She was referred to the Oesophago-gastric surgical team for opinion regarding surgery. She underwent a HROM study revealing the findings discussed earlier.

The finding of a spastic area of high pressure (>180mm Hg) in the untreated area of the mid oesophagus with a relatively normal functioning distal oesophageal sphincter made it possible to offer the patient a HROM guided trans-hiatal focal oesophageal myotomy with sparing of the OGJ to prevent worsening of the observed gastro oesophageal reflux. Since it is

likely that the Nutcracker oesophagus was a result of progressive oesophageal hypersensitivity due to long standing acid reflux, it was decided to combine the segmental myotomy with a floppy Nissen fundoplication.

The satisfactory result of the treatment undertaken can only be explained by the greater understanding of the functional status of the multiply treated oesophagus afforded by the interpretation of the HROM studies. This experience with the application of the newer classification of oesophageal motility disorders based on HROM functional analysis opens the avenue to tailor the use of available treatment modalities to suite the functional abnormalities noted thus delivering maximum benefit whilst preserving existing oesophageal function.

The long term result in this patient will be followed up with great interest and of course, historic surgical optimism.

## 4 Conclusion

The treatment of functional oesophageal motility disorders continues to remain challenging with limited comparative evidence to support the use of various available modalities which have shown benefit.

The improved understanding of oesophageal function from the technological advancement afforded by high resolution oesophageal manometric studies and the application of the modern classification of Oesophageal motility disorders could guide the application of the appropriate treatment modality tailored to individual patients. This may also enable salvage of existing oesophageal function to deliver optimal functional results with relief of symptoms and improvement of quality of life.

## Acknowledgement

Ms Carvelle Miller-Rowe: Surgical Secretary: Assisted with administrative work to procure necessary records. Dr A. Angjiansah: Director: Oesophageal Lab. Provided report of HR oesophageal manometry study.

## References

- [1] Katz PO, Dalton CB, Richter JE, et al. Esophageal testing of patients with noncardiac chest pain or dysphagia. Results of three-years experience with 1161 patients. *Ann Intern Med.* 1987; 106: 593-597.
- [2] Glassman MS, Medow MS, Berezin S, et al. Spectrum of esophageal disorders in children with chest pain. *Dig Dis Sci.* 1992; 37: 663-666. PMID:1563306 <http://dx.doi.org/10.1007/BF01296420>
- [3] S J Spechler, D O Castell; Classification of oesophageal motility abnormalities; *Gut.* 2001; 49: 145-151. PMID:11413123 <http://dx.doi.org/10.1136/gut.49.1.145>
- [4] Peter J. Kahrilas, Sudip K. Ghosh and John E. Pandolfino. Esophageal Motility Disorders in Terms of Pressure Topography: The Chicago Classification *J Clin Gastroenterol.* 2008; 42(5): 627-635.
- [5] Osler W. Oesophagismus. In: Osler W, ed. *Principles and Practice of Medicine.* New York, NY, USA: D Appleton and Co. 1892; 340.
- [6] Moersch HJ, Camp JD. Diffuse spasm of the lower part of the esophagus. *Ann Otol Rhinol Laryngo.* 1934; 43: 1165-71.
- [7] Chua YC, Aziz Q. Perception of gastro-oesophageal reflux. *Best Pract Res Clin Gastroenterol.* 2010; 24(6): 883-91. <http://dx.doi.org/10.1016/j.bpg.2010.10.003>
- [8] Lottrup C, Olesen SS, Drewes AM. The pain system in oesophageal disorders: mechanisms, clinical characteristics, and treatment; *Gastroenterol Res Pract.* 2011; 2011: 910420. Epub 2011 Aug 2.
- [9] R. Tutuian, D. O. Castell; Review article: oesophageal spasm – diagnosis and management, *Aliment Pharmacol Ther.* 2006; 23: 1393-1402. PMID:16669954 <http://dx.doi.org/10.1111/j.1365-2036.2006.02917.x>
- [10] Joseph A. Murray, Amber Ledlow, Janice Launsbach, Donna Evans, Michelle Loveday, Jeffrey L. Conklin. The effects of recombinant human hemoglobin on esophageal motor function in humans; *Gastroenterology.* 1995; 109(4): 1241-1248. PMID:7557091

- [11] David P. Hirsch, Richard H. Holloway, Guido N.J. Tytgat, Guy E.E. Boeckstaens; Involvement of nitric oxide in human transient lower esophageal sphincter relaxations and esophageal primary peristalsis. *Gastroenterology*. 1998; 115(6): 1374-1380. PMID:9834264
- [12] Jeffrey L. Conklin. Nitric oxide: A mediator of esophageal motor function; *Journal of Laboratory and Clinical Medicine*. 1998; 131(1): 10-20. [http://dx.doi.org/10.1016/S0022-2143\(98\)90072-5](http://dx.doi.org/10.1016/S0022-2143(98)90072-5)
- [13] Claudia Grubel, Jan Borovicka, Werner Schwizer, M., Mark Fox, Geoff Hebbard. Diffuse Esophageal Spasm; *Am J Gastroenterol*. 2008; 103: 450-457. PMID:18005367
- [14] Lacy B.E, Weiser K. Esophageal Motility Disorders. *Medical Therapy. J Clin Gastroenterol*. 2008; 42: 652-658. PMID:18364589 <http://dx.doi.org/10.1097/MCG.0b013e31815bd223>
- [15] Irving JD, Owen WJ, Linsell J, McCullagh M, Keightley A, Anggiansah A. Management of diffuse esophageal spasm with balloon dilatation. *Gastrointest Radiol*. 1992; 17(3): 189-92. PMID:1612298 <http://dx.doi.org/10.1007/BF01888544>
- [16] Eduardo B. V. da Silveira, Arvey I. Rogers; Treatment of Achalasia with Botulinum A Toxin; *American Journal of Therapeutics*. 2002; 9: 157-161. PMID:11897930 <http://dx.doi.org/10.1097/00045391-200203000-00010>
- [17] Brisinda G, Bentivoglio AR, Maria G, Albanese A. Treatment with botulinum neurotoxin of gastrointestinal smooth muscles and sphincters spasms; *Mov Disord*. 2004; 19 Suppl 8: S146-56. PMID:15027068 <http://dx.doi.org/10.1002/mds.20070>
- [18] F. Henry Ellis Jr. Esophagomyotomy for noncardiac chest pain resulting from diffuse esophageal spasm and related disorders. *The American Journal of Medicine*. 1992; 92(5), Supplement 1: S129-S131. [http://dx.doi.org/10.1016/0002-9343\(92\)80068-B](http://dx.doi.org/10.1016/0002-9343(92)80068-B)
- [19] Nastos D, Long-Qi Chen, Ferraro P, Taillefer R, Duranceau A; Long Myotomy With Antireflux Repair for Esophageal Spastic Disorders. *Journal of Gastrointestinal Surgery*. 2002; 6(5): 713-722. [http://dx.doi.org/10.1016/S1091-255X\(02\)00016-1](http://dx.doi.org/10.1016/S1091-255X(02)00016-1)
- [20] Leconte M, Douard R, Gaudric M, Dumontier I, Chaussade S, Dousset B. Functional results after extended myotomy for diffuse oesophageal spasm. *Br J Surg*. 2007; 94(9): 1113-8. PMID:17497756 <http://dx.doi.org/10.1002/bjs.5761>