

ORIGINAL ARTICLES

The evaluation of the association between patella types and chondromalacia patella by magnetic resonance imaging

Alper Hayirlioglu¹, Hilal Doganay², Mehmet Gokce Yilmabasar³, Recep Bilhan Pekar¹

1. Health Minister, Istanbul Medeniyet University, Göztepe Education and Research Hospital, Istanbul, Turkey. 2. Zonguldak Women's and Children's Hospital, Zonguldak, Turkey. 3. Istanbul Kartal State Hospital, Istanbul, Turkey.

Correspondence: Alper Hayirlioglu. Address: Health Minister, Istanbul Medeniyet University, Göztepe Education and research Hospital, Istanbul, Turkey. Email: hayirlioglu@hotmail.com

Received: September 30, 2014 **Accepted:** February 27, 2015 **Online Published:** March 10, 2015
DOI: 10.5430/ijdi.v2n2p21 **URL:** <http://dx.doi.org/10.5430/ijdi.v2n2p21>

Abstract

302 non-traumatic patients, who had an MRI scan of the knee with the suspicion of any diagnosis were evaluated in terms of patella types and their relationship to chondromalacia patella. Outerbridge MRI grading system was used in the evaluation of patellar chondromalacia. Type II patella is the most common type. The distribution of patella type was not statistically significantly different between the two genders ($p > 0.05$). Patella types have no specific distribution. Chondromalacia in varying degrees was seen in 14 patients among 41 with Type I patella (34%), while this rate was 81 out of 207 (39%) in patients with Type II patella, and 34 out of 53 (64%) in patients with Type III patella. One patient with Type IV patella did not have chondromalacia patella. When all patellar types were included, the rate of chondromalacia in females and males was 50% and 34%, respectively.

Chondromalacia was 42.7% in our study. Grade I chondromalacia was observed in 22 knees (12%), Grade II chondromalacia was seen in 32 knees (23%), Grade III chondromalacia was seen in 28 knees (21%), and Grade IV chondromalacia was seen in 49 knees (37%). The frequency of high grade (Grade III and Grade IV) chondromalacia was seen in 59% of cases, while this rate was reported up to 41% in other studies. In our study, the association between Type III patella and chondromalacia was found to be statistically significant.

keywords

Non-traumatic chondromalacia patella, Patella types, MRI

1 Introduction

The knee joint is a joint subjected to the earliest wear in the human body among all joints due to various reasons among all ages.

An important cause of pain in the anterior patella is pathological changes in the retropatellar articular cartilage. The term chondromalacia patella refers to a progressive course of softening of the articular cartilage, fibrillation, thinning, focal protrusions, formation of ulcers, chondral defects, and subchondral erosive changes.

It was reported that the most difficult diagnosis was cartilage pathology among knee problems; furthermore, there are no imaging studies contributing to the diagnosis other than some specific magnetic resonance imaging methods. Arthrography, computed tomography, and computed tomography arthrography, as well as direct radiography, which is the primary imaging technique of the skeletal system, are all inadequate methods to view the joint cartilage. The aim of imaging of cartilage is to evaluate the continuity of the cartilage surface, the thickness of the cartilage matrix, its volume, and its relation to the subchondral bone. Magnetic resonance imaging has currently become the primary diagnostic method in the evaluation of joint pathology, due to its high resolution between tissues and the property of multiplanar imaging^[1-3].

Wiberg and Outerbridge believed the existence of an association between Type III patella and chondromalacia patella, which actually has many etiologic causes^[4-6]. We suggest that the relationship between patella types and patellofemoral diseases can be established. For this reason this study aimed to evaluate whether patella type plays a role in the etiology of a frequently seen pathology, chondromalacia patella.

2 Patients and methods

Retrospectively, a total of 302 non-traumatic patients, aged 18 years or older, including 164 females (54%) and 138 males (46%), who had an MRI scan of the knee between December 2008 and March 2013 at the Goztepe Education and Research Hospital were evaluated. Patients with patella alta and baja variations were excluded from our study. The morphology of the patella in normal and dysplastic knees were displayed, to focus patella types only.

Axial fat-saturated proton density sequences of each patient were evaluated for chondromalacia, and the patella type of each patient was determined. The mean age of the patients was 47 years with a range of 18-75 years (see Figure 1).

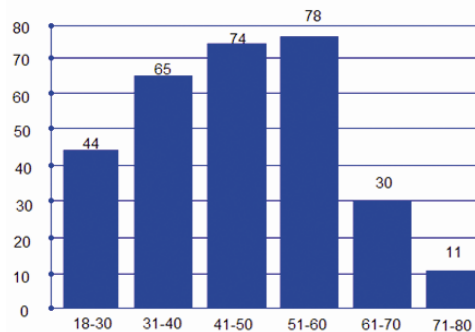


Figure 1. Age distribution of the patients

A 1,5 Tesla GE Signa Excite MR and superficial knee Q coil was used in obtaining images. In the axial fat-saturated proton density weighted sequences, the parameters were as follows: TR: 2860, TE: 48,1/Ef, slice thickness 4mm, FOV 16 × 16, and finally matrix:192 × 256 pixels.

Patella were classified according to Baumgartl's classification^[7]:

Type I patella: medial and lateral facets, both are concave with equal length (see Figure 2)

Type II patella: lateral facet is more prominent compared to the medial facet; medial facet is plane or concave (see Figure 3)

Type III patella: a smaller and convex medial facet (see Figure 4)

Type IV patella: no medial facet or central rim; as also called "Jokey hat" (see Figure 5).

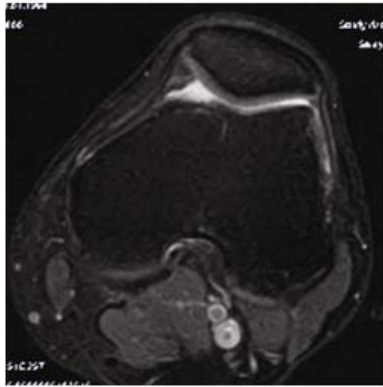


Figure 2. MR image of a patient with Type I patella

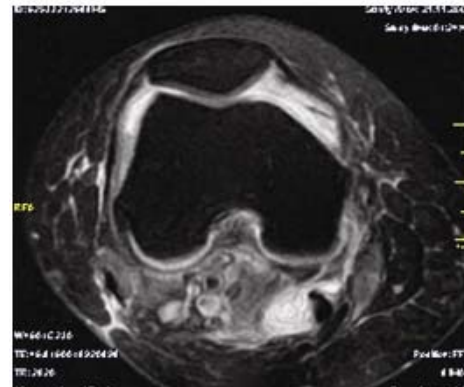

Figure 3. MR image of a patient with Type II patella

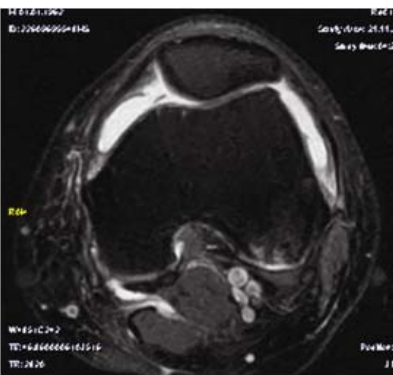

Figure 4. MR image of a patient with Type III patella

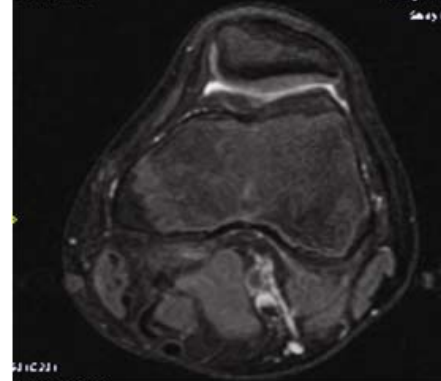


Figure 5. MR image of a patient with Type IV patella

The Outerbridge MRI grading system was used for the degree of patellar chondromalacia [5, 6]

Grade 0: Normal

Grade I: “Softening” or edema in the cartilage without contour irregularity (see Figure 6)

Grade II: Surface irregularity, fissure or focal defect in less than 50% (see Figure 7)

Grade III: Fragmentation, fissure, or defect formation in 50% or more of the cartilage (see Figure 8)

Grade IV: Full thickness loss up to the bone and reactive changes in the subchondral bone (see Figure 9).

Patients were classified according to age, gender, patella type, and grading of chondromalacia and a statistical analysis was performed.

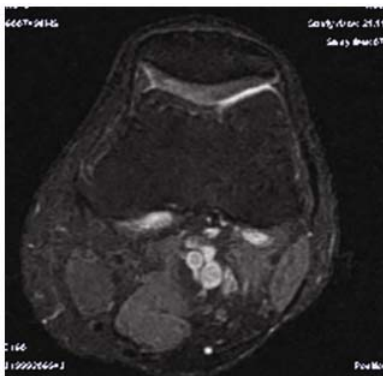


Figure 6. MR image of a patient with Grade I chondromalacia patella

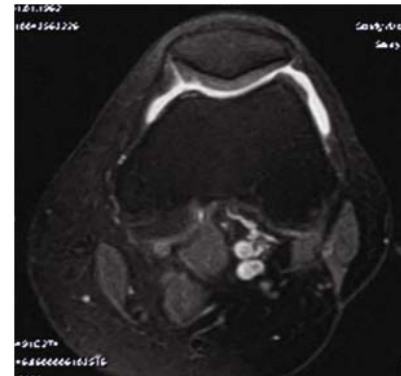

Figure 7. MR image of a patient with Grade II chondromalacia patella

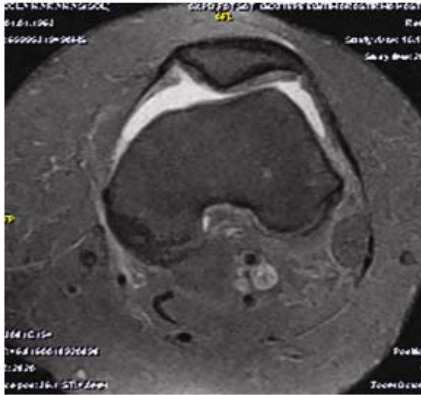

Figure 8. MR image of a patient with Grade III chondromalacia patella

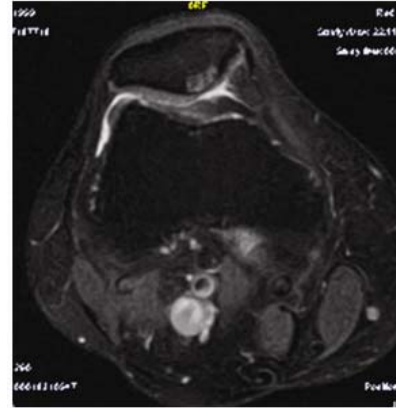


Figure 9. MR image of a patient with Grade IV chondromalacia patella

3 Findings

Patella types of 302 knees of 164 females and 138 males with a knee MRI were evaluated for patella types. Patella Type I, Type II, and Type III were seen in 15 (9.15%), 114 (69.51%), and 35 (21.34%), respectively in females. Type IV patella was not encountered in this group (see Table 1).

The respective rates among men were 18.8% (n: 26), 67.3% (n: 93), 13% (n: 18), and 0.7% (n:1), respectively (see Table 2).

When patella types among the whole series were evaluated, Type I, Type II, Type III and Type IV patella were seen in 13%, 68%, 17.5%, and 0.3%, respectively (see Table 3).

No statistical difference was found between genders in the distribution of patella types ($p > 0.05$).

Table 1. Distribution of chondromalacia types according to the types of patella in female patients

Patella Types (Females)	Total number of patients	Number of patients with chondromalacia
Type I	15	6
Type II	114	50
Type III	35	26
Type IV	0	0

Table 2. Distribution of chondromalacia types according to the types of patella in male patients

Patella Types (Males)	Total number of patients	Number of patients with chondromalacia
Type I	26	8
Type II	93	31
Type III	18	8
Type IV	1	0

Table 3. Distribution of patellar types among patients

Patellatypes	Percentage
Type I	13.57%
Type II	68.54%
Type III	17.55%
Type IV	0.33%

Chi-square tests were used for the statistical analysis. Total chi-square value was found to be 10.07, and the table with an $\alpha = 0.05$ level and 3 degrees of freedom, was found greater than the chi-square value of 7.815. Thus, the groups were found to be different in terms of the presence of chondromalacia patella ($p < 0.05$).

When patients with Grade II (with Type III patella) were excluded and the chi-square test was repeated for Groups 1, 2, and 4, the total chi-square value for the three groups was found to be 1.15, which was less than 5.991, and which is less than the table chi-square value of $\alpha = 0.05$ level with 2 degrees of freedom. Therefore, the groups were found to be similar in terms of the presence of chondromalacia patella ($p < 0.05$) (level of significance was accepted to be 0.05).

No differences were found between patients in the groups with Type I, Type II, and Type IV patella in terms of the development of chondromalacia patella. The rate in patients with Type III patella, on the other hand, was different. The incidence of chondromalacia patella was found to be 64% in cases with Type III patella. The statistical analysis was parallel to these percentages. Chondromalacia patella is seen more frequently in cases with Type III patella compared to others (see Table 4).

When the frequency of chondromalacia was evaluated according to the types of patella, chondromalacia patella in varying degrees was encountered in 6 out of 15 women with Type I patella (40%), 50 out of 114 women with Type II patella (43%), and 26 out of 35 women with Type III patella (74%). Chondromalacia patella in varying degrees was encountered in 8 out of 26 men with Type I patella (31%), 31 out of 93 men with Type II patella (33%), and 8 out of 18 men with Type III patella (44%). Chondromalacia patella was not present in one patient with Type IV patella.

Table 4. Distribution of condromalacia patella among patella types

Patellatype	Patients Chondromalacia/Patellatype	Percentage
Type I	14/41	34%
Type II	81/207	39%
Type III	34/53	64%
Type IV	0/1	0%

In the total series chondromalacia patella in varying degrees was encountered in 14 out of 41 patients with Type I patella (34%), 81 out of 207 patients with Type II patella (39%), and 34 out of 53 patients with Type III patella (64%), while it was not present in one patient with Type IV patella. When all patella types were evaluated together, chondromalacia patella incidence was 50% and 34% of women and men, respectively.

Grade I, Grade II, Grade III, and Grade IV chondromalacia were present in 22 knees (12%), 30 knees (23%), 28 knees (21%), and 49 knees (37%), respectively, in a total of 129 knees with chondromalacia patella. The reason for the high

incidence of high grade chondromalacia (Grade III and Grade IV) as 59% was attributed to the fact that a knee MRI was performed in symptomatic patients.

4 Discussion

In this study, non-traumatic 302 patients were analyzed. In our analyzes, patella types and chondromalacia relationship were evaluated. Since not all of our patients have surgically or clinically proven knee disorders, correlation between chondromalacia and knee disorders was not possible in this study.

Whole series were evaluated with MRI. Patella types rates were found to be similar to Reider's anatomical study; Patella types was not specific^[8].

Chondromalacia patella is a frequent pathology in society with an incidence of up to 63% reported in various studies, while it was found to be 42.7% in our study. High grade (Grade III and Grade IV) chondromalacia is seen in up to 41% of cases with chondromalacia patella, while this rate was found to be 59% in our series. This result might be attributed to the fact that knee MRIs this study were not obtained in the general population, but were performed in symptomatic patients^[9].

In the electron microscopic studies by Osamu Ohno et al. in 1988, the initial pathologic finding was swelling of the superficial matrix, especially in the superficial and transit zone, together with the disturbance of collagen fiber network^[10, 11].

Goodfellow defined the differential diagnosis of age-related superficial degeneration and basic degeneration. The age-related type occurs in the medial facet and includes surface irregularities with no progression. It does not cause progressive full thickness cartilage loss. Basic degeneration, on the other hand, develops on the separated back side of the medial and odd facets^[11, 12].

Hyaline cartilage is the main functional unit of the synovial joints. Biomechanical, environmental, and genetic factors are held responsible for cartilage damage. Pathological changes of the hyaline cartilage of the knee are evaluated as surface and basic degeneration. Surface degeneration is age-related and increases with increased age. The earliest finding is wear and tear of the tangential zone of articular surface. Basic degeneration, on the other hand, occurs in the deep layers of the cartilage. It begins with the radially oriented collagen fascicles. It is seen as focal softening. A histologic examination of the cartilage at this time discloses fissures at the deeper part below the softening region. Fissures result in ruptures extending to the tangential collagen fibers, and less frequently the bullae on the articular face, over time^[11-13]. Cartilage lesions are among the most common lesions, especially in the knee joint. In advanced phases, it is known to cause irreversible damage and a possible ground for osteoarthritis. Cartilage lesions that might accompany many other intraarticular lesions might be symptomatic in certain conditions. On the other hand, some of the failures of treatment of other pathologies may be underlined by cartilage problems. With its highly specialized layers, cartilage continues its function of weight bearing and function of decreasing friction to a minimum. Histologically damaged integrity can be defined as cartilage injury. Its actual incidence is unknown. Noyes et al. reported an incidence of high degree focal cartilaginous lesions to be 5%-10% in young patients with hemarthrosis^[14].

In another study of consecutive arthroscopic interventions in 993 patients, the rate of grade 3-4 focal cartilage lesions that were classified as "appropriate to repair" by the International Cartilage Repair Society (ICRS), was found to be 11%^[15].

In a retrospective study evaluating 31,516 cases, the incidence of cartilage lesion at any degree was found to be 63%^[16]. In this study, where the mean cartilage lesions per one knee was 2.7, the rate of 3rd and 4th degree lesions were reported as 41.4% and 19%, respectively^[17].

Hjelle et al. reported the rate, localization, and dimensions of cartilage lesions in 1000 consecutive knee arthroscopies. According to this, the incidence of chondral and osteochondral lesions at any degree was 61% (16). Mean defect size was 2.1 cm², while 60% of the lesions were placed at the medial femoral condyle. Defect size was found to be less than 1 cm² in individuals between the ages of 40 and 50 years, with a mean incidence of grade 3 and 4 lesions of 6% [16]. Cartilage lesions might be isolated; however, they frequently accompany other intraarticular knee lesions [18].

Cartilage injury has been classified according to various systems in the past. The current classification created by the International Cartilage Repair Society is based on the depth of injury according to the affected layers [15].

In a study evaluating the lesions by only watching video records, Outerbridge classification was demonstrated to end in similar reproducible results among different surgeons [19].

In another study in a cadaver model, the accuracy of the Outerbridge classification was found to be 68% during arthroscopic evaluation, and its reproducibility and compatibility among same observer and different observers was stated to be high [20].

On the other hand, the classification system of the International Cartilage Repair Society not only classifies the lesion, but it is also a system of evaluation with the documentation of local and general factors related to the lesion from the dimensions of the lesion to the extremity involvement and the state of the ligaments and meniscus [21].

At this point, a differential diagnosis of cartilage lesion and osteoarthritis should be made. This is most easily accomplished with the number of lesions and the status of the opposite surface. When the number of lesions is less than three with a normal opposite surface, it is appropriate to classify the lesion as a cartilage lesion, while the opposite lesions are classified as osteoarthritis [21].

Cartilage lesions do not develop at the end of a degenerative process, but as a result of major, minor, or repetitive micro-trauma. The lesion may be acute or chronic according to the time of diagnosis. The main features of the cartilage lesions that differentiate them from osteoarthritis are that they occur after trauma, are focal, are less than three in number, and with normal cartilage at the opposite site of the lesion. Many techniques have been developed for the treatment of cartilage lesions. Although conventional and inexpensive methods, such as drilling and microfracture, have been used for a long time, the newer and more expensive techniques, such as autologous chondrocyte implantation, have also been used in increasing rates. An interesting point is that most of the studies associated with cartilage injury are directed to the treatment of the lesion instead of prevention and diagnosis, despite cartilage injury is very common with possible serious sequels and well documented burden on the health care system economics. There are limited data on the diagnosis, evaluation, and natural course of the disease. The subject of such reports is mostly based on the diagnostic efficacy of magnetic resonance imaging sequences. In addition studies regarding cartilage injury related to patellar morphology are limited in number [1]. The answer to the question of how to diagnose a cartilage lesion without magnetic resonance imaging and arthroscopic examination remains uncertain.

Given these circumstances we believe that our simple but efficient study will contribute to the management of chondromalacia patella and fill in the lack of statistical data on the association between patellar morphology and chondromalacia patella in our country.

There are various opinions about whether the type of patella plays a role in the chondromalacia patella. Wiberg and Outerbridge believed in an association between Type II patella and chondromalacia patella, while many researchers rejected the hypothesis of an association between patella types in the etiology of chondromalacia patella. In this study, Type III patella and chondromalacia were found to be statistically significantly associated. This may demonstrate that convex medial facet anatomy might result in chondral damage related to the uneven weight load distribution.

We suggest that associations between the patella types and patellofemoral diseases will be demonstrated more clearly by comprehensive future studies.

References

- [1] Kaya TB, Semiz OA, Pekar B, et al. The association of patellofemoral joint morphology with Chondromalacia patella: a quantitative mri analysis. *Clinical imaging*. 2014 July-August; 38(4): 495-98. <http://dx.doi.org/10.1016/j.clinimag.2014.01.012>
- [2] Barnett AJ, Gardner ROE, Lankester BJA, et al. Magnetic resonance imaging of the patella. A comparison of the morphology of the patella in normal and dysplastic knees. *J Bone Joint Surg Br*. 2007 June; 89-B(6): 761-65. PMID:17613500 <http://dx.doi.org/10.1302/0301-620X.89B6.18995>
- [3] Schutzer SF, Ramsby GR, Fulkerson JP. Computer tomographic classification of patellofemoral pain patients. *OrthopClin North Am*. 1986; 17: 35-48.
- [4] Wiberg G. Roentgenographic and anatomic studies on the patello-femoral joint *ActaOrthopScand*. 1941; 12: 319-410. <http://dx.doi.org/10.3109/17453674108988818>
- [5] Outerbridge RE. The etiology of chondromalacia patellae. *J Bone Joint Surg Br*. 1961; 43-B: 752-57. PMID:14038135
- [6] Outerbridge RE. Further studies on etiology of chondromalacia patellae. *J Bone Joint Surg Br*. 1964; 46-B: 179-190.
- [7] Baumgartl F. *Das Kniegelenk*. Berlin: Springer 1944.
- [8] Reider B, Marshall JL, Koslin B. The anterior aspect of the knee joint an anatomic study. *J Bone Joint Surg*. 1981; 63-A: 351-6.
- [9] Syed A Ali, Robert Helmer, Michael R Terk. Analysis of the Patellofemoral Region on MRI: Association of Abnormal Trochlear Morphology With Severe Cartilage Defects. *AJR*. 2010 March; 194(3): 721-27. PMID:20173151 <http://dx.doi.org/10.2214/AJR.09.3008>
- [10] Osamu Ohno, Jiro Naito, Tetsuhiro Iguchi, et al. An Electron Microscopic Study of Early Pathology in Chondromalacia of the Patella. *The Journal of Bone and Joint Surgery*, incorporated July. 1988; 70-A(6): 883.
- [11] Gür E, Baydar ML. Patellar kondromalazinin artroskopik tani ve tedavisi. *Acta Othop Traumatol Turc*. 1979 August; 29: 385-390.
- [12] J Goodfellow, DS Hungerford, C Woods. Patello-femoral joint mechanics and pathology. Chondromalacia patellae. *J Bone Joint Surg Br*. 1979 August; 58-B(3): 291-99.
- [13] Rubenstein JD, Li JG, Majumdar S, et al. Image resolution and signal-tonoise ratio requirements for MR imaging of degenerative cartilage. *AJR*. 1997; 169: 1089-1096. PMID:9308470 <http://dx.doi.org/10.2214/ajr.169.4.9308470>
- [14] Noyes FR, Mooar PA, Matthews DS, et al. The symptomatic anterior cruciate deficient knee-Part 1: The long-term functional disability in athletically active individuals. *J Bone Joint Surg*. 1983; 65A(2): 154-162.
- [15] Aroen A, Loken S, Heir S, et al. Articular cartilage lesions in 993 consecutive knee arthroscopies. *Am J Sports Med*. 2004; 32: 211-5. PMID:14754746 <http://dx.doi.org/10.1177/0363546503259345>
- [16] Hjelle K, Solheim E, Strand T, et al. Articular cartilage defects in 1,000 knee arthroscopies. *Arthroscopy*. 2002; 18: 730-4. PMID:12209430 <http://dx.doi.org/10.1053/jars.2002.32839>
- [17] Curl WW, Krome J, Gordon ES, et al. Cartilage injuries: a review of 31,516 knee arthroscopies. *Arthroscopy*. 1997; 13: 456-60. [http://dx.doi.org/10.1016/S0749-8063\(97\)90124-9](http://dx.doi.org/10.1016/S0749-8063(97)90124-9)
- [18] Hooper TR, Potter HG. Imaging of chondral defects. *Op Tech Orthop*. 2001; 11: 76-82. [http://dx.doi.org/10.1016/S1048-6666\(01\)80015-X](http://dx.doi.org/10.1016/S1048-6666(01)80015-X)
- [19] Marx RG, Connor J, Lyman S, et al. ultirater agreement of arthroscopic grading of knee articular cartilage. *Am J Sports Med*. 2005; 654-57.
- [20] Cameron ML, Briggs KK, Steadman JR. Reproducibility and reliability of the Outerbridge classification for grading chondral lesions of the knee arthroscopically. *Am J Sports Med*. 2003; 31: 83-6. PMID:12531763
- [21] Mandelbaum BR, Browne JE, Fu F, et al. Articular cartilage lesions of the knee. *Am J Sports Med*. 1998; 53-61.