

ORIGINAL ARTICLES

Combination of small gap suture with nerve fragments in the experimental study of the rat nerve defects

Hong Zhang^{*1,2}, Rigen Mo¹, Bo Feng², Zun Zhang², Guodong Liu²

¹College of Life Sciences of Inner Mongolia University, Hohhot, China

²Department of Orthopedics, The Third Affiliated Hospital of Inner Mongolia Medical University, Baotou, China

Received: May 5, 2015

Accepted: July 18, 2015

Online Published: September 10, 2015

DOI: 10.14725/dcc.v2n3p22

URL: <http://dx.doi.org/10.14725/dcc.v2n3p22>

Abstract

Objective: To study the effect of nerve fragments and small gap suture of epineurium in peripheral nerve repair.

Methods: (1) The experimental animals were randomly divided into control group, simple small gap suture group, small gap suture combined neural debris group; (2) observing the nerve anastomosis after two weeks; (3) testing nerve fiber regeneration after eight weeks; (4) testing gastrocnemius wet weight ratio after eight weeks; (5) pathological image analysis: the number of regenerated nerve fibers, the diameter and myelin thickness of regenerated nerve fiber were measured.

Results: (1) Scar tissue was formed in traditional suture anastomotic adhesions; in simple small gap suture group, obvious adhesions was not found surrounding the tissue; for combination group of small gap suture with nerve debris, there was no obvious adhesions, and the outer membrane of small gap turned thinner than before. (2) Compared with the normal control group, the wet weight was increased significantly in the small gap suture group; relative to the small gap group, the wet weight was increased significantly in the small gap plus nerve fragments group. (3) Compared with the control group, the total number of myelinated nerve fibers was increased significantly in the small-gap suture group and small gap plus nerve fragments group; the diameter of nerve fibers and myelin thickness were increased significantly in simple small gap group and the small gap plus nerve debris group. (4) Histology showed: Compared with simple small gap suture group, nerve fiber density was increased, arrangement is neat in the small gap plus nerve fragments group.

Conclusions: The nerve fragments plus epineurium small gap suture has a significant role in the repair of peripheral nerve injury.

Key Words: Nerve debris, Nerve repair, Small gap

Peripheral nerve injury is very common in clinic and the regenerative mechanism is complicated. However, the outcome of traditional suture is not satisfactory. Small gap suture has been demonstrated to be effective on axonal regeneration by building a suitable environment, providing a new treatment choice for clinician. Nerve fragments are able to promote nerve regeneration.^[1-3] Based on this, the

study was also designed to compare the outcomes of nerve fragments combined simple small gap suture and traditional epineurium suture, and to explore how small gap suture combined nerve debris effect on the repair of nerve defect, which may provide a reliable and good functional recovery of nerve anastomosis methods for clinical research.

*Correspondence: Hong Zhang; E-mail: bb0472@yahoo.com.cn; Address: The Third Affiliated Hospital of Inner Mongolia Medical University, Baotou, China.

1 Materials and methods

1.1 Experimental animals and groups

A total of 45 adult healthy Wister female rats, weighing 300-350 g, were collected and provided by Animal Experimental Center of Baotou Medical College. The experimental rats were randomly divided into the control group, simple small gap suture experimental group, and small gap suture combined nerve debris test group, with 15 rats in each group. Control group: the direct anastomosis of the adventitia; the small gap suture group: the small gap of the nerve membrane combined saline; the small gap suture combined fragment group: the outer membrane small gap combined the nerve fragment.

1.2 Animal models

After the rats were weighed and anesthetized, a longitudinal small incision (about 3 cm in length) was made on the left lateral surface of the left foot in order to expose sciatic nerve for the transection of the sciatic nerve. The control group was taken with direct anastomosis of the nerve sheath. Simple small gap suture: Transection of sciatic nerve protection and the two ends of the epineurium stripping were performed. Some nerve fibers were wrapped in both sides of the nerve membrane, with 1.5 mm on each side of the nerve, and the outer membrane was anastomotic. Small gap suture combined neural debris group: except for the addition of neural debris, the operation was the same as the simple small gap suture. Sciatic nerve surgery was performed on 2 weeks, 4 weeks and 8 weeks after operation, and the corresponding examinations were made.

1.3 Index testing

General observation. The appearance of anastomotic stoma, adhesion of surrounding tissue and neuroma were monitored at 2 weeks after operation.

Gastrocnemius muscle wet weight measurement. After stripping the bilateral sciatic nerve, the gastrocnemius muscle was taken off at the tendon insertion point, and the wet weight of gastrocnemius muscle was measured by electronic balance. The wet weight ratio of gastrocnemius muscle was calculated by measuring the wet weight of gastrocnemius muscle as 1.

Nerve anastomosis tissue was observed, nerve fiber count, nerve fiber diameter, the thickness of myelin sheath of sciatic nerve were measured as well. A 5 mm sample was collected from anastomotic position of sciatic nerve, and made into paraffin sections thick as 5 μ m. After conventional HE staining, histological observation was performed, and the number of myelinated fibers was counted by computer pathological image analyzer so as to measure the thickness

of myelin sheath and the diameter of fiber.

1.4 Statistical analysis

All the data were processed by SPSS 13 statistical software, and expressed by mean \pm standard deviation ($\pm S$). Single factor analysis of variance and *t*-test were adopted, and $\alpha = .05$ was used as the test standard.

2 Results

2.1 General observation of anastomotic stoma

At 2 weeks after operation, the hyperplastic scar tissue was seen in the anastomotic stoma of the control group. No obvious adhesion was observed with the surrounding tissue at the anastomosis site nor scar tissue hyperplasia in simple small gap suture group. Neither obvious adhesion with surrounding tissue, nor scar tissue hyperplasia was found in small gap suture combined neural debris group, while small gap outer membrane became thinner (see Figure 1).

2.2 Gastrocnemius muscle wet weight ratio

At 8 weeks after surgery: compared with normal control group, the wet weight ratio increased significantly in simple small gap suture group. The ratio was even higher in small gap suture combined neural debris group, which indicated that the group achieved better outcome (see Table 1).

2.3 The number of regenerated nerve fibers, the diameter and myelin thickness of regenerated nerve fiber

After 8 weeks, the pathological section images showed that the number of myelinated nerve fibers increased in the small gap suture group, compared with the control group ($p < .05$). While it increased more significantly in small gap suture combined nerve debris group. The diameter of myelinated nerve fiber and the thickness of myelinated nerve sheath in the experimental groups were significantly higher than those in the control group. Both indexes were higher in the small gap suture combined nerve debris group obviously than in simple small gap suture group (see Tables 2-3).

2.4 Histological observation

After 8 weeks, the diameter of nerve fibers in the control group was not the same, showing irregular arrangement, and the myelinated nerve fibers were disordered. The continuous distribution of the regenerated nerve fibers with regular

arrangement was observed in both simple small gap suture group and small gap suture combined nerve debris group, and the nerve fibers were arranged in a wavy and orderly manner. Moreover, the nerve density of the small gap suture combined nerve fragment group increased compared with the simple small gap group (see Figure 2).

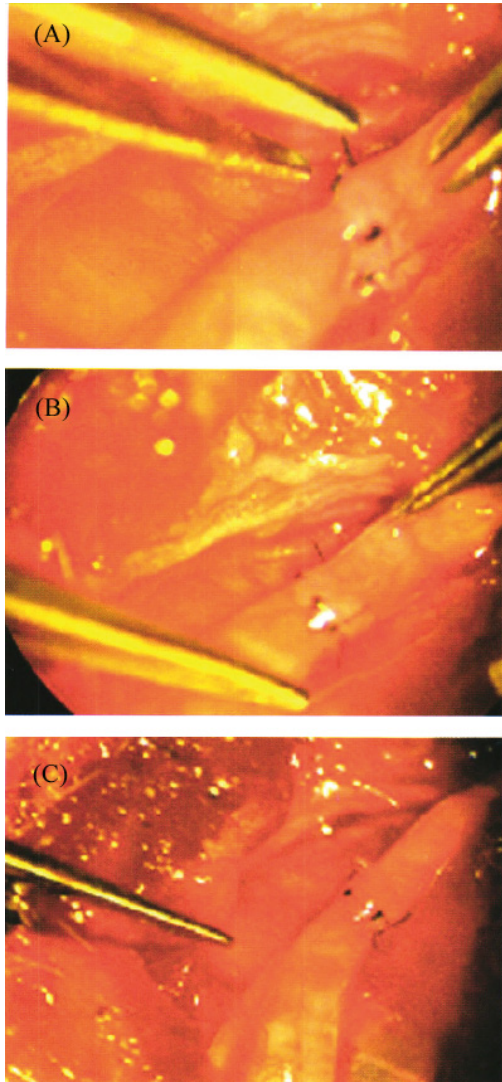


Figure 1: Observation of neural anastomosis at 2 weeks after operation
 A. Control group; B. Simple small gap suture group;
 C. Small gap suture combined neural debris group

Table 1: Wet weight ratio of gastrocnemius muscle (8 weeks after operation)

Groups	n	Wet weight ratio (%)
Control group	15	53.93 ± 2.25
Experimental A	15	60.71 ± 1.69
Experimental B	15	66.10 ± 2.05

Table 2: The number of myelinated nerve fibers (8 weeks after operation)

Groups	n	Number of nerve fibers (rootlets/×200)
Control group	15	254.98 ± 6.29
Experimental A	15	301.94 ± 2.64
Experimental B	15	321.24 ± 1.25

Table 3: Diameter of nerve fiber and thickness of myelin sheath (8 weeks after operation)

Groups	n	Diameter of nerve fiber (μm)	Thickness of myelin sheath (μm)
Control group	15	3.27 ± 0.36	0.42 ± 0.06
Experimental A	15	4.12 ± 0.16	0.79 ± 0.03
Experimental B	15	5.17 ± 0.11	1.15 ± 0.03

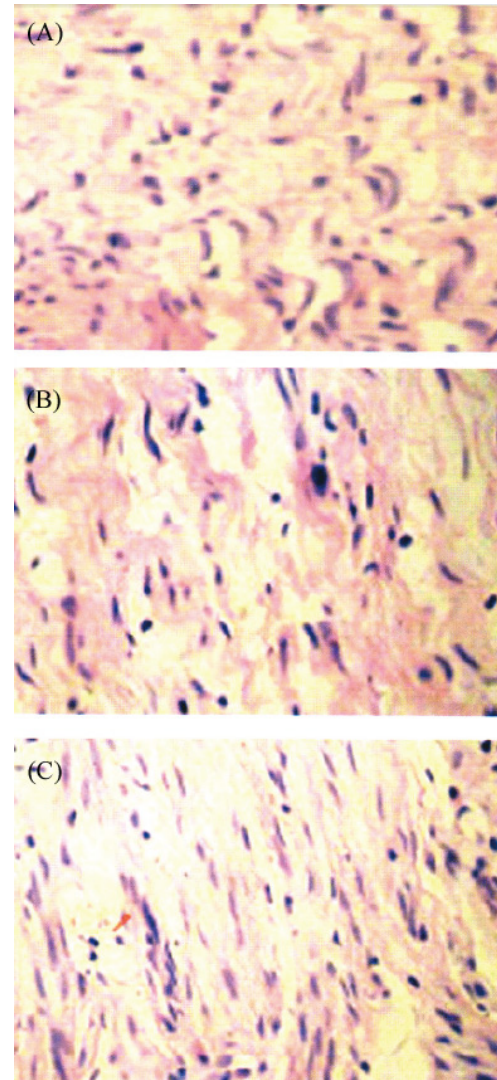


Figure 2: Histological observation of neural anastomosis
 A. Control group; B. Simple small gap suture group;
 C. Small gap suture combined neural debris group

3 Discussion

3.1 Effective space for nerve regeneration provided by small gap suture

Peripheral nerve injury is very common in clinic. Although the micro technology has been greatly improved, the outer membrane of perineurial anastomosis and nerve anastomosis are the primary treatment. However, the wrong alignment of the nerve bundle, the omission of the nerve bundle (escape from the stump) and the connective tissue hyperplasia of the stoma could not be completely avoided.

The primary condition for the success of nerve regeneration and function recovery has been demonstrated to be related with a suitable physiological microenvironment, in which appropriate promoting factors and the selective regeneration biological space could be supplied.^[4-6] Small gap suture was applied in our study to provide small clearance for the regeneration of rat sciatic nerve, and create basic conditions of nutrition and chemotaxis. Epineurium small gap anastomosis was proved to be better than the direct anastomosis with regard to nerve regeneration and functional recovery based on the general observation of the morphology of the anastomotic stoma, the pathological analysis of the nerve regeneration and the observation of histology in the experimental animals. The approach of small gap suture made the regenerated nerve separate from the surrounding tissue, and no regenerated nerve fiber leakage at the broken end was observed, and the number of regenerative nerve fibers entered into the distal end was more than traditional suture. At the same time, this method also lightened the anastomotic tension, and alleviated the infiltration of inflammatory cells to nerve. In that case, the occurrence of anastomotic scarring could be effectively prevented as well as the chance of ineffective growth or neuroma formation caused by forced docking from direct suture.

3.2 The advantages of nerve debris suture in small gaps suture

Nerve growth factor can promote nerve regeneration. It has been found that the addition of nerve fragments into the vein or skeletal muscle bridge contributes greatly to regeneration of the peripheral nerve.^[7,8] Nerve fragments have been proved to accelerate the growth of Schwann cells in this experiment. Schwann cells are glial cells of the peripheral nervous system. It is closely related with the occurrence, development and function of peripheral nerve, and plays an important role in the regeneration of peripheral nerve injury and repair process. Moreover, the substances produced by Schwann cells are crucial for axon regeneration, such as nerve growth factor, brain-derived neurotrophic factor, cell adhesion factor and extracellular matrix,^[9,10] which are beneficial to the regeneration of nerve. Degeneration of nerve debris results in the formation of large amounts of myelin phospholipid, which promotes Schwann cell proliferation. On the other hand, axonal debris can provoke the growth of Schwann cells directly.

The regeneration of damaged nerve requires an environment with many factors. Nerve debris is the factor that contributes to the formation of microenvironment. At the same time, epineurium and perineurium in our experiment were removed from nerve fragments, with only nerve fiber left to prevent the proliferation of fibroblast, which provides a multi-factor environment for nerve regeneration.

To sum up, nerve debris combined with small gap suture of the nerve sheath imposes a significant effect on the repair of peripheral nerve injury, and lays the foundation for the repair of peripheral nerve injuries.

Conflicts of Interest Disclosure

The authors have no conflict of interest related to this article.

References

- [1] Yang SA, Shu XQ, Liu NF. Repair of peripheral nerve injuries with suture of small gap. *Chinese Journal of Microsurgery*. 2003; 26(1): 56.
- [2] Pfister LA, Papaloizos M, Merkle HP, et al. Nerve conduits and growth factor delivery in peripheral nerve repair. *Journal of the Peripheral Nervous System*. 2007; 12(2): 65-82. PMID: 17565531. <https://doi.org/10.1111/j.1529-8027.2007.00125.x>
- [3] Song CZ, Gu YD, Xu JG. Comparison of the effect of direct nerve anastomosis and small gap sleeve repair under different contraposition conditions. *Chinese Journal of Hand Surgery*. 1998; 14(4): 253.
- [4] Yin WT, Pan Q, Cui SS, et al. Preliminary report of clinical application of nerve growth factor promoting peripheral nerve regeneration. *Chinese Journal of Hand Surgery*. 1997; 13(1): 6-8.
- [5] Dong MM, Yi TH. Stem cell and peripheral nerve injury and repair. *Facial Plastic Surgery*. 2010; 26(05): 421-428. PMID: 20853234. <https://doi.org/10.1055/s-0030-1265023>
- [6] Gordon T, Tyreman N, Raji MA. The basis for diminished functional recovery after delayed peripheral nerve repair. *Journal of Neuroscience*. 2011; 31(14): 5325-34. PMID: 21471367. <https://doi.org/10.1523/JNEUROSCI.6156-10.2011>
- [7] Madison RD, Robinson GA, Chad Aram SR. The specificity of motor neuron regeneration (preferential reinnervation). *Acta Physiologica*. 2007; 189(2): 202. PMID: 17250570. <https://doi.org/10.1111/j.1748-1716.2006.01657.x>
- [8] Hei FZ. Repair of nerve injury with sleeve anastomosis of nerve sheath. *Jilin Medical Journal*. 2008; 9(21): 11.
- [9] Yuan WQ. Clinical observation of small gap outer sleeve suture. *Journal of Minimally Invasive Medicine*. 2008; 3(6): 595.
- [10] Yin WT. Experimental study on repair of peripheral nerve fracture with small gap bridging and adventitial anastomosis. *Journal of Jilin University (Medicine Edition)*. 2005; 31(6): 116.