

## CASE REPORTS

# Thyroid-associated eye disease

Xiangyang Xin \*, Lili Gao, Xiping Kong, Chengkun An, Bin Shen

*The Third Affiliated Hospital of Inner Mongolia Medical University, Hohhot, China*

**Received:** January 1, 2015

**Accepted:** February 2, 2015

**Online Published:** June 15, 2015

**DOI:** 10.14725/dcc.v2n2p34

**URL:** <http://dx.doi.org/10.14725/dcc.v2n2p34>

## Abstract

A case of thyroid associated ophthalmopathy (TAO) in the third affiliated hospital of Inner Mongolia medical university was collected and analyzed by the experts for their diagnosis, auxiliary examination and treatment. We hope to improve the clinician's understanding towards TAO and accumulate experience in the treatment of the disease because this disease is rare and the treatment plans are various.

**Key Words:** Rectal cancer, Liver metastases, Neoadjuvant therapy, Surgery

## 1 Medical record

### 1.1 General information

A 38-year-old female patient was admitted to our hospital on December 3, 2011 due to exophthalmos in the right eye for two years duration and which was aggravated six months back. The patient was referred to our department because of right eye proptosis two years ago, without redness, eye pain or decreased vision, and was diagnosed as thyroid related ophthalmopathy in the right eye by systemic examination. She was treated with local injection of Triamcinolone Acetonide and systemic oral corticosteroid therapy, while the effect was not good. After half a year, intravenous methylprednisolone acetate methylprednisolone impact treatment was performed, and symptoms and signs were all relieved. She went to our department for treatment as the symptom of right eye proptosis worsened in recent six months, and was admitted to our hospital for "Thyroid-associated orbitopathy in the right eye". Outpatient department examination showed that T3, T4 and TSH were normal. The patient's mental state was normal and thyroid enlargement was not found since the onset of the disease. Food and drink, urination and defecation were all normal. Past medical history

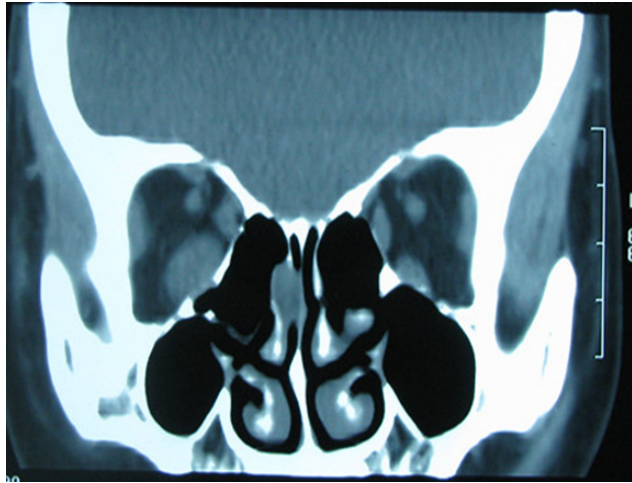
included 5 years of hyperthyroidism treated with oral therapy.

### 1.2 Physical examination

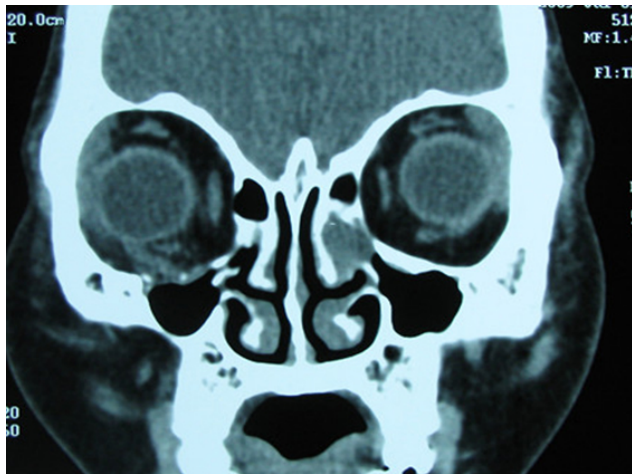
T 36.8 °C, P 80 beats/min, R 20 times/min, BP 110/90 mmHg. His systemic condition is general. Thyroid enlargement or tenderness is not found, without shaking hands. Double lung breath sounds resonance. The heart rate indicates regularity in the force and rhythm of the heartbeat, and no murmur is heard. Babinski's sign is negative and meningeal irritation sign is negative as well. Ophthalmology examination results: visual acuity: OD 0.8 OS 1.0. Right upper eyelid is retracted, upper lid lies 1 mm below the superior corneal limbus, palpebral fissure measures 10 mm horizontally. Corneal transparency, pupil size and reflex are normal, and no congestion is detected in the conjunctiva. Both crystalline lens and vitreous body are transparent. Fundus examination results: the boundary of optic papilla is clear and its color is normal. Macular reflection is normal. The anterior segment of the left eye as well as fundus is normal. Intraocular pressure examination results: 17 mmHg in the right eye, 15 mmHg in the left eye. The

\*Correspondence: Xiangyang Xin; E-mail: 2435303314@qq.com; Address: The Third Affiliated Hospital of Inner Mongolia Medical University, Hohhot, China.

upward movement in the right eye is limited. The eyeball movement towards any direction is normal. Ocular position: corneal reflection is normal in the positive position. Degree of exophthalmos examination results: 18 mm of the right eye, 12 mm of the left eye, and orbital distance is 101 mm. Orbital pressure examination results: right eye T+2, left eye Tn.



**Figure 1:** Preoperative CT examination



**Figure 2:** Postoperative CT examination

**1.3 Auxiliary examination**

Auxiliary examination after admission. Increased orbital fat volume and density were identified by CT scan. On CT imaging, orbital septum protrusion, inferior rectus muscle hypertrophy in spindle shape, and mild medial rectus muscle hypertrophy were all shown (see Figure 1). B-ultrasound examination showed: the inferior rectus muscle progressed into spindle shaped hypertrophy in moderate intensity, the fat pad increased, and the echo extended backward along the optic nerve.

**1.4 Primary diagnosis**

- (1)Thyroid associated eye disease in the right eye
- (2)Hyperthyroidism

**1.5 Diagnosis and treatment**

Right orbit incision decompression was performed under general anesthesia after all relevant examinations were taken.<sup>[1]</sup> Skin of lower eyelid incision approach started and parallel palpebral margin incision was conducted at 2 mm under lower eyelid eyelashes. The orbital margin was firstly exposed when the skin, orbicularis muscle and orbital septum were separated, and periosteotomy was subsequently conducted to show the complete inferior wall of orbit. Protect the infraorbital nerves and blood vessels. Ripped orbital floor and removed the orbital wall on both sides, and lower mucosa was removed. The backward side could reach up to orbital apex, outward to maxillary lateral wall. Multiple periosteal incision and backward separation were carried out in orbital wall region in order to make orbital fat protrude into the maxillary sinus and retain central orbital periosteum to support eye. Postoperative anti-inflammatory and hemostatic treatment were followed, and their effect was good. After the surgery, the symptom of exophthalmos disappeared and ocular movement turned to normal, without occurrence of diplopia. There was no recurrence at 2-year postoperative follow-up.

**2 Discussion**

**2.1 Dr. Chengkun An**

*Dr.Chengkun An is a postgraduate 2011 at Third Affiliated Hospital of Inner Mongolia Medical University.*

Thyroid-associated ophthalmopathy (TAO) is autoimmune disorder with underlying mechanisms that are still being explored, whose occurrence of onset ranks peak among adult patients with orbital disease. Regardless of the common ocular signs, it is often accompanied by varying degrees of thyroid disorders such as hypothyroidism and hyperthyroidism. The first description of TAO could be dated to 200 years back, known by many names, including Graves ophthalmopathy, endocrine exophthalmos of Graves’ disease, malignant exophthalmos and infiltrative exophthalmos. The age range of the disease is large, from young to advanced age. The prevalence of gender is somewhat characteristic, among which middle-aged female patients are usually associated with hyperthyroidism, while male patients are presented with ocular signs and thyroid function is normal. In recent years, many foreign scholars proposed that the pathogenesis of TAO was closely related to the environment, genetic, immune and other factors.<sup>[2]</sup>

### 2.1.1 Study of pathogenetic mechanism

1) **Study on the common antigen of orbital tissue of thyroid gland.** Thyroid disease is an autoimmune disease characterized by a marked heterogeneity in the clinical presentation, with involvement of the thyroid, eye and skin. Most patients with TAO had a medical history of thyroid disease. Orbit becomes the functional thyroid-stimulating hormone receptor expressed by fibroblasts, also known as cross antigen of thyroid follicular cell membranes. Thyroid stimulating antibodies, antithyroglobulin, antithyroid autoantibodies, thyrotropin receptor antibodies are the main antibodies to the thyroid stimulating hormone receptor. Serum thyroid-stimulating antibody concentration has been demonstrated to correlate with quantitative indicators of TAO, such as degree of exophthalmos and other clinical manifestations measurements.<sup>[3]</sup>

2) **Membrane antigen of extraocular muscle.** Soluble antigen and membrane antigen of some extraocular muscle and orbital tissues may also serve as a common antigen including 55kDa, 64kDa and 95kDa protein.

3) **Cellular immune.** There are a lot of researches on thyroid associated ophthalmopathy cellular immune response, including cellular immune abnormality, lymphocyte subsets imbalance, decrease function of T cell, excessive enhancement of B cell activity, decrease of CD8 cells, and increase of CD8/CD4 ratio. T cell subsets (T cell subset) and natural killer cells (nature killer cell) undergo non-specific changes in some patients, and antibody-dependent cellular cytotoxicity against human extraocular muscle antigen appears and produces immune cross-reaction between orbit and thyroid.

4) **Cytokines.** Some progresses in the study on the correlation between the level of cytokines and pathogenesis of thyroid associated diseases have been made. Cytokines, as a letter or sign in biological control language, is a peptide regulatory of heterogeneity with a wide range of biological activity, produced by immune cells and non-immune cells during the process of systemic inflammatory and immune response.

### 2.1.2 Study of pathological mechanism

The main pathological changes of TAO are inflammatory responses of the orbital soft tissues and the external muscles of the eye. Early pathological changes are the infiltration of lymphocytes and plasma cells in the connective tissue of the extraocular muscles. Normally, extraocular muscle is composed of muscle fascicle and muscle fiber. Muscle fascicle is wrapped by perimysium, while each muscle fiber in muscle fascicle is wrapped by endomysium. The fibroblasts in the endomysium may produce glycosaminoglycan and then collagen when activated. Glycosaminoglycan, on the other hand, may potentially result in tissue edema due to the combination of polyanion and water, a main cause of post ocular tissue swelling. During the chronic phase of the disease, the

involvement of the collagen deposition of extraocular muscle would cause fibroblast proliferation, fiber proliferation and fat deposition. The appearance of fat deposition plays a significant role in reflecting the long-term chronic process of the disease.<sup>[4]</sup>

## 2.2 Dr. Bin Shen

*Dr. Bin Shen is a postgraduate 2012 at Third Affiliated Hospital of Inner Mongolia Medical University.*

The main clinical manifestations of TAO are the ocular signs, which can be summarized as follows: 1) Eyelid changes, characterized by eyelid retraction and lid lag on down gaze. Eyelid retraction could occur in both sides, especially in upper eyelid, accompanied by eyelid swelling or edema. 2) Changes of extraocular muscle, extraocular muscle hypertrophy in fusiform shape. Pathological examination visualized muscle fiber hypertrophy, inflammatory cell infiltration, degeneration, atrophy and fibrosis, causing eye movement disorder and diplopia. 3) Proptosis, orbital soft tissue edema, inflammatory cell infiltration, thickening of the fat pad. Exposure keratitis and secondary infection may even appear in severe degree. 4) Decreased vision due to optic neuropathy, because of joint compression from edema and muscle hypertrophy at orbit apex. In addition, the symptoms also include increase of the orbital pressure, enlargement of lacrimal gland conjunctiva and lacrimal caruncle, edema and so on. It is a common disease in the Department of ophthalmology and Department of internal medicine. Its incidence rate occupies the first place in adult patients with orbital disease, accounting for nearly 20 percentages. It not only affects the appearance of patients but also seriously affects the work and life of patients due to exophthalmos and diplopia, corneal exposure, optic nerve compression, visual impairment, even blindness, bringing great pain to the patients. Though great progresses have been made regarding the etiology, pathogenesis diagnosis and treatment of the disease, the remaining problems and difficulties, has attracted many scholars' great attention into depth study. Imaging examination of TAO carries certain characteristics. CT examination showed consistency fusiform swelling in single or more extraocular muscles. Normal tendon insertion serves as an important sign that differentiates the disease from extra ocular myositis. The high density of the orbital apex is another characteristic feature of CT scan of TAO, which is caused by joint swelling of many extraocular muscles in the orbital apex. On B-scan ultrasound of orbit, extraocular muscles are bulky predominantly and fat pad is thickening. 5) Soft-tissue involvement. Regardless of inflammatory cell infiltration, dilatation and congestion of blood vessels, increased permeability and increased interstitial fluid, the significant increase of glycosaminoglycans deposition between tissue space and great uptake of water by the tissue, contribute to the eyelid, conjunctiva congestive

red and orbital soft tissue swelling, such as eyelid, conjunctiva and lacrimal gland, among which soft tissue involvement is especially obvious in patients with acute TAO and infiltrative exophthalmos. Patients often experience associated symptoms, such as eye discomfort, dryness, eye pain, foreign body sensation, photophobia, lacrimation, diplopia, decreased visual acuity when eye soft tissue is involved.

The clinical manifestations of our case include: right upper eyelid is retracted, upper lid lies 1.5 mm below the superior corneal limbus, palpebral fissure measures 10mm horizontally and the eye upward movement is limited. Degree of exophthalmos: 18mm of the right eye, 12 mm of the left eye, and orbital distance is 101mm. Orbital pressure: right eye is T+2, and left eye is Tn. All the symptoms of the patients satisfies the clinical characteristics of TAO, by which the diagnosis of TAO was established.

### 2.3 Dr. Lili Gao

*Dr. Lili Gao, Chief Physician, professor and Postgraduate Tutor in Third Affiliated Hospital of Inner Mongolia Medical University, specializes in cataract and ophthalmic plastic surgery.*

The diagnosis of TAO is not difficult. The typical ocular signs and objective evidence include:

- (1) Eyelid swelling, superior eyelid retraction, lid lag, decrease of the blink reflex, monocular or binocular progressive protrusion.
- (2) Involvement of ocular muscle, limitation of motion, diplopia and strabismus
- (3) Enlargement of ocular muscle assessed by ultrasound, CT scan and MRI examination

Laboratory test results for TAO varied in different types. Thyroid iodine uptake increased as well as T3 and T4, and thyroid stimulating hormone (TSH) decreased according to nuclide measurement when TAO is associated with hyperthyroidism. T3, T4, free T3 and free T4 are in normal level when thyroid functions well in patients with TAO. In rare cases, TAO are undiagnosed. A lot of orbital diseases contribute to proptosis, and eyelid retraction may be caused by many other diseases so that TAO is often mistakenly diagnosed as orbital tumors and treated with orbital wall incision. Therefore, the incidence that no orbital tumor is found during the surgery often occurs. Laboratory examination, ultrasonic, CT scan, magnetic resonance imaging, eyeball traction test and check of intraocular pressure etc. are advisable for an accurate diagnosis, especially for easily misdiagnosed cases, to avoid the recurrence of similar misdiagnosis, unnecessary orbital surgery and biopsy.

The clinical manifestations and imaging findings of the patients are consistent with the diagnosis of thyroid associated diseases. The three main features of TAO are eyelid

retraction, eye protrusion and hypertrophy of the external muscles. The differential diagnosis should be distinguished from the 3 aspects.

### *Orbital pseudotumor*

Orbital pseudotumor is a nonspecific inflammatory process of unknown origin, characterized by orbital mass. It is divided into three types according to the pathological changes: lymphocytic infiltration type, fibroblast proliferation type and mixed type. In addition, conversion of the three types is possible in some patients. A variety of tissues would be involved, among which hypertrophic myositis (also known as hypertrophic myositis) often mixes up with the disease. Hypertrophic myositis often involves one muscle and the lesions usually invade terminations of muscles. Congestion could be detected at the termination of muscles in most cases through bulbar conjunctiva. On CT imaging, the termination of muscles is bulky predominantly. It is similar to TAO in condition that muscle fibrosis causes eye position deviation and eye movement disorders. But hypertrophic myositis lesions rarely involve Müller muscle and levator muscle, so that eyelid retraction and lag syndrome are not included.

### *Carotid Cavernous Fistula (CCF)*

The clinical manifestations of CCF include: orbital soft tissue hyperemia, multiple muscle hypertrophy, pulsating exophthalmos, eyes dilated veins and orbital vascular murmur, superficial venous of conjunctiva dilatates corneal limbus in read and thread shape, chamber angle examination reveals congestion of Schlemm's canal. On CT scan, extraocular muscle was tested to be enlarged and superior ophthalmic vein were found thickening and other vascular dilatation.

### *Passive enlargement of the extraocular muscles*

External muscle hypertrophy is caused by the oppression or direct invasion of the orbital occupying lesions. However, the latter could be identified with other diseases by some specific signs.

### *Lesions of extraocular muscles*

Cysticercosis of extraocular muscle or intramuscular hemangioma contributes to the formation of muscle hypertrophy. It only presents in single muscle and has own clinical features, without the symptoms of eyelid retraction or lid lag.

### *Clande - Bernard syndrome*

5. It is necessary to identify eyelid retraction of TAO with upper eyelid retraction deformity caused by excessive correction of the upper eyelid, trauma and inflammation.<sup>[5]</sup> Eyelid retraction may also appear when sympathetic nerve is stimulated, such as Clande - Bernard syndrome.

The patient was with right upper eyelid retraction so that the diagnosis of orbital pseudotumor, carotid cavernous fistula, lesions of extraocular muscles were ruled out. Usually, ocular muscle thickening would not occur in patients with upper eyelid retraction deformity caused by excessive correction of ptosis, trauma, etc, or patients with eyelid retraction resulted from damage within the brainstem region, stimulation of sympathetic nerve. Regardless of eyelid retraction, the patient also experienced inferior rectus thickening so that the diagnosis of above disease are excluded.

## 2.4 Dr. Xinping Kong

*Dr. Xinping Kong is an associate chief physician of Ophthalmology Department at the Third Affiliated Hospital of Inner Mongolia Medical University, specializing in the treatment of retinal disease and orbital disease.*

The management of TAO includes surgical treatment and non-surgical treatment. While non-surgical treatment refers to the following methods.

### 2.4.1 Drug Treatment

**(1) Antithyroid drugs:** The antithyroid drugs (ATD) are introduced in 1940 when TAO is associated with hyperthyroidism, showing curative rate of 30%-40%. TSH receptor antibody (TRAb) is the main cause of the disease. The application and effective outcome of ATD on TAO associated with hyperthyroidism is lack of prospective studies.<sup>[6,7]</sup> Current clinical application of ATD in combination with oral prednisone turns out to carry a more increased curative rate.

**(2) Immunosuppressor:** A consensus has been reached among medical community that TAO is an autoimmune disease. At present, it is generally accepted that glucocorticoid is one of immunosuppressive agents with definite therapeutic effects, and its main function is anti-inflammation and immune suppression. Corticosteroid therapy can be employed in a variety of ways, such as oral, topical (retroocular or subconjunctival) injection and intravenous drug use. Oral corticosteroids may bring some side effects and complications in a larger dose. In addition, TAO would reappear after hormone withdrawal or during reduction process. During the past decades, clinical studies mainly focused on intravenous injection for administration, whose common measure is to use large dose of methylprednisolone acetate methylprednisolone for impact therapy. Impact therapy turns out to be quite a reliable treatment method with faster curative effect, less side effects and difficulty recurrence, comparing with oral hormone.

The clinical effect of cyclosporine in the treatment of autoimmune disease has been widely accepted. It may impact humoral immunity and cellular immunity by inhibiting T lymphocyte activation, monocyte and macrophage antigen

expression, inducing T helper cell activity and inhibiting cytokine production. It is of great value to narrow the enlargement of the extraocular muscles, relieve exophthalmos, and improve the sensitivity, and bring down the total clinical activity score of eyeball, while its overall effect of the treatment of TAO is still controversial. Some studies proposed that the combination of cyclosporine and corticosteroids had advantage over single use of any drug, especially for patients who need long-term intervention with steroid resistance and disease activity. The combination of drug therapy is suggested as the effect of any single drug is poor.<sup>[8]</sup> In view of the side effects, such as high blood pressure, elevated liver aminotransferase, serum creatinine level, and high prices, its clinical application is restricted.

**(3) Somatostatin analogs:** Somatostatin is identified as a hormone that inhibits secretion of growth hormone and many cytokines, including tumor cells. It not only inhibits TRH, TSH, T3, T4 secretion,<sup>[9]</sup> also hinders the growth of thyroid for patients with thyroid diseases. Octreotide is a kind of somatostatin analogs with long-term effect and its function is more effective when compared with glucocorticoid. Octreotide is a long-acting somatostatin analogues, which is more effective to reduce glucocorticoid, especially for clinical activity score of TAO.

In addition, it reduces inflammation, improves the ocular movement disorder, and decreases the formation of glucosamine.<sup>[10]</sup> Although somatostatin is not as good as corticosteroids in reducing muscle volume, it avoids the side effects that produced by corticosteroids. The reaction of octreotide can cause headache, fatigue, edema and high blood sugar. Octreotide has a short half-life so that daily repeated injection is needed. We could achieve little side effects if we overcome the shortcoming, but the price is relatively higher.<sup>[11]</sup>

**(4) Cytokine antagonists:** Nowadays, the effect of soluble cell receptors, natural or synthetic cytokine antagonists and anti-inflammatory cytokines in the treatment of severe inflammatory disease is still in progress. Some investigators found that soluble IL-1 receptor (IL-1R) and IL-1 receptor antagonist (IL-1ra) antagonists could inhibit IL-1 stimulation of glycosaminoglycan synthesis and secretion, such as pentoxifylline (IL-1 antagonists agent). Pentoxifylline, on one hand, significantly inhibits the activity of cytokines. On the other hand, pentoxifylline inhibits human leukocyte antigen DR (HLA-DR) expression which is mediated by IL-1, tumor necrosis factor (TNF) - alpha interferon gamma (TNF gamma), and it also hinders glycosaminoglycan synthesis in orbital fibroblast cell. It serves as a useful role in relieving soft tissue swelling, but its function towards exophthalmos and extraocular muscle is ineffective. The serum levels of GAG and TNF- were also decreased in the patients with ocular symptoms.

**(5) High-dose intravenous immunoglobulin:** High-dose intravenous immunoglobulin is feasible through a variety of

mechanisms, such as inhibitory receptors on immunocompetent cells down, inhibition of cytokine release and the cytokine receptor regulation, immune lysis complement, and unique resistant antibody blocking antigenic determinant<sup>[12]</sup> to inhibit autoimmune reaction.<sup>[13]</sup> Its clinical application is limited due to the higher cost.

#### 2.4.2 Plasma exchange therapy

Plasma exchange therapy is feasible for patients at advanced stage. It not only eliminates or reduces the disease associated antigen, antigen antibody complexes and certain cytokines, but also affects the plasma viscosity and plasma composition. However, the exact curative effect is still remains to be explored, and the use of corticosteroids or immunosuppressive agents (cyclophosphamide or azathioprine) should be combined during clinical practice.

#### 2.4.3 Orbital radiation therapy

The mechanism of orbital radiation therapy is non-specific anti-inflammatory effect, and the lymphocytes in the orbital invasion are highly sensitive to radiation. Usually low dose radiation can inhibit the lymphocyte, change proportion of helper / inhibit the T lymphocytes. In addition, radiation therapy can reduce the production of amino dextran in the orbital tissue fibroblasts. A variety of ophthalmic manifestations were responsive to radiotherapy, total efficiency is about 60%, among which soft tissue change, optic neuropathy and newly extraocular muscle involvement were with excellent results. But the function to reduce proptosis and improve muscle activity is ineffective, especially for the long-term involvement of extraocular muscles. Beyond that, it carries poor efficacy in the disease of longer course, while its results are more satisfactory for rapid progressive eye disease. Compared with glucocorticoids, orbital radiotherapy is more effective in the aggravating or new occurrence of eye disease. It may take a few days, or even several weeks to demonstrate the radiotherapeutic effects. Radiation therapy is relatively sensitive in patients with progressive proptosis, ocular movement disorder and early neurological signs of compression in whom hormone treatment failed.<sup>[14]</sup>

#### 2.4.4 He-Ne laser acupoint irradiation

Wang Haiyan, et al.<sup>[15]</sup> proposed that application of He Ne laser acupoint irradiation in the treatment of Tao is a safe and effective method according to the physiological mechanism of laser and laser acupuncture theory.

The patient has been treated with local injection of Triamcinolone Acetonide and systemic oral corticosteroid therapy with deficient effect. However, symptoms and signs were relieved when intravenous methylprednisolone acetate methylprednisolone impact treatment was employed after half a year. In view of the younger age, comprehensive economic reasons and the need to improve the appearance, the

patient is more suitable for surgical treatment.

### 2.5 Dr. Xiangyang Xin

*Dr. Xiangyang Xin is an associated chief physician in the Department of Ophthalmology, at the Third Affiliated Hospital of Inner Mongolia Medical University, specializing in the treatment of orbital diseases, cataract, ocular trauma.*

The clinical manifestation of TAO is divided into two types. TAO accompanied by hyperthyroidism, frequently termed Graves ophthalmopathy, mostly occurs in young women at bilateral side. The inflammatory response of the lesion was obvious and sensitive to glucocorticoid treatment, and the pathological changes of the orbital soft tissue were slow so that the lesions were easy to treat and can reoccur despite treatment. Another type is with simple ocular signs, known as ophthalmic Graves' disease, thyroid function tests are normal (a few or even lower), but TSH and other endocrine hormone or certain antibodies are abnormal. It usually presents in middle-aged men unilaterally or bilaterally, varying in clinical inflammatory response. It is mild at the initial stage but aggravates to serious condition at the late stage. Occurrence of fibrosis lesions are commonly seen in involved tissues, most of the response to glucocorticoid therapy was slightly worse, and the clinical symptoms were not typical.

Graves is an autoimmune disease that is closely associated with hyperthyroidism, the pathogenesis of which remains uncertain. The underlying pathogenesis is due to lymphocytes-dominated inflammatory reaction triggered by autoantibodies against extraocular muscle and orbital fat, resulting in orbital tissue deposition of mucopolysaccharides, mainly hyaluronic acid and disease. Exophthalmos caused by orbital fat and muscle swelling accounts for 30%-50% of the cases.

TAO is the most common surgical indications of orbital decompression. In addition to exophthalmos, clinical symptoms of Graves disease include epiphora, photophobia, diplopia and conjunctival hyperemia. Visual loss may occur in severe cases due to exposure keratitis and optic neuropathy. The development of Graves' eye disease is an independent process over thyroid disease, so the patient may still suffer from eye disease even when hyperthyroidism has been controlled.

Surgery remains as the important treatment method for TAO, and the appearance of surgical indications at any process of the disease, regardless of mild or severe, are evident. It can be divided into eyelid surgery, ocular surgery and orbital surgery according to the operation type.

Eyelid surgery is the correction of eyelid retraction, including Müller muscle resection, Müller muscle resection plus levator palpebrae superioris muscle resection, levator palpe-

brae superioris plus incision of M ller muscle edge, sclera transplantation and tarsorrhaphy. The surgery merely resolves the symptoms of eyelid retraction alone, not including the symptom of exophthalmos, so that the patient is not suitable for the operation.

Ocular muscle surgery is for ocular misalignment and diplopia caused by extraocular muscle lesions. Appearance of serious limitation of subduction and then difficulty in reading after inferior rectus muscle surgery is performed. The patient did not have ocular misalignment and diplopia, therefore the operation is not preferred.

In view of past experience, orbital decompression is found to be safe and effective. In the past century, a variety of surgical approaches are designed to reduce pressure of 1 4 orbits. This operation aims at reducing the orbital pressure and proptosis, relieving optic nerve compression. In the light of clinical manifestations and imaging data of the patient, we conducted the inferior orbital decompression. More attention was paid to the protective tissue of the inferior orbital vessels and nerves in order to reduce the incidence of com-

plications during the operation. Postoperative orbital CT examination was performed(see Figure 2).

### 3 Conclusions

The symptoms of proptosis and eyelid retraction progressively disappeared after the surgery. There is no recurrence or no significant decrease in visual acuity during 2 years of follow-up. What we gain from the discussion of the case is that the correct choice of treatment methods relies on a careful examination of the history, thorough preoperative examination, accurate diagnosis and correct analysis. We hope the clinician could raise their awareness of "thyroid associated eye disease", seize the characteristics of the disease, and accumulate experience in the treatment method in order to implement personalized treatment.<sup>[16]</sup>

### Conflicts of Interest Disclosure

The authors have no conflict of interest related to this article.

### References

- [1] Guoxiang Song, Zhongyao Wu. Orbital disease [M]. Beijing: People's Medical Publishing House, 1999: 342.
- [2] Dian Fu, Juan Liu, Jian Wang. Research progress of thyroid associated eye disease and self-antigen [J]. 2012, 18(9): 1374-1376.
- [3] Eckstein AK, Plicht M, Lax H, et al. Clinical results of anti-inflammatory therapy in Graves ophthalmopathy and association with thyroidal autoantibodies [J]. Clin Endocrinol, 2004, 61(5): 612-618.
- [4] Rose JG Jr, Burkat CN, Boxrud CA. Diagnosis and management of thyroid orbitopathy [J]. Otolaryngol Clin North Am, 2005, 38(5): 1043-1074.
- [5] Guihua Zhang, Ning Jing, Sheng De. Advances in the pathogenesis of thyroid associated eye disease [J]. Journal of Medical Review, 2007, 13(8): 612-14.
- [6] Vitti P, Raqo T, Chiovato L, et al. Clinical features of patients with Graves' disease undergoing remission after antithyroid drug treatment [J]. Thyroid, 1997, 7(3): 369-375.
- [7] Hongwen Zhang, Fengyuan Sun. Diagnosis and treatment of thyroid associated eye disease [J]. Chinese Journal of Coal Industry Medicine, 2005, 8(1): 4-5.
- [8] Jian Tang, Qingli Luo, Weimin He. Drug therapy of thyroid associated eye disease and timing of orbital decompression surgery [J]. West Chin Med J, 2005, 20(1): 2-3.
- [9] Shaomin Shi, Yebing He. A meta-analysis of somatostatin analogues in treatment of Graves ophthalmopathy [J]. Chinese Journal of Evidence-Based Medicine, 2013, 13(1): 106-111.
- [10] Cozma I, Zhang L, Uddin J M, et al. Modulation of expression of somatostatin receptor subtypes in Graves' ophthalmopathy orbits: relevance to novel analogues [J]. Am J Physiol Endocrinol Metab, 2007, 293(6): E1630-1635.
- [11] Tianjun Zhang. Diagnosis and treatment of Grave ophthalmopathy [J]. Chinese Journal of Endocrinology and Metabolism, 2000, 16(3): 196-197.
- [12] Antonelli A, Saracino A, Alberti B, et al. High-dose intravenous immunoglobulin treatment in Graves' ophthalmopathy [J]. Acta Endocrinol, 1992, 126(1): 13-23.
- [13] Likun Ai. Clinical treatment of thyroid associated eye disease [J]. Foreign Medical Sciences (Section of Ophthalmology), 2001, 25(5): 298-303.
- [14] Lin Yan, Li Hua, Wen Jiang. Effectiveness of radiation therapy combined with oral glucocorticoids in the treatment of thyroid associated eye disease [J]. Sichuan Medical Journal, 2012, 33(2): 225-227.
- [15] Bradley EA, Gower EW, Bradley DJ, et al. Orbital radiation for graves ophthalmopathy: a report by the American Academy of Ophthalmology [J]. Ophthalmology, 2008, 115(2): 398-409.
- [16] Shepard KG, Levin PS, Terris DJ. Balanced orbital decompression for Graves' ophthalmopathy[J]. Laryngoscope, 1998, 108(11 Pt 1): 1648-1653.