

ORIGINAL ARTICLES

Ameloblastoma: A clinical study of 25 Iraqi patients

Salwan Y. Bede*, Jamal A. Mohammed, Thair A. Hasan

Department of Oral and Maxillofacial Surgery, College of Dentistry, University of Baghdad, Iraq

Received: July 10, 2016

Accepted: August 12, 2016

Online Published: August 17, 2016

DOI: 10.5430/css.v2n4p25

URL: <http://dx.doi.org/10.5430/css.v2n4p25>

ABSTRACT

Objective: Geographic differences in clinical and pathological aspects of ameloblastoma have been suggested, therefore the purpose of this study was to analyze cases of ameloblastoma in terms of clinical and radiographic manifestations, histopathological types, treatment modalities and recurrence rate and compare them with reports from other parts of the world.

Methods: The medical reports of patients diagnosed with ameloblastoma were reviewed and the data concerning the age, gender, chief complaint, the anatomical site of the lesion, radiographic appearance, histopathological diagnosis, treatment approach and recurrence were retrieved. Surgical treatment consisted of either enucleation with curettage and peripheral ostectomy or resection; marginal or segmental. Statistical analysis included descriptive and inferential statistics.

Results: This study included 25 patients with a mean age of 39 years, 14 (56%) were males and 11 (44%) were females. Six patients (24%) were below 20 years when diagnosed. Nineteen patients (76%) had Solid Ameloblastoma, while the remaining 6 patients (24%) were diagnosed with Unicystic ameloblastoma, surgical treatment was provided for 23 patients, recurrence occurred in 2 patients (8.7%).

Conclusions: The main clinical characteristics of ameloblastoma in Iraq are in line with those reported in other studies from other parts of the world especially Asian countries, being mostly of solid variant, predominantly involving the mandibular posterior region, with no gender predilection or slight male preponderance but generally affecting younger age group.

Key Words: Ameloblastoma, Clinical study, Iraq

1. INTRODUCTION

Ameloblastoma is a slowly growing and locally invasive odontogenic tumor associated with high recurrence rate classified by the World Health Organization (WHO) as a benign odontogenic tumor of epithelial origin with mature, fibrous stroma without odontogenic ectomesenchyme.^[1-4] Although its origin is uncertain^[1] but theoretically the tumor may arise from epithelial rests of dental lamina, developing enamel organ, epithelial lining of odontogenic cysts or from the basal cells of oral mucosa.^[2] Historically it is believed that the tumor was described by Cusack in 1827 and detailed by Broca in 1868 and that Malassez was the first to coin the

term adamantinoma to this tumor in 1885, and he suggested that it originates from the epithelial remnants of a developing root sheath, while the term ameloblastoma was introduced by Churchill in 1934.^[3,5-7]

Clinically ameloblastoma accounts for about 1% of all cysts and tumors of the jaws and about 10%-58% of odontogenic tumors.^[3,5-8] The tumor affects all age groups but the peak incidence is in the third and the fourth decade of life, and mostly involving the mandibular molar ascending ramus region.^[2,9,10]

Ameloblastoma can be divided into 3 main subtypes namely; Solid or Multicystic ameloblastoma (SA) which is the most

***Correspondence:** Salwan Y. Bede, Asst. Prof.; Email: salwan.bede@gmail.com; Address: Department of Oral and Maxillofacial Surgery, College of Dentistry, University of Baghdad, Bab-Almoadham, Baghdad, Iraq.

common subtype, Cystic or Unicystic ameloblastoma (UA) which was first described in 1977 by Robinson and Martinez^[11] and studied in detail and classified into luminal, intraluminal and mural types by Ackermann et al. in 1988.^[12] The third subtype of ameloblastoma is the Peripheral or Extrasosseous ameloblastoma which is rare. These subtypes have different clinical manifestations and distinct treatment and prognostic considerations.^[2, 12, 13] Microscopically Ameloblastoma shows follicular or plexiform patterns and other less common patterns namely; acanthomatous, desmoplastic, granular and basal.^[5] SA is more aggressive with high recurrence potential than UA which usually responds to a less aggressive treatment.^[13, 14] Two malignant variants of ameloblastoma were distinguished by the WHO namely; malignant (or metastasizing) ameloblastoma which shows signs of metastasis, mostly to the lung while retaining the histological features of solid ameloblastoma, and ameloblastic carcinoma that shows histological features of malignant transformation like pleomorphism and mitosis.^[15]

Radiographically ameloblastoma appears as a radiolucent lesion of varying size either as a unilocular or multilocular, the latter is described as “soap bubble” appearance.^[6, 16]

Surgical treatment includes conservative approaches involving enucleation and curettage which is associated with high recurrence rates or more radical treatment approaches such as marginal and segmental resection of the affected jaw bones.^[1, 5]

Aims

Geographic differences in clinical and pathological aspects of ameloblastoma have been suggested.^[17] To the best of our knowledge, there are only few reports about ameloblastoma in Iraq, therefore the purpose of this study was to analyze cases of ameloblastoma in terms of the clinical and radiographic manifestations, histopathological types, treatment modalities and recurrence rate and compare them with reports from other parts of the world.

2. MATERIALS AND METHODS

The medical reports of patients who were diagnosed and treated for ameloblastoma at the Department of Oral and Maxillofacial surgery, College of Dentistry, University of Baghdad during the period extending from January 2009 to December 2015 were reviewed and the data concerning the age, gender, chief complaint, the anatomical site of the lesion, radiographic appearance, histopathological type, treatment approach and recurrence were retrieved. All the patients had at least 2 radiographs, mostly Orthopantomograph (OPG) and posteroanterior (PA) view of the mandible and in some patients CT scan was taken for better assessment of the ex-

tent of the lesions. Radiographically the lesions were either unilocular or multilocular radiolucency with or without root resorption.

2.1 Surgical treatment

Diagnosis was made by incisional biopsy of the lesions under local anesthesia and surgical treatment, after obtaining informed consent from the patients, consisted of either enucleation with curettage using curette and peripheral ostectomy by surgical handpiece and bur, this modality of treatment was reserved for UA. The other treatment modality was through resection of the tumor with about 1 cm of clinically and radiographically intact surrounding bone as a safe margin, resection was either marginal or segmental according to the extent of the lesion and was performed for cases of SA. Two patients who were diagnosed with SA refused to undergo mandibular resection and asked for more conservative procedure, for these patients enucleation with curettage and peripheral ostectomy was performed after informing them about the higher possibility of recurrence.

During the follow up, which was calculated from the date of the first treatment to the date of the last available assessment, the patients were examined clinically and radiographically for any recurrence, any suspicious lesion was biopsied under local anesthesia to confirm the presence of recurrence.

2.2 Statistics

Statistical analysis included descriptive and inferential statistics using Chi-square test and Student *T*-test for 2 independent means, the level of significance was set at $p < .05$.

3. RESULTS

3.1 Demographics and clinical manifestations

This retrospective study included 25 patients, 14 (56%) were males and 11 (44%) were females with a male: female ratio of 1.3:1, however, gender difference was statistically not significant at $p < .05$ ($\chi^2 = 0.36, p = .549$). The patients ranged in age from 12 to 75 years with a mean of 39 years. Six patients (24%) were below 20 when diagnosed (see Table 1).

Table 1. Distribution of the age groups

Age group	Number of patients (%)
10-19	6 (24)
20-29	2 (8)
30-39	4 (16)
40-49	4 (16)
50-59	3 (12)
60-69	4 (16)
70-79	2 (8)
Total	25 (100)

All the patients reported painless swelling as their chief complaints with variable durations ranging from 3 months to 9 years, in one patient there was a draining sinus expressing a yellowish fluid.

All the lesions were in the mandible, in 13 (52%) patients the left side of the mandible was involved whereas in 10 (40%) patients the right side was affected. In the remaining 2 (8%) patients the lesions affected the anterior mandible with tumors crossing the midline. Most of the cases involved the posterior mandibular region (see Table 2).

Table 2. Anatomical sites

Location	Number of patients (%)
Premolar-Molar region	9 (36)
Molar-Angle-Ramus region	9 (36)
Premolar-Molar-Angle-Ramus	5 (20)
Anterior crossing the midline	2 (8)
Total	25 (100)

3.2 Radiographic appearance

Radiographically the lesions appeared as multilocular radiolucency (see Figure 1) in 17 patients (68%) and as unilocular radiolucency (see Figure 2) in 8 (32%). Thirteen patients (52%) showed root resorption, and all the cases for which CT scan was available showed expansion of the buccal and lingual plates (see Figure 3).

3.3 Surgical treatment

Surgical treatment was carried out in 23 patients (92%) the remaining 2 patients were deemed unfit for major surgical operation by the anesthetist. The lesions were treated by enucleation with curettage and peripheral ostectomy in 8 patients (34.8%), 2 of whom had SA but declined resection. On the other hand resection was performed in 15 patients (65.2%) as shown in (see Figure 4).

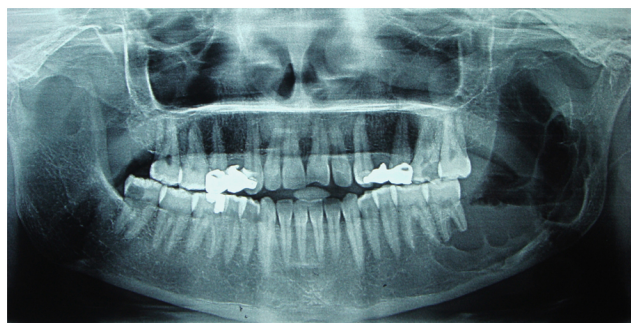


Figure 1. OPG of a 32 years old patient showing a multilocular radiolucency involving the molar-angle-ramus region of the left mandible with root resorption of the second molar

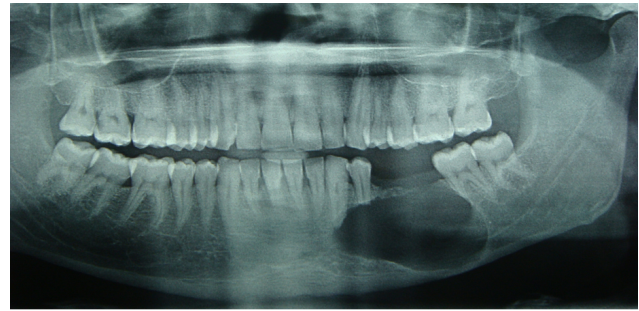


Figure 2. OPG of a 28 years old patient showing a unilocular radiolucency involving the premolar-molar region of the left mandible with root resorption of the first premolar and second molar

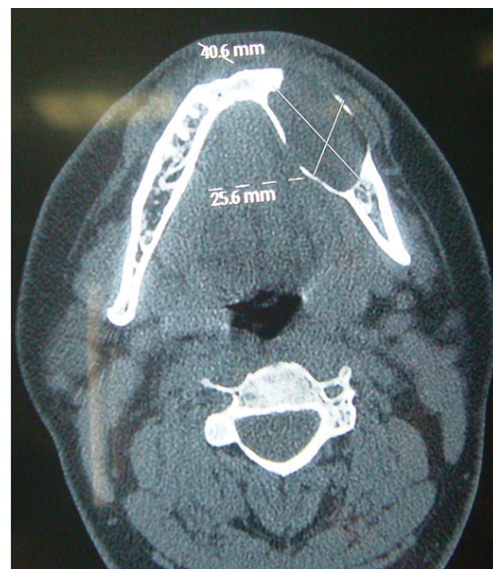

Figure 3. CT scan (axial section) showing buccal and lingual expansion of the mandible

3.4 Histopathology and follow up

Of all the 25 patients in this study, the histopathological examinations revealed SA in 19 patients (76%), 18 (94.7%) were of follicular type and one (5.3%) of plexiform type, while the remaining 6 patients (24%) were diagnosed with UA. The mean age of patients with SA was 42.6 years whereas that of patients diagnosed with UA was 29.7 years, but the difference was statistically not significant at $p < .05$ ($T = 1.314$, $p = .102$).

The follow up period ranged from 8 months to 6 years, during this period recurrence occurred in 2 patients (8.7%), both patients, in whom recurrences were evident and proved by biopsy, had SA treated by enucleation and curettage, in one of them the recurrence was treated by segmental resection of the lesion, while the other patient declined further treatment, therefore recurrence in treated SA was (11.8%) while no recurrence was detected in UA.

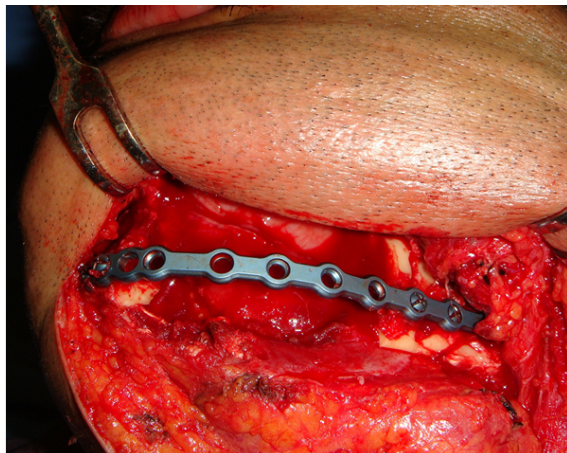


Figure 4. Intraoperative view of the same patient in Figure 2 showing segmental resection of the tumor with safe margin and temporary reconstruction with reconstruction plate

4. DISCUSSION

Ameloblastoma is the second most common odontogenic tumor of the jaw bones after odontoma,^[13] but its clinical significance comes from its characteristic high recurrence rate in addition to the slow and locally aggressive growth pattern which, if untreated, the tumor can grow to a massive or grotesque proportions as it is often the case in some African countries.^[18] Geographic differences in incidences and clinical manifestations are suggested in the literature.^[13, 17]

4.1 Comparison of demographics

The mean age in the current study (39 years) is almost identical with that reported by Small and Waldron^[19] in their review of 1.036 cases where they report an average age of 38.9 years. Another study from South Korea reported a mean age of 34.5 years.^[20] Reichart et al. in 1995 reported a higher mean age among Asians (41.2 years) followed in descending order by Caucasians (39.9 years) and Blacks (28.7 years).^[21]

In this study patients below 20 years of age were involved in (24%) of the cases, lower incidence rates of ameloblastoma in a similar age group have been reported in Asian studies; 13.9%,^[9] 18.2%^[22] and 19.7%.^[23] However one study from a neighboring country^[24] reported a higher incidence of ameloblastoma (38.5%) in patients below 21.

African studies, on the other hand, report incidences of ameloblastoma in patients 10-19 years of 17.1% in Zimbabwe,^[25] 21.3% in Kenya^[17] and 21.9% in Nigeria.^[26] Other studies also suggest that ameloblastoma in Africa occurs in younger age groups than that reported in European and American studies.^[13]

Equal gender distribution is reported^[17, 26] but the results of this study show slightly higher male preponderance, although

the gender difference was statistically not significant. A similar observation was made by other studies.^[7, 24, 27, 28] On the other hand female preponderance is also reported.^[5, 6]

4.2 Comparison of clinical presentations and radiographic features

The clinical presentation was a slowly growing painless swelling in all the patients; this is in keeping with other studies that reported painless swelling as the most common clinical manifestation.^[24, 27] Radiographically multilocular radiolucency was the most common appearance which is also observed in other studies,^[5, 6, 16, 27] root resorption was evident in more than half of the patients in the current study, other studies reported different percentages as low as 6.7% in one study^[27] and as high as 72% in another.^[16]

Apajalahti et al., in their review of imaging characteristics of 26 patients, state that the tendency of ameloblastoma to cause bony expansion and perforation and root resorption are significant aspects in the differential diagnosis emphasizing the superiority of CT scan over the conventional two-dimensional imaging modalities.^[16] In the current study over half of the patients showed root resorption and in all the patients, for whom CT scans were available, expansion of bone buccally and lingually was evident.

The results of this study show that the majority of the cases were diagnosed with SA, an observation that is evident in the literature.^[2, 5, 27] Most of the cases of SA, in this study, were of follicular type, other studies reported the predominance of follicular ameloblastoma,^[6, 17, 29] yet this finding is in contrast to Siar et al.^[27] and Fregnani et al.^[5] where plexiform type was evident in most of the cases.

With respect to the anatomical site, this study is in line with most reports in that the mandible is the most common jaw bone involved and that the posterior part of the mandible is most frequently reported site,^[5, 17, 24, 27] other studies,^[30] however, have reported that anterior mandible is the most common site of involvement; this observation has also been made in some African countries suggesting a geographic variation which is in contrast to reports from Asia and the west.^[6] Reichart et al.^[21] also reported that the anterior mandible is significantly more involved in Black than in White populations.

4.3 Treatment

Treatment of ameloblastoma entails two main approaches; the first is radical approach involving resection of the tumor with 1 cm – 1.5 cm of clinically and radiographically uninvolved bone, the second approach is more conservative and it consists of enucleation of the tumor with bone curettage.^[31] Although Carlson and Marx^[32] believed that the terms “rad-

ical” and “conservative” are inaccurate and they consider recommending conservative therapy for an aggressive tumor to be a paradox. Sampson and Pogrel^[33] criticized the term enucleation in treatment of ameloblastoma considering it as a confusing term. The first approach is usually reserved for treatment of SA^[1,14] while the UA is more amenable to conservative approach.^[20] Alternative therapeutic measures are also reported like enucleation with cryosurgery, enucleation and application of Carnoy’s solution as a means of chemical cauterization and surgical excision with peripheral ostectomy.^[34–37] Carnoy’s solution is a powerful fixative that penetrates the bone to more than 1.5 mm devitalizing remaining tumor cells and reducing recurrence rate.^[38] Lau and Samman, in their systematic review, reported a recurrence rate of 16% in cases of UA treated with enucleation followed by the application of Carnoy’s solution compared with 30.5% for the cases treated by enucleation only^[38] but concerns about the safety of the inferior alveolar nerve have been raised and a critical time of exposure of 2-3 minutes has been suggested.^[39] In this study Carnoy’s solution was not used in the treatment of UA which consisted of enucleation with thorough curettage and peripheral ostectomy using rotary instruments, this approach was also found to be effective in reducing recurrence rate.^[38]

In cases treated with resection the rule of including 1 cm – 1.5 cm of clinically and radiographically intact bone was followed regardless of the proximity to the inferior alveolar nerve especially in large lesions. Recent studies have confirmed the presence of perineural and intraneural involvement of the ameloblastoma with the nerve and recommended that the nerve should not be preserved in cases of advanced mandibular ameloblastoma.^[40]

Radiotherapy was also reported as a treatment modality of ameloblastoma especially as a salvage therapy.^[41,42]

4.4 Recurrence

This study shows a lower global recurrence rate than that reported by other studies,^[5,43] it also shows that recurrence occurred in SA treated conservatively by enucleation, Nakamura et al.^[44] reported recurrence of SA treated conservatively in 45% of the cases versus 10% recurrence for cases treated radically while conservative and radical treatment of UA showed recurrence in 14% and 0% respectively. Antonoglou and Sandor^[14] in a systematic review and meta-analysis of 229 cases reported a recurrence rate ranging 0.8%-38% in SA and 0.2%-12% in UA favoring radical treatment for SA. Conservative treatment was associated with higher recurrence rate in other studies.^[20,43] SA and UA are intraosseous tumors that have the potential for recurrence in

contrast to their extraosseous or peripheral counterpart which has a negligible recurrence rate.^[43] Recurrence is a major concern when treating ameloblastoma, some authors suggest that the term “persistence” is more accurate owing to the incomplete removal of the tumor.^[32] Most recurrence is reported to occur within 5 years after surgery, which is in line with this study since recurrences occurred within 2 years after surgery, but late recurrence as late as 33 years is also possible.^[21,43] The low recurrence rate, in the current study, can be attributed to the radical treatment approach adopted by the authors especially in patients diagnosed with SA, but given the relatively short follow up period the reported recurrence rate should only be considered cautiously due to the possibility of late recurrences.

Inadequacy of surgical treatment, the histopathological subtype and the tumor behavior are primary factors implicated in recurrence of ameloblastoma.^[13,20,27,43] Hong et al.,^[20] in their long term follow up of 305 cases, maintained that recurrence was more in follicular than in plexiform types which is in line with the results of our study yet in contrast with Siar et al.^[27] who showed that most recurrences occurred in plexiform growth pattern.

Soft tissue recurrences of ameloblastoma have been reported to occur even after radical treatment, Lin et al. in 2015^[45] attributed soft tissue recurrence to the aggressive behavior of the tumor and the insufficient resection of the adjacent soft tissues in the primary treatments and they also made the observation that half of the cases had multiple recurrences and that in most of the cases recurrence occurred after 10 years of the primary treatment recommending long-term follow up especially for aggressive tumors.

5. CONCLUSIONS

The results of this study need to be interpreted cautiously because of its main limitations of small sample size and short follow up period relative to other cited studies, nevertheless, they revealed that the main clinical characteristics of ameloblastoma in Iraq are in line with those reported in other studies from other parts of the world especially Asian countries, being mostly of solid variant, predominantly involving the mandibular posterior region, with no gender predilection or slight male preponderance but generally affecting younger age group, this study also showed that recurrence occurred in cases of SA treated conservatively by enucleation, curettage and peripheral ostectomy.

CONFLICTS OF INTEREST DISCLOSURE

The authors declare that they have no conflict of interests.

REFERENCES

- [1] Sammartino G, Zarrelli C, Urciuolo V, et al. Effectiveness of a new decisional algorithm in managing mandibular ameloblastomas: A 10-years experience. *Br J Oral Maxillofac Surg.* 2007; 45: 306-310. <http://dx.doi.org/10.1016/j.bjoms.2006.08.023>
- [2] Neville BW, Damm DD, Allen CM, et al. *Oral and Maxillofacial pathology.* 3rd ed. Elsevier Saunders; 2004. 702-711 p.
- [3] Kademani D, Junck DM. Contemporary treatment of Ameloblastoma. In: Bagheri SC, Bell RB, Khan HA, editors. *Current therapy in oral and maxillofacial surgery.* Elsevier Saunders; 2012. 384-390 p. <http://dx.doi.org/10.1016/b978-1-4160-2527-6.00049-9>
- [4] Barnes L, Eveson JW, Reichart P, et al. *World Health Organization Classification of Tumors. Pathology & genetics of the head and neck tumors.* Lyon: IARC Press; 2005. 283-327 p.
- [5] Fregnani ER, da Cruz Perez DE, de Almeida OP, et al. Clinicopathological study and treatment outcomes of 121 cases of ameloblastomas. *Int J Oral Maxillofac Surg.* 2010; 39: 145-149. <http://dx.doi.org/10.1016/j.ijom.2009.11.022>
- [6] Chukwunke FN, Anyanechib CE, Akpehc JO, et al. Clinical characteristics and presentation of ameloblastomas: an 8-year retrospective study of 240 cases in Eastern Nigeria. *Br J Oral Maxillofac Surg.* 2015. <http://dx.doi.org/10.1016/j.bjoms.2015.08.264>
- [7] França L, Curioni OA, Paiva DA, et al. Ameloblastoma demographic, clinical and treatment study - analysis of 40 cases. *Braz J Otorhinolaryngol.* 2012; 78(3): 38-41.
- [8] Almeida R de AC, Andrade ES de S, Barbalho JC, et al. Recurrence rate following treatment for primary multicystic ameloblastoma: systematic review and meta-analysis. *Int J Oral Maxillofac Surg.* 2016; 45(3): 359-67. <http://dx.doi.org/10.1016/j.ijom.2015.12.016>
- [9] Zhang J, Gu Z, Jiang L, et al. Ameloblastoma in children and adolescents. *Br J Oral Maxillofac Surg.* 2010; 48: 549-554. <http://dx.doi.org/10.1016/j.bjoms.2009.08.020>
- [10] Bansal S, Desai RS, Shirsat P, et al. The occurrence and pattern of ameloblastoma in children and adolescents: an Indian institutional study of 41 years and review of the literature. *Int J Oral Maxillofac Surg.* 2015; 44: 725-731. <http://dx.doi.org/10.1016/j.ijom.2015.01.002>
- [11] Robinson L, Martinez MG. Unicystic ameloblastoma: A prognostically distinct entity *Cancer.* 1977; 40: 2278-2285. [http://dx.doi.org/10.1002/1097-0142\(197711\)40:5<2278::AID-CNCR2820400539>3.0.CO;2-L](http://dx.doi.org/10.1002/1097-0142(197711)40:5<2278::AID-CNCR2820400539>3.0.CO;2-L)
- [12] Ackermann GL, Altini M, Shear M. The unicystic ameloblastoma: A clinicopathological study of 57 cases. *J Oral Pathol.* 1988; 17: 541-546. PMID: 3150441. <http://dx.doi.org/10.1111/j.1600-0714.1988.tb01331.x>
- [13] Pogrel MA, Montes DM. Is there a role for enucleation in the management of ameloblastoma? *Int J Oral Maxillofac Surg.* 2009; 38: 807-812. <http://dx.doi.org/10.1016/j.ijom.2009.02.018>
- [14] Antonoglou GN, Sandor GK. Recurrence rates of intraosseous ameloblastomas of the jaws: A systematic review of conservative versus aggressive treatment approaches and meta-analysis of non-randomized studies. *J Craniomaxillofac Surg.* 2015; 43: 149-157. <http://dx.doi.org/10.1016/j.jcms.2014.10.027>
- [15] Abdullah BH, Bede SYH, Ismael WK. Ameloblastic carcinoma of mandible: A case report. *J oral dent res (Baghdad).* 2014; 1(2): 13-16. Available from: <http://www.iaor.net/jor/index.htm>
- [16] Apajalahti S, Kelppe J, Kontio R, et al. Imaging characteristics of ameloblastomas and diagnostic value of computed tomography and magnetic resonance imaging in a series of 26 patients. *Oral Surg Oral Med Oral Pathol Oral Radiol.* 2015; 120: e118-e130. <http://dx.doi.org/10.1016/j.oooo.2015.05.002>
- [17] Butt FMA, Guthua SW, Awange DA, et al. The pattern and occurrence of ameloblastoma in adolescents treated at a university teaching hospital, in Kenya: A 13-year study. *J Craniomaxillofac Surg.* 2012; 40: e39-e45. <http://dx.doi.org/10.1016/j.jcms.2011.03.011>
- [18] Chukwunke FN, Ajuzieogu O, Chukwuka A, et al. Surgical challenges in the treatment of advanced cases of ameloblastoma in the developing world: The authors' experience. *Int J Oral Maxillofac Surg.* 2010; 39: 150-155. <http://dx.doi.org/10.1016/j.ijom.2009.11.023>
- [19] Small IA, Waldron CA. Ameloblastoma of the jaws. *Oral Surg Oral Med Oral Pathol Oral Radiol Endod.* 1955; 8: 281. [http://dx.doi.org/10.1016/0030-4220\(55\)90350-9](http://dx.doi.org/10.1016/0030-4220(55)90350-9)
- [20] Hong J, Yun PY, Chung IH, et al. Long-term follow up on recurrence of 305 ameloblastoma cases. *Int J Oral Maxillofac Surg.* 2007; 36: 283-288. <http://dx.doi.org/10.1016/j.ijom.2006.11.003>
- [21] Reichart PA, Phillipsen HP, Sonner S. Biological profile of 3677 cases. *Eur J Cancer B Oral Oncol.* 1995; 31B: 86-99. [http://dx.doi.org/10.1016/0964-1955\(94\)00037-5](http://dx.doi.org/10.1016/0964-1955(94)00037-5)
- [22] Ueno S, Nakamura S, Mushimoto K, et al. A clinicopathologic study of ameloblastoma. *J Oral Maxillofac Surg.* 1986; 44: 361-365. [http://dx.doi.org/10.1016/S0278-2391\(86\)80031-3](http://dx.doi.org/10.1016/S0278-2391(86)80031-3)
- [23] Sirichitara V, Dhiravarangkura P. Intrabony ameloblastoma of the jaws. An analysis of 147 Thai patients. 1984; 13(3): 187-193. [http://dx.doi.org/10.1016/S0300-9785\(84\)80002-2](http://dx.doi.org/10.1016/S0300-9785(84)80002-2)
- [24] Al-Khateeb T, Khansa T, Ababneh KT. Ameloblastoma in young Jordanians: a review of the clinicopathologic features and treatment of 10 cases. *J Oral Maxillofac Surg.* 2003; 61: 13-8. <http://dx.doi.org/10.1053/joms.2003.50002>
- [25] Chidzonga MM. Ameloblastoma in children. The Zimbabwean experience over 10 years. *Oral Surg Oral Med Oral Pathol Oral Radiol Endod.* 1996; 81: 168-170. [http://dx.doi.org/10.1016/S1079-2104\(96\)80408-2](http://dx.doi.org/10.1016/S1079-2104(96)80408-2)
- [26] Arotiba GT, Ladeinde AL, Arotiba JT, et al. Ameloblastoma in Nigerian children and adolescents: a review of 79 cases. *J Oral Maxillofac Surg.* 2005; 63: 747-51. <http://dx.doi.org/10.1016/j.joms.2004.04.037>
- [27] Siar CH, Lau SH, Ng KH. Ameloblastoma of the jaws: a retrospective analysis of 340 cases in a Malaysian population. *J Oral Maxillofac Surg.* 2012; 70: 608-15. <http://dx.doi.org/10.1016/j.joms.2011.02.039>
- [28] Gumgum S, Hosgoren B. Clinical and radiologic behavior of ameloblastoma in 4 cases. *J Can Dent Assoc.* 2005; 71: 481-4. PMID: 16026635.
- [29] Fulco GM, Nonaka CFW, de Souza LB, et al. Solid ameloblastomas - Retrospective clinical and histopathologic study of 54 cases. *Braz J Otorhinolaryngol.* 2010; 76(2): 172-7. PMID: 20549076. <http://dx.doi.org/10.1590/S1808-86942010000200005>
- [30] Adekeye EO. Ameloblastoma of the jaws: a survey of 109 Nigerian patients. *J Oral Surg.* 1980; 38: 36-41. PMID: 6985655.
- [31] Escande C, Chaîne A, Menard P, et al. A treatment algorithm for adult ameloblastomas according to the Pitie-Salpetriere Hospital experience. *J Craniomaxillofac Surg.* 2009; 37: 363-9. <http://dx.doi.org/10.1016/j.jcms.2009.05.001>
- [32] Carlson ER, Marx RE. The Ameloblastoma: Primary, Curative Surgical Management. *J Oral Maxillofac Surg.* 2006; 64: 484-94. <http://dx.doi.org/10.1016/j.joms.2005.11.032>
- [33] Sampson DE, Pogrel MA. Management of mandibular ameloblastoma: The clinical basis for a treatment algorithm. *J Oral Maxillofac Surg.* 1999; 57: 1074. [http://dx.doi.org/10.1016/S0278-2391\(99\)90328-2](http://dx.doi.org/10.1016/S0278-2391(99)90328-2)
- [34] Shi S, Liu Y, Shan Y, et al. Enucleation combined with peripheral ostectomy: Its role in the management of large cystic ameloblastoma.

- tomas of the mandible. *J Craniomaxillofac Surg*. 2014; 42: 1659-63. <http://dx.doi.org/10.1016/j.jcms.2014.05.009>
- [35] Carneiro JT, Couto APGR, Carreira ASD. Use of gas combination cryosurgery for treating ameloblastomas of the jaw. *J Craniomaxillofac Surg*. 2012; 40: e342-e345. <http://dx.doi.org/10.1016/j.jcms.2012.01.017>
- [36] Haq J, Siddiqui S, McGurk M. The use of Carnoy's solution following enucleation of ameloblastoma: ten year's experience. *Br J Oral Maxillofac Surg*. 2015; 53: e37-e110. <http://dx.doi.org/10.1016/j.bjoms.2015.08.057>
- [37] Sachs SA. Surgical Excision With Peripheral Osteotomy: A Definitive, Yet Conservative, Approach to the Surgical Management of Ameloblastoma. *J Oral Maxillofac Surg*. 2006; 64: 476-83. PMID: 16487812. <http://dx.doi.org/10.1016/j.joms.2005.12.001>
- [38] Lau SA, Samman N. Recurrence related to treatment modalities of unicystic ameloblastoma: A systematic review. *Int J Oral Maxillofac Surg*. 2006; 35: 681-690. <http://dx.doi.org/10.1016/j.ijom.2006.02.016>
- [39] Abdullah WA. Surgical treatment of keratocystic odontogenic tumors: A review article. *Saudi Dent J*. 2011; 23: 61-65. <http://dx.doi.org/10.1016/j.sdentj.2011.01.002>
- [40] Engelbrecht H, Meer S, Kourie JF. Perineural infiltration of the inferior alveolar nerve in mandibular ameloblastomas. *Br J Oral Maxillofac Surg*. 2013; 51(8): 757-761. PMID: 23473884. <http://dx.doi.org/10.1016/j.bjoms.2013.02.002>
- [41] Atkinson CH, Harwood AR, Cummings BJ. Ameloblastoma of the jaw. A reappraisal of the role of megavoltage irradiation. *Cancer*. 1984; 53: 869. [http://dx.doi.org/10.1002/1097-0142\(19840215\)53:4<869::AID-CNCR2820530409>3.0.CO;2-V](http://dx.doi.org/10.1002/1097-0142(19840215)53:4<869::AID-CNCR2820530409>3.0.CO;2-V)
- [42] Gardner DG. Radiotherapy in the treatment of ameloblastoma. *Int J Oral Maxillofac Surg*. 1988; 17: 201. [http://dx.doi.org/10.1016/S0901-5027\(88\)80033-X](http://dx.doi.org/10.1016/S0901-5027(88)80033-X)
- [43] Hammarfjord O, Roslund J, Abrahamsson P, et al. Surgical treatment of recurring ameloblastoma, are there options? *Br J Oral Maxillofac Surg*. 2013; 51: 762-6. <http://dx.doi.org/10.1016/j.bjoms.2013.08.013>
- [44] Nakamura N, Higuchi Y, Mitsuyasu T, et al. Comparison of long term results between different approaches to ameloblastoma. *Oral Surg Oral Med Oral Pathol Oral Radiol Endod*. 2002; 93: 13-20. PMID: 11805772. <http://dx.doi.org/10.1067/moe.2002.119517>
- [45] Lin Z, Sun G, Wang T, et al. Soft tissue recurrent ameloblastomas also show some malignant features: A clinicopathological study of a 15-year database. *Med Oral Patol Oral Cir Bucal*. 2015; 20(3): e365-371. <http://dx.doi.org/10.4317/medoral.20276>