

CASE REPORTS

Use of the Urchin[®] Heart Positioner facilitates insertion of the HeartWare[®] device for biventricular application

Sebastian G. Michel*, Christian Hagl, Gerd Juchem, Ralf Sodian

Department of Cardiac Surgery, Ludwig-Maximilians-University Munich, Germany

Received: November 1, 2015

Accepted: December 8, 2015

Online Published: December 14, 2015

DOI: 10.5430/css.v2n1p69

URL: <http://dx.doi.org/10.5430/css.v2n1p69>

ABSTRACT

Background: Ventricular assist devices (VAD) are a valuable treatment option in heart failure. During implantation, the correct positioning of the VAD within the ventricle is critical to avoid inflow restrictions caused by the septum or a papillary muscle. We report a novel technique using the Urchin[®] heart positioner to facilitate exposure of the right and left ventricular apex.

Case report: We used the Urchin[®] heart positioner, a suction device normally used for luxating the heart during off-pump coronary artery bypass grafting, for implantation of the HeartWare[®] ventricular assist device in a 75-year-old man.

Conclusions: Our technique facilitates insertion of apical cannulas, because the suction device holds the lumen of the ventricles open during the procedure.

Key Words: Ventricular assist device, Implantation, Off-pump, Suction device

1. INTRODUCTION

While mechanical circulatory support with left ventricular assist devices (LVAD) is a sufficient treatment in most cases of chronic heart failure, about 30% of these patients require some sort of support for the right ventricle as well.^[1]

The HeartWare[®] (Heart Ware Inc, Framingham, MA) ventricular assist device is a continuous non-pulsatile intrapericardial VAD that is used for chronic left ventricular support. For patients who require right sided support as well, we and others use two of these pumps in parallel: the LVAD is connected to the left ventricular apex and the ascending aorta, the right VAD (RVAD) to the right ventricular apex and the pulmonary artery.^[2-4] We report a novel technique to facilitate the insertion of the right and left ventricular HeartWare[®]

pumps.

2. CASE PRESENTATION

A 75-year-old male patient with end-stage ischemic cardiomyopathy and an LV-EF of 15% was referred to our center. After multiple myocardial infarctions there was no remaining option for coronary revascularization. As the right ventricular function was impaired as well with tricuspid regurgitation and severe pulmonary hypertension, the decision was made to implant a biventricular assist device consisting of two HeartWare[®] pumps. The patient was taken to the operating room, and standard cannulation for cardiopulmonary bypass was performed (right atrium, aorta). On pump beating heart, the sutures of the sewing ring for insertion of the RVAD and LVAD were placed after the heart was comfortably posi-

***Correspondence:** Sebastian G. Michel; Email: Sebastian.Michel@med.uni-muenchen.de; Address: Herzchirurgische Klinik, Klinikum der Universität München, Marchioninistrasse 15, 81377 München, Germany.

tioned using the Urchin[®] heart positioner (Medtronic Inc., Minneapolis, MN). Pulling at the silicone suction apparatus of the Urchin[®] (see Figure 1) ensures that the filling of both ventricles is not impaired and their lumen are held open, even when the heart is luxated. Care has to be taken not to compress the coronary vessels with the device. The vascular grafts for aorta and pulmonary artery were anastomosed end-to-side in a standard fashion. The patient recovered well from the procedure.

As shown in Figure 1, on pump beating heart, the sutures of the sewing ring for the right ventricular assist device were placed after the heart was comfortably positioned using the Urchin[®] heart positioner (Medtronic Inc., Minneapolis, MN) with its silicone suction apparatus. Perfect exposure for insertion of the right and left HeartWare[®] ventricular assist device is possible using this technique.

3. DISCUSSION

Avoiding suction phenomena caused by positioning the VAD inflow too close to the septum or papillary muscles is crucial for successful VAD implantation. Using the Urchin[®] suction device which was originally designed for off-pump coronary artery bypass grafting (CABG), facilitates a precise positioning of the VAD because the lumen of the ventricle is held open during the procedure, and the filling is not impaired. This technique may be helpful to make an already complex procedure in very sick patients a little simpler.

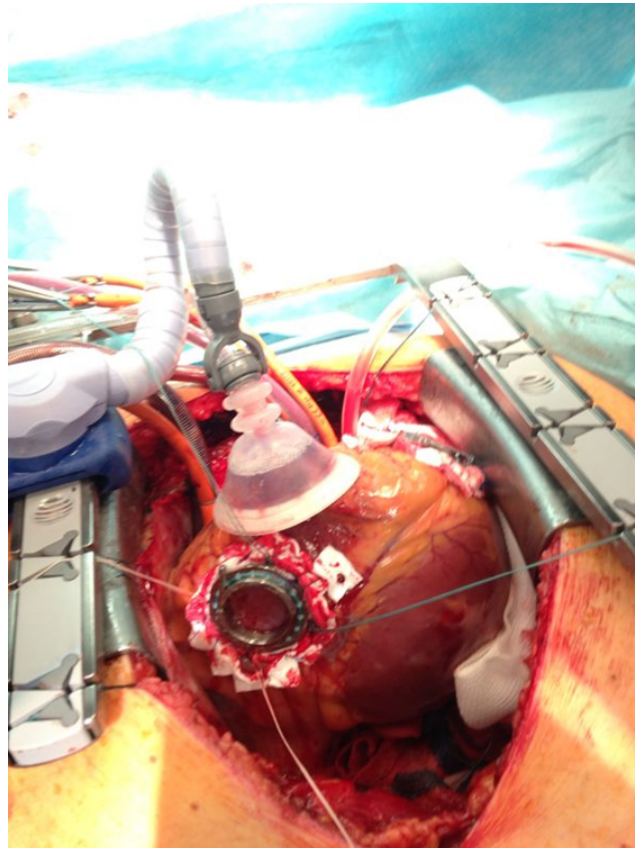


Figure 1. Urchin[®] suction device to facilitate exposure to insert LVAD and/or RVAD

REFERENCES

- [1] Potapov EV, Loforte A, Weng Y, *et al.* Experience with over 1000 implanted ventricular assist devices. *J Card Surg.* 2008; 23: 185-194. <http://dx.doi.org/10.1111/j.1540-8191.2008.00606.x>
- [2] Gregoric ID, Cohn WE, Frazier OH. Diaphragmatic implantation of the HeartWare ventricular assist device. *J Heart Lung Transplant.* 2011; 30: 467-470. <http://dx.doi.org/10.1016/j.healun.2010.11.014>
- [3] Hetzer R, Krabatsch T, Stepanenko A, *et al.* Long-term biventricular support with the HeartWare implantable continuous flow pump. *J Heart Lung Transplant.* 2010; 29: 822-824. <http://dx.doi.org/10.1016/j.healun.2010.02.012>
- [4] Strueber M, Meyer AL, Malehsa D, *et al.* Successful use of the HeartWare HVAD rotary blood pump for biventricular support. *J Thorac Cardiovasc Surg.* 2010; 140: 936-937. <http://dx.doi.org/10.1016/j.jtcvs.2010.04.007>