

## CASE REPORTS

# Nasal septal perforation: A possible local complication of topical adrenaline 1:1,000

Lilleen Minyi Huang\* Jin Keat Siow

Department of Otorhinolaryngology, Head and Neck Surgery, Tan Tock Seng Hospital, Singapore

**Received:** August 27, 2015

**Accepted:** October 11, 2015

**Online Published:** October 14, 2015

**DOI:** 10.5430/css.v2n1p41

**URL:** <http://dx.doi.org/10.5430/css.v2n1p41>

## ABSTRACT

**Background:** Topical adrenaline 1:1,000 is one of a variety of vasoconstrictors used in endoscopic sinus surgery. It is increasingly being used as a topical agent of choice for its very reliable efficacy. Studies have shown that systemic cardiopulmonary complications have been uncommon. There have been no reports of untoward local effects on nasal mucosa.

**Methods:** Two patients who underwent endoscopic sinus surgery developed post-operative nasal septal perforation following the use of topical adrenaline 1:1,000 soaked in surgical patties which were applied on both sides of the nasal septum for a period of approximately 20 minutes.

**Results:** Exposure of previously healthy nasal septal mucosa to topical adrenaline of high concentration 1:1,000 resulted in the post-operative development of slough and subsequent nasal septal perforation.

**Conclusions:** Topical adrenaline 1:1,000 should be used with great caution as a vasoconstrictor during endoscopic sinus surgery. Prolonged (20 minutes) and simultaneous contact with the nasal septal area should be avoided to prevent post-operative nasal septal perforation.

**Key Words:** Adrenaline, Epinephrine, Complications, Septal perforation, Endoscopic sinus surgery

## 1. INTRODUCTION

Topical vasoconstrictors have a very important role to reduce bleeding and to decongest local sino-nasal mucosa allowing for good visualization during endoscopic sinus surgery. Vasoconstrictors have a potential to cause systemic cardiopulmonary complications. However, the incidence of systemic cardiopulmonary complications is low as evidenced by studies using topical adrenaline 1:1,000 during endoscopic sinus surgery. Orlandi *et al.*<sup>[1]</sup> reviewed the safety of topical adrenaline 1:1,000 in 1998 cases of endoscopic sinus surgery. There were no reports of local nasal mucosal complications from the use of topical adrenaline 1:1,000 in this group of patients. However, two systemic complications were iden-

tified (0.1%). One patient developed coronary vasospasm and a second patient had intraoperative hypertension immediately after inadvertent sub-mucosal injection of the concentrated adrenaline. The study concluded that the use of topical adrenaline 1:1,000 is safe as long as appropriate safeguards are in place.

In this case report, we have identified two patients who developed septal perforations after routine functional endoscopic sinus surgery, in the absence of septal surgery and minimal intraoperative septal manipulation. We postulate that this local effect on nasal mucosa may be the result of mucosal ischemia arising from an approximate 20 minute bilateral and simultaneous exposure of the nasal septum to topical

\*Correspondence: Lilleen Minyi Huang; Email: [lilleenhuang@gmail.com](mailto:lilleenhuang@gmail.com); Address: Department of Otorhinolaryngology, Head and Neck Surgery, Tan Tock Seng Hospital, 11 Jalan Tan Tock Seng, 308433, Singapore.

adrenaline 1:1,000 soaked surgical patties.

These two patients did not develop any systemic complications from topical adrenaline 1:1,000 use.

**2. MATERIALS AND METHODS**

Between January and September 2014, in the course of post-operative follow up of our patients who had undergone endoscopic sinus surgery, we identified two patients who developed nasal septal perforations. Both had fairly prolonged (20 minutes) and simultaneous bilateral contact of their nasal septum with topical adrenaline 1:1,000 soaked surgical patties prior to endoscopic sinus surgery. We retrospectively reviewed their medical records and the factors leading to the development of this complication.

**3. RESULTS**

**3.1 Case 1**

The first patient was a 67-year-old lady who presented with persistent blocked nose and hyposmia secondary to chronic rhino sinusitis without nasal polyps. This was refractory to medical treatment with multiple courses of oral antibiotics, intranasal steroids and nasal douching for 2 years.

She had a history of hypertension, but this was well controlled and she was not on oral anti-hypertensives. She did not have any other cardiovascular risk factors, diabetes mellitus, and was a non-smoker.

She was not prescribed oral or topical nasal decongestants preoperatively.

Following induction of general anesthesia, both nasal cavities were first decongested with 2 sprays of co-phenylcaine and thereafter one 2 cm x 4 cm surgical patty (soaked in a mixture containing 3 ml of adrenaline 1:1,000 and 10 ml of 2% xylocaine gel) was placed on each side of the nasal cavity to induce further vasoconstriction. The surgical patties remained in the nasal cavity for about 20 minutes whilst the patient was cleaned and draped, and endoscopic and image guidance equipment set up and prepared. The surgical patties were then removed and placed into the infundibulum on both sides.

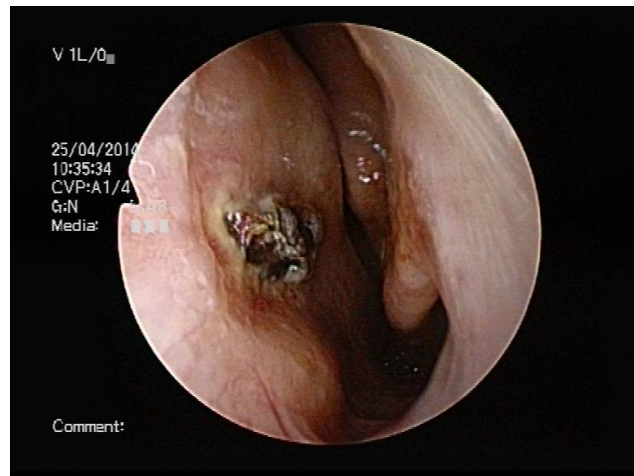
The surgical patties in the left infundibulum were removed and left endoscopic sinus surgery was performed in the usual fashion with prior infiltration of local anaesthetic containing 2% lignocaine and 1: 80,000 adrenaline to the lateral wall of the nose as is normally done during endoscopic sinus surgery. No infiltration of the nasal septum was performed.

On completion of the left side, surgical patties in the right infundibulum were removed and surgery was performed on the right side.

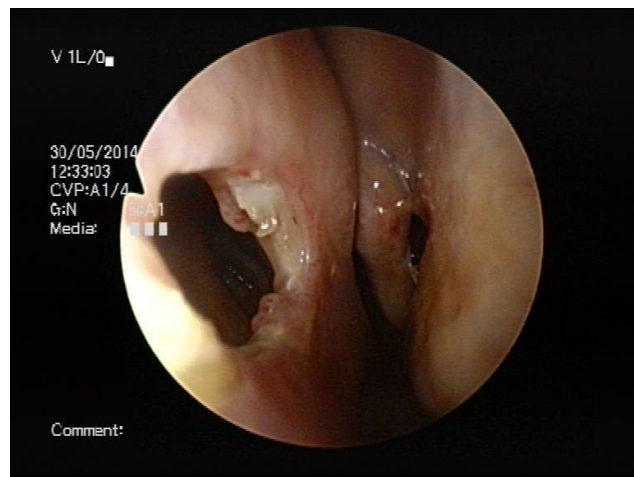
On completion of surgery, both middle meati were packed with a self-absorbing synthetic material soaked in triamcinolone solution. No septal surgery was performed. There was minimal manipulation of the septum, and there were no septal hematomas, mucosal or cartilage lacerations intraoperatively.

Total time for surgery was 2 hours and 35 minutes.

The patient started regular nasal douching with commercial preparation of sodium bicarbonate from postoperative day two.



**Figure 1.** Endoscopic view of left nasal cavity and crusting over the left anterior nasal septum at 9<sup>th</sup> post-operative day



**Figure 2.** Endoscopic view of left nasal cavity. Previous area of crusting has developed into a septal perforation at 10<sup>th</sup> post-operative week

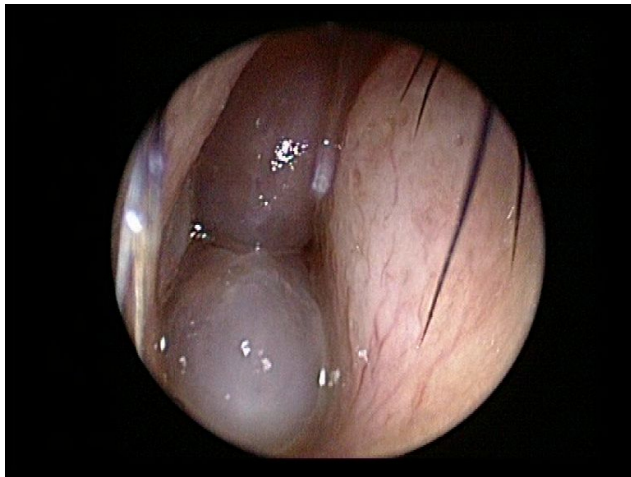
On the 9<sup>th</sup> post-operative day, moderate amounts of crusting and inflamed nasal mucosa were noted over the anterior aspects of both inferior turbinates and on both sides of the anterior caudal nasal septum although there had been no sep-

tal instrumentation throughout the surgery and in no part of the surgery had electrocautery been used or inadvertently applied to the septum (see Figure 1). At the 10<sup>th</sup> post-operative week, a septal perforation was noted at the anterior nasal septum (see Figure 2).

The patient reported an improvement in her nasal blockage and hyposmia with occasional post nasal drip. She did not report any symptoms consequent to the septal perforation.

### 3.2 Case 2

The second case was a 61-year-old gentleman who presented with persistent blocked nose due to bilateral grade III nasal polyps (see Figure 3). He was a healthy patient with no significant past medical history and was not on anti-hypertensives. He was also a non-smoker.



**Figure 3.** Pre-operative picture of the right nasal cavity showing Grade III nasal polyps and an intact healthy nasal septum

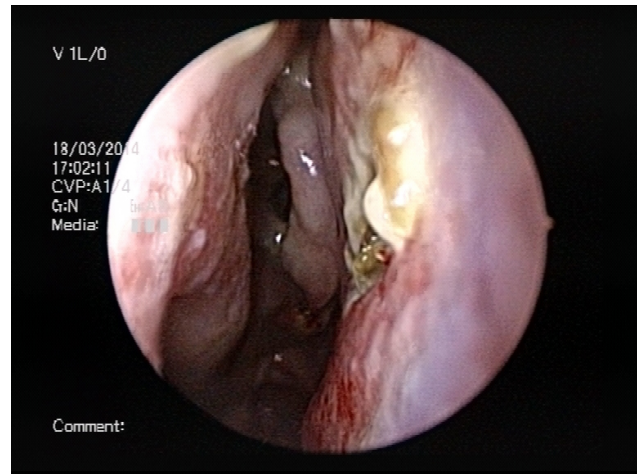
He was treated preoperatively with oral antibiotics, pulse prednisolone, intra-nasal steroids and saline nasal douching. He did not use any oral or topical nasal decongestants.

He underwent the same local decongestion protocol, endoscopic sinus surgery procedure, post-operative nasal dressing and douching as the patient in Case 1. Neither septal surgery nor injections of the nasal septum with vasoconstrictor were performed. There was minimal manipulation of the septum, and there were no septal hematomas, mucosal or cartilage lacerations intraoperatively.

Once again, the contact time of topical adrenaline 1:1,000 soaked surgical patties with the septal mucosa was estimated to be about 20 minutes.

Total time for surgery was 3 hours and 55 minutes.

During review at the third post-operative week, a moderate amount of crusting was noted to have formed over an area of the anterior nasal septum bilaterally, along with surrounding septal mucosal inflammation (see Figure 4).

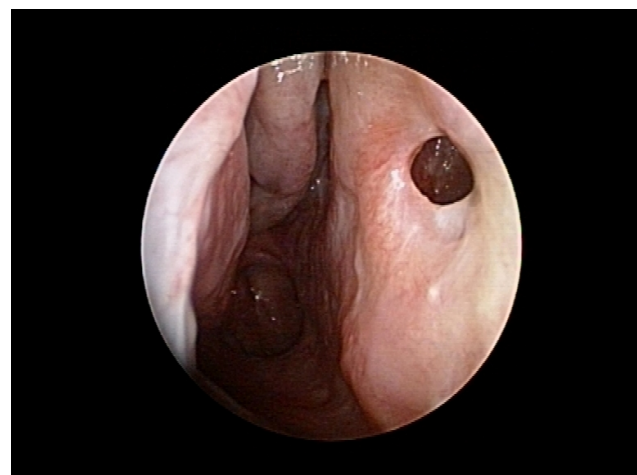

**Figure 4.** Endoscopic view of right nasal cavity showing area of crusting over anterior nasal septum at 3<sup>rd</sup> post-operative week

At 5 weeks post-surgery, a septal perforation developed over the area where the crusting had been noted (see Figure 5).

Over the next several weeks, the area of septal perforation remained stable and did not progress. The rest of the nasal mucosa remained healthy.

The patient reported resolution of his nasal blockage symptoms and did not complain of any symptoms consequent to the septal perforation.



**Figure 5.** Endoscopic view of right nasal cavity where previous area of crusting had evolved into a septal perforation at the 5<sup>th</sup> post-operative week

#### 4. DISCUSSION

Topical vasoconstrictors are routinely used in endoscopic sinus surgery. Surgical patties or pledgets soaked in vasoconstrictor agent are often placed in the nasal cavity upon induction of general anesthesia to promote vasoconstriction, shrink nasal mucosa, and provide a decongested field by the time draping and endoscopic equipment are set up. However, rare systemic cardiopulmonary complications can still occur with the use of topical vasoconstrictors, and Han *et al.*<sup>[2]</sup> proposed a protocol for the safe use of topical vasoconstrictor agents in endoscopic sinus surgery. These include avoiding the use of beta-blockers for intraoperative hypertension after topical vasoconstrictor use, avoidance of topical adrenaline in patients with history of cardiovascular disease, and judicious use of topical adrenaline 1:1,000 in patients 18 years or older.

Locally, topical adrenaline activates  $\alpha_1$ -receptors to contract smooth muscle cells in the arterioles of vascular beds like the skin, mucosa, kidney and veins.<sup>[3]</sup> It causes vasoconstriction, reducing mucosal edema and allowing tissue decongestion. This facilitates visualization and reduces bleeding during sinus surgery.

The two cases presented had undergone routine functional endoscopic sinus surgery, where topical adrenaline 1:1,000 is commonly used for intraoperative nasal decongestion. There was no septal surgery performed in both cases, no inadvertent septal instrumentation intraoperatively nor any application of electrocautery to the septum. We could not identify any significant risk factors for ischemia which could have contributed to tissue necrosis. One patient had well-controlled hypertension and no other cardiovascular risk factors, while the second patient was healthy with no previous medical history. Both were non-smokers and both had no previous history of nasal surgery. Both patients also did not have significant risk factors for poor wound healing such as diabetes mellitus, collagen vascular disease, renal and hepatic disease, and were not on any immunosuppressive agents or systemic steroids which would otherwise impede normal wound healing. In the absence of such iatrogenic or significant cardiovascular risk factors, we therefore postulate that the exposure of nasal septal mucosa to topical adrenaline of 1:1,000 concentration for a prolonged period of approximately 20 minutes could have caused a degree of vasoconstriction sufficient to cause mucosal ischemia and necrosis, resulting in unhealthy, inflamed nasal mucosa and inadvertent septal perforation post-operatively.

We also noticed that the septal perforations in both patients were located in the anterior septum. The other parts of nasal mucosa which were initially covered with slough, notably the anterior ends of both inferior turbinates in Case 1, eventually

healed.

The length of time that the topical adrenaline 1:1,000 soaked surgical patties were in contact with nasal septal mucosa both bilaterally and simultaneously was approximately 20 minutes in both patients. This protocol of placing nasal patties with vasoconstrictor agents other than topical adrenaline 1:1,000 (*e.g.* co-phenylcaine, diluted adrenaline 1: 10,000, cocaine) following induction just before surgery had been in place in our department for several years without any cases of post-operative nasal septal perforation being encountered.

There is a paucity of literature reporting any adverse local nasal mucosal complications from the use of topical adrenaline 1:1,000 in endoscopic sinus surgery. Perhaps unrelated but similarly, necrotizing metaplasia or anesthetic necrotic ulcers of the palatal mucosa have been reported following administration of local anaesthetics containing vasoconstrictors such as adrenaline.<sup>[4,5]</sup> In these cases, although the exact mechanisms remain unclear, it has been postulated that vasoconstrictors in the local anaesthetic solutions reduce oxygen supply to vasculature of minor salivary gland lobules of the palate mucosa, possibly causing tissue ischemia and secondary necrosis with resultant ulcer formation. For both our cases, in the absence of septal surgery, minimal septal manipulation and absence of any septal tears or injury intraoperatively, we infer that the development of post-operative nasal septal perforations in both patients may be a consequence of concentrated topical adrenaline (1:1,000) which were placed on both sides of the nasal septum for approximately 20 minutes. As both patients were in their sixties, it is possible that their vessels were more arteriosclerotic and thus more susceptible to iatrogenic ischemia from this period of contact of septal mucosa with the topical adrenaline.

#### 5. CONCLUSIONS

Topical adrenaline at 1:1,000 concentration remains the topical vasoconstrictor agent of choice for our endoscopic sinus surgery procedures. At this point, it is difficult to establish a causal relationship between topical adrenaline 1:1,000 and development of local nasal mucosal complications as a result of its use, and future evidence-based assessments would be required. However, this report is made to advise caution in its use in bilateral simultaneous contact with the septal mucosa prior to or during endoscopic sinus surgery. It should best be applied directly into the infundibulum and prolonged contact (20 minutes) with the anterior nasal septum should be avoided as much as possible.

#### ACKNOWLEDGEMENTS

No financial or material support.

#### CONFLICTS OF INTEREST DISCLOSURE

No potential conflicts.

## REFERENCES

- [1] Orlandi RR, Warriar S, Sato S, *et al.* Concentrated topical epinephrine is safe in endoscopic sinus surgery. *Am J Rhinol Allergy*. 2010 Mar-Apr; 24(2): 140-2. PMID: 20338114. <http://dx.doi.org/10.2500/ajra.2010.24.3454>
- [2] Higgins TS, Hwang PH, Kingdom TT, *et al.* Systematic Review of Topical Vasoconstrictors in Endoscopic Sinus Surgery. *Laryngoscope*. 2011 Feb; 121(2): 422-32. PMID: 21271600. <http://dx.doi.org/10.1002/lary.21286>
- [3] Brody TM, Lerner J, Minneman KP, *et al.* *Human Pharmacology: molecular to clinical*. St Louis: Mosby; 1994. 124.
- [4] Imbery TA, Edwards PA. Necrotizing Sialometaplasia: literature review and case reports. *J Am Dent Assoc*. 1996 Jul; 127(7): 1087-92. PMID: 8754467. <http://dx.doi.org/10.14219/jada.archive.1996.0334>
- [5] Ranjitha EG, Ramasamy, Austin RD, *et al.* Necrotic Ulcer on the Palate: As a Sequelae of Local Anaesthetic Administration: A Rare Case Report. *Int J Adv Health Sci*. 2015; 2(2): 10-13.