

## CASE REPORTS

# Ganglioneuroblastoma in an adult patient

Nicholaus Monsma<sup>1</sup>, G. Paul Wright\*<sup>1,2,3</sup>, Mathew H. Chung<sup>1,2,3</sup>

<sup>1</sup>Michigan State University College of Human Medicine, Department of Surgery, Grand Rapids, Michigan, United States

<sup>2</sup>Grand Rapids Medical Education Partners/Michigan State University General Surgery Residency Program, Grand Rapids, Michigan, United States

<sup>3</sup>Spectrum Health Medical Group, Division of Surgical Specialties, Grand Rapids, Michigan, United States

**Received:** July 1, 2015

**Accepted:** July 26, 2015

**Online Published:** August 9, 2015

**DOI:** 10.5430/css.v1n1p29

**URL:** <http://dx.doi.org/10.5430/css.v1n1p29>

## ABSTRACT

Neuroblastoma (NB) is a common tumor in children but is extremely rare in adults. Sparse literature exists on adult NB or the subtype ganglioneuroblastoma (GNB). We present a 40-year-old male complaining of decreased strength and pain in his left hand. Imaging studies showed a paraspinal tumor at T1 and an abdominal mass while laboratory tests were significant for high plasma and urine metanephrines suggesting a diagnosis of pheochromocytoma. Percutaneous core needle biopsy was performed and a diagnosis of GNB was made based on immunohistochemical staining. The patient underwent debulking surgery and final pathology confirmed the diagnosis. The patient demonstrates no signs of local recurrence but developed diffuse bony metastasis after the debulking procedure. Systemic therapy regimens for GNB are largely extrapolated from pediatric regimens and efficacy is unknown. Differentiation between adult and pediatric NB remains unclear.

**Key Words:** Neuroblastoma, Ganglioneuroblastoma, Pheochromocytoma

## 1. INTRODUCTION

Neuroblastoma (NB) is a common embryological tumor in children arising from neural crest cells. It comprises about 8% of all pediatric cancers and accounts for approximately 15% of all cancer deaths in patients under the age of 15.<sup>[1-3]</sup> However, it is rare in adults and therefore most research and literature pertains to NB in children. There is a limited number of cases of NB reported in adults.<sup>[4]</sup> Of those reports, even fewer relate to the subtype ganglioneuroblastoma (GNB). In this report, we present a rare case of adult GNB.

## 2. CASE PRESENTATION

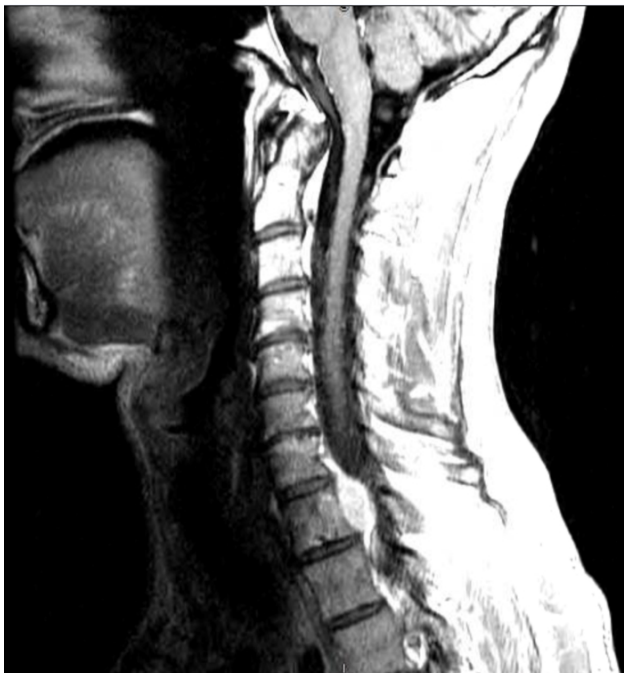A 40-year-old male patient presented with decreased strength and pain in his left hand. The patient exhibited no other comorbid conditions. He was a former smoker with a reported 4 pack-year history but had quit one year prior to presenta-

tion. He also reported consuming 10-12 alcohol drinks per week. On physical exam he was a thin appearing male with body mass index of 21.6. Abdominal exam demonstrated fullness on the left side with no discrete tumor palpated. Neurologic examination showed 3+/5 strength in the left hand when compared with the contralateral side. MRI of the cervical spine revealed a paraspinal tumor at T1 (see Figure 1). A CT of the abdomen was obtained and revealed a large left sided abdominal mass appearing to arise from the left adrenal gland (see Figure 2). A 2 cm mass was also seen in the superior half of the right lobe of the liver along with several tiny low-attenuation lesions. It was deduced that some of the lesions represented cysts. Initial differential diagnosis included adrenocortical carcinoma, exophytic left renal cell carcinoma, or gastrointestinal stromal tumor arising from the bowel with metastasis to the liver and left aspect of the spinal

\*Correspondence: G. Paul Wright; Email: [Paul.Wright@grmep.com](mailto:Paul.Wright@grmep.com); Address: 221 Michigan St, Ste 200A, Grand Rapids, Michigan, United States.

canal at T1.

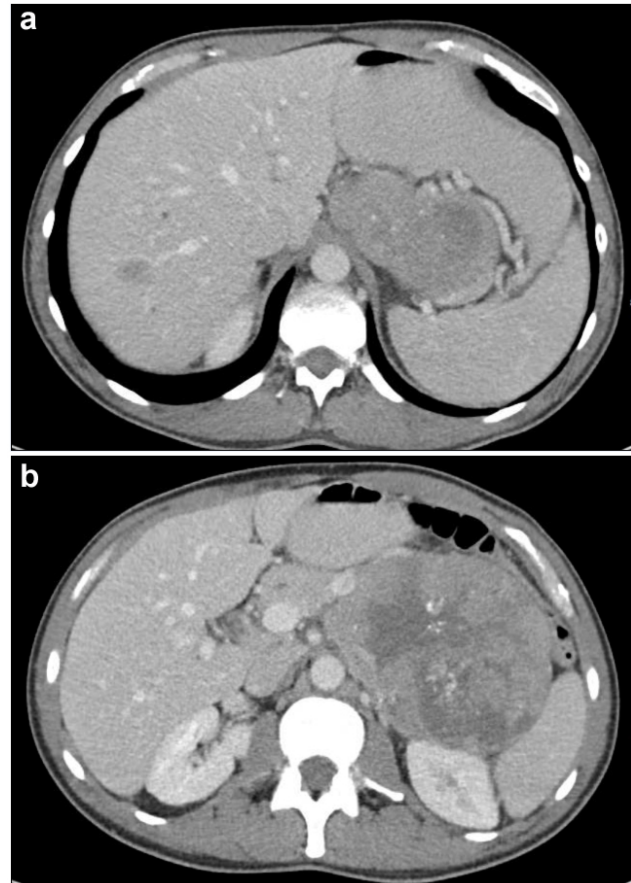
Workup was initiated with plasma and urine metanephrine studies. The plasma normetanephrine levels was 1.9 nmol/L (normal range: < 0.20) while the 24 hour urine total metanephrines level was 1349 mcg/24 hrs (normal range: 200-614) These elevated tests in the face of an abdominal mass raised concern for pheochromocytoma. An I-123 metaiodobenzylguanidine (MIBG) scan was performed and showed intense radiotracer uptake by the abdominal mass and a focus of radiotracer uptake was seen in the posterior right lobe of the liver as seen in Figure 3. Additional abnormal foci of increased uptake were seen throughout the musculoskeletal system, including posterior to the right transverse process of T3, within the right T8 vertebral body, right ilium, left ilium, sacrum, right gluteus muscles, and right superior pubic ramus. There were additional foci within the spinal canal, most intense at the L4 level. Other foci in the spinal canal were seen at the T1 level, and right S1-2 neural foramen. A focus within the anterior myocardium, or pericardium, was in the area of the right ventricular outflow track. These areas of MIBG-avidity were all thought to be consistent with metastatic disease.



**Figure 1.** Sagittal view of cervical spine MRI demonstrating a paraspinal tumor at the level of the T1 vertebral body

A percutaneous core-needle biopsy of the abdominal mass was obtained. The specimen contained a small round blue cell tumor with focal necrosis. Scattered throughout the tumor were large ganglion-like cells with granular cytoplasm, large nuclei, and large nucleoli. Collections of cells

formed pseudorosettes with neurophil-like material in the background. Immunohistochemical staining was performed and revealed the tumor cells were positive for chromogranin, synaptophysin and CD 56, and negative for pax-8, myogenin, CD 99, WT-1, CD 45, S-100, desmin, and pancytokeratin. It was determined from these findings that the tumor represented a GNB.

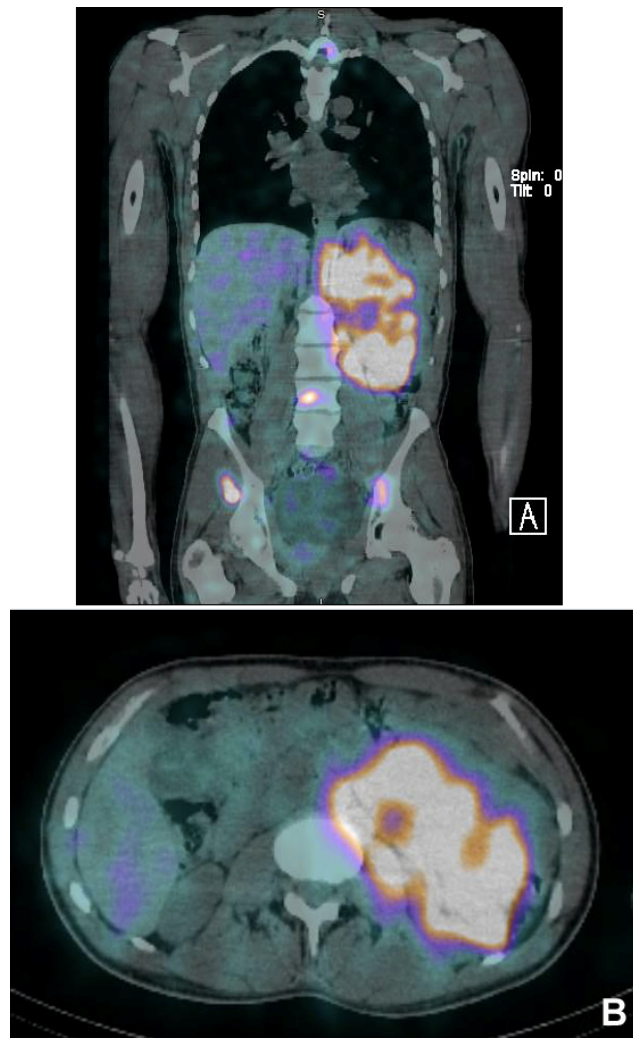


**Figure 2.** CT scan of the abdomen demonstrating (a) the small liver metastasis and superior portion of large adrenal mass and (b) the large adrenal mass with central necrosis at its largest point

Debulking surgery was performed which included resection of the large abdominal tumor and unilateral nephrectomy. During the surgery, the hepatic metastasis was treated with radiofrequency ablation. Following surgery, the patient underwent stereotactic body radiation therapy for the lesion in the spine. The patient was also started on zoledronic acid to treat the bony metastases.

There was no evidence of recurrent disease in the liver or peritoneum at interval three-month postoperative evaluation. However, the patient demonstrated rapidly progressive diffuse bony disease due to the non-efficacy of zoledronic acid.

This has led to a switch to denosumab. Additionally, systemic chemotherapy with topotecan and cyclophosphamide was initiated. At six-month follow-up his disease has demonstrated mild improvement with decreased FDG uptake on PET scan and no new symptoms. He is scheduled to undergo therapeutic MIBG treatment and following this will be started on ALK-inhibitor targeted therapy with crizotinib.



**Figure 3.** I-123 metaiodobenzylguanidine scan demonstrating increased uptake within tumor on (A) coronal and (B) axial views

### 3. DISCUSSION

Neuroblastic tumors arise from the neural crest cells that are designated to become sympathetic nervous tissue and therefore can arise anywhere in the body where sympathetic nervous tissue exists.<sup>[1,3]</sup> NB and GNB are often grouped together because both possess malignant potential.<sup>[3]</sup> NB is a tumor composed of immature undifferentiated neuroblasts while GNBs are comprised of both mature and immature

cells. The malignant potential of these tumors typically matches the degree of immature cells.<sup>[3,5]</sup> There may be survival differences between NB and GNB though in most reports these are grouped together as a single entity.

NB is predominantly a disease of infants and children. Ninety percent of children with NB/GNB are diagnosed before the age of 5 years.<sup>[6-8]</sup> Adult NB is exceedingly rare as less than five cases per year have been reported over 30 years of the U.S. National Cancer Institute's Surveillance, Epidemiology, and End Results (SEER) Program.<sup>[9]</sup> Additionally, fewer than 50 cases of GNB have been reported.<sup>[10,11]</sup>

The most common locations of NB include the adrenal medulla, extra-adrenal retroperitoneum, and less commonly in the neck and pelvis.<sup>[3,6]</sup> The associated symptoms vary depending on the location and tumor burden. If localized, NB typically presents with pain or distention, however it may be asymptomatic.<sup>[3,6]</sup> Patients with widespread disease typically present with malaise, fever, irritability, weight loss, shortness of breath, or peripheral neurologic deficit.<sup>[3,6]</sup> In this case, the patient was asymptomatic in relation to his abdominal mass. However, the patient did experience symptoms of pain and weakness in the left hand likely due to compression of the T1 spinal nerve leading to dysfunction in the median and/or ulnar nerve.

Typical diagnosis may be suspected with urinary catecholamine and radiological images, but is usually confirmed by histological and immunological results.<sup>[4]</sup> Most NBs secrete catecholamines in the form of vanillylmandelic acid (VMA) and homovanillic acid (HVA).<sup>[3]</sup> Since 90 percent of patients have MIBG-avid disease, radioiodine-labeled MIBG is used to pinpoint primary tumors and metastatic sites in order to help stage the neuroblastoma.<sup>[6]</sup> These laboratory and imaging findings are similar to those seen in pheochromocytoma, a more common malignancy in adults.

Immunological and histological results for NB include staining positive for chromogranin A, synaptophysin, neuron-specific enolase (NSE), CD 56 and neurofilament. NBs often show a fibrillar background resembling neutrophils. GNBs are composed predominantly of neoplastic ganglion cells. Pheochromocytoma stains for Chromogranin A, Synaptophysin, NSE, S100, cytokeratin 8, protein gene product (PGP) 9.5. Typical histological findings include hypercellular specimens with loose groups or single cells with binucleated and multinucleated cells.<sup>[12]</sup>

Prognosis estimation follows pediatric protocols which dictate that patients are stratified into levels of risks that are either high, intermediate or low.<sup>[6,15]</sup> These levels of risk are significant in determining prognosis. Risk group is determined by

factors such as age of patient, stage of disease, and biological factors such as MYCN gene amplification.<sup>[6,13]</sup> Histology can also be classified favorable or unfavorable according to the International Neuroblastoma Pathologic Committee Classification.<sup>[13]</sup> However, growing research states risk assessment for adults may be different because adult NB differs in certain biological factors such as having a lower incidence of MYCN amplification and catecholamine secretion.<sup>[14]</sup> It also becomes harder to detect or stage the NB due to the fact that MIBG is less useful as age increases.<sup>[4,14]</sup>

Since little research has been done on adult NB, no standardized method of treatment has been formulated and pediatric protocols are typically followed.<sup>[4,13,15]</sup> In children, multidisciplinary treatment has been the standard of care and includes surgical resection, chemotherapy, radiation, and stem cell transplantation dependent on the stage of disease.<sup>[6,12]</sup> Chemotherapy regimens typically include cisplatin and etoposide, alternating with vincristine, cyclophosphamide, and doxorubicin.<sup>[16]</sup> Adult regimens have been similar with additional reported success with agents include topotecan, bleomycin, and ifosfamide.<sup>[17-22]</sup> Although adults are reported to have significantly worse survival rates than children, this may be related to a more advanced stage of disease at diagnosis. When matched for stage and other prognostic factors, recent reports suggest the prognosis for adult and pediatric patients may be similar.<sup>[17]</sup> New research in treatment of NB include targeting the MYC protein.<sup>[6,14]</sup>

Anti-GD3 immunoglobulins, I-131-labeled MIBG or ALK-inhibition molecules are all currently under investigation and may prove useful in the future treatment of NB patients.<sup>[23]</sup> The reported 5-year survival of adult NB is 36%.

In the reported case, the patient was symptomatic primarily from the T1 lesion. However, given the size and degree of metastasis it was felt he would soon display symptoms of his abdominal disease due to compression of adjacent structures. While the elective debulking procedure has been thus far successful for local control on short-term follow-up, diffuse bony metastases occurred. The treatment for the bony metastasis has been changed from zoledronic acid to denosumab, a receptor activator of nuclear factor kappa-B ligand inhibitor. With stable/improved disease he will now undergo therapeutic MIBG treatment followed by use of a newer targeted therapy, crizotinib, which is an ALK-inhibitor. Stem cell harvest has also been accomplished for future use in rescue therapy if the need arises.

#### 4. CONCLUSION

Adult GNB is extremely rare but should be considered particularly in patients with findings suggestive of pheochromocytoma without the classically associated symptoms. Treatment for these rare tumors is largely based on pediatric protocols that demonstrate low rates of efficacy in the adult population. Further focus on individualized therapy may be warranted in these cases.

#### REFERENCES

- [1] Davidoff AM. Neuroblastoma. *Semin in Pediatr Surg.* 2012; 21(1): 2-14. PMID: 22248965. <http://dx.doi.org/10.1053/j.sempedsurg.2011.10.009>
- [2] Franks LM, Bollen A, Seeger RC, *et al.* Neuroblastoma in adults and adolescents: An indolent course with poor survival. *Cancer.* 1997; 79(10): 2028-2035. [http://dx.doi.org/10.1002/\(SICI\)1097-0142\(19970515\)79:10<2028::AID-CNCR26>3.0.CO;2-V](http://dx.doi.org/10.1002/(SICI)1097-0142(19970515)79:10<2028::AID-CNCR26>3.0.CO;2-V)
- [3] Lonergan GJ, Schwab CM, Suarez ES, *et al.* Neuroblastoma, ganglioneuroblastoma, and ganglioneuroma: radiologic-pathologic correlation. *Radiographics.* 2002; 22(4): 911-934. PMID: 12110723. <http://dx.doi.org/10.1148/radiographics.22.4.g02j115911>
- [4] Jrebi NY, Iqbal CW, Joliat G, *et al.* Review of our experience with neuroblastoma and ganglioneuroblastoma in adults. *World J Surg.* 2014; 38: 2871-2874. PMID: 25002244. <http://dx.doi.org/10.1007/s00268-014-2682-0>
- [5] Jiang M, Stanke J, Lahti JM. The connections between neural crest development and neuroblastoma. In: *Current topics in developmental biology.* Vol 94. Elsevier Science & Technology; 2011: 77-127. <http://dx.doi.org/10.1016/b978-0-12-380916-2.00004-8>
- [6] Irwin MS, Park JR. Neuroblastoma: Paradigm for Precision Medicine. *Pediatr Clin North Am.* 2015; 62(1): 225-256. PMID: 25435121. <http://dx.doi.org/10.1016/j.pcl.2014.09.015>
- [7] Maris JM, Hogarty MD, Bagatell R, *et al.* Neuroblastoma. *Lancet.* 2007; 369(9579): 2106-2120. [http://dx.doi.org/10.1016/S0140-6736\(07\)60983-0](http://dx.doi.org/10.1016/S0140-6736(07)60983-0)
- [8] Brodeur GM. Neuroblastoma: Biological insights into a clinical enigma. *Nat Rev Cancer.* 2003; 3(3): 203-216. PMID: 12612655. <http://dx.doi.org/10.1038/nrc1014>
- [9] Esiashvili N, Goodman M, Ward K, *et al.* Neuroblastoma in adults: Incidence and survival analysis based on SEER data. *Pediatr Blood Cancer.* 2007; 49(1): 41-46. PMID: 16628557. <http://dx.doi.org/10.1002/pbc.20859>
- [10] Bhanvadia V, Desai N, Sheikh S, *et al.* Retroperitoneal nodular ganglioneuroblastoma in adult: An unusual case report. *Clin Cancer Invest J.* 2014; 3(3): 251. <http://dx.doi.org/10.4103/2278-0513.132124>
- [11] Ohtaki Y, Ishii G, Hasegawa T, *et al.* Adult neuroblastoma arising in the superior mediastinum. *Interact Cardiovasc Thorac Surg.* 2011; 13(2): 220-222. PMID: 21388984. <http://dx.doi.org/10.1510/icvts.2010.262204>
- [12] Sidawy MK, Ali SZ (eds). *Mediastinum. Fine needle aspiration cytology.* Philadelphia: Churchill Livingstone Elsevier; 2007. 201-219.
- [13] National Cancer Institute: PDQ® Neuroblastoma Treatment. Bethesda, MD: National Cancer Institute. Date last modified: December 15, 2014. Available at: <http://cancer.gov/cancertop>

- ics/pdq/treatment/neuroblastoma/HealthProfessional. Accessed January 1, 2015.
- [14] Smith L, Minter S, O'Brien P, *et al.* Neuroblastoma in an adult: case presentation and literature review. *Ann Clin Lab Sci.* 2013; 43(1): 81-84. PMID: 23462610.
- [15] Majed Al-Mourgi. Adult neuroblastoma: A case report. *EJHM.* 2014; 54: 36-40. <http://dx.doi.org/10.12816/0002429>
- [16] Kushner BH, LaQuaglia MP, Bonilla MA, *et al.* Highly effective induction therapy for stage 4 neuroblastoma in children over 1 year of age. *J Clin Oncol.* 1994; 12(12): 2607-2613. PMID: 7527454.
- [17] Conter HJ, Gopalakrishnan V, Ravi V, *et al.* Adult versus pediatric neuroblastoma: The M.D. Anderson Cancer Center experience. *Sarcoma.* 2014; 2014: 375151. PMID: 25024639. <http://dx.doi.org/10.1155/2014/375151>
- [18] Stevens PL, Johnson DB, Thompson MA, *et al.* Adult neuroblastoma complicated by increased intracranial pressure: a case report and review of the literature. *Case Rep Oncol Med.* 2014; 2014: 341980. <http://dx.doi.org/10.1155/2014/341980>
- [19] Venat-Bouvet L, Le Brun-Ly V, Martin J, *et al.* Long-term survival in adult neuroblastoma with multiple recurrences. *Case Rep Oncol.* 2010; 3(1): 45-48. PMID: 20740158. <http://dx.doi.org/10.1159/000286142>
- [20] Milam MR, Gabel SF, Milam RA, *et al.* Neoadjuvant bleomycin, etoposide, and cisplatin in adult neuroblastoma arising from the broad ligament of the uterus. 2007; 107(2): 350-354.
- [21] Yamaguchi S, Wada T, Oba K, *et al.* Oral etoposide following combination chemotherapy and radiation therapy in a patient with advanced adult neuroblastoma led to long survival. *Int J Clin Oncol.* 2001; 6(5): 259-261. <http://dx.doi.org/10.1007/PL00012115>
- [22] Rowe PH, Oram JJ, Scott GW. Neuroblastoma in adults. *Postgrad Med J.* 1979; 55(646): 579-580. PMID: 514942. <http://dx.doi.org/10.1136/pgmj.55.646.579>
- [23] Barone G, Anderson J, Pearson ADJ, *et al.* New strategies in neuroblastoma: Therapeutic targeting of MYCN and ALK. *Clinical Cancer Res.* 2013; 19(21): 5814-5821. PMID: 23965898. <http://dx.doi.org/10.1158/1078-0432.CCR-13-0680>