

CASE REPORTS

Robot-assisted thoracoscopic resection of giant subcarinal bronchogenic cyst

Vid Fikfak¹, Gaur Puja^{1,2}, Min P. Kim*^{1,2}

¹Department of Surgery, Houston Methodist Hospital, Houston, Texas, United States

²Department of Surgery, Weill Cornell Medical College, Houston Methodist Hospital, Houston, Texas, United States

Received: June 30, 2015

Accepted: August 26, 2015

Online Published: September 2, 2015

DOI: 10.5430/css.v2n1p8

URL: <http://dx.doi.org/10.5430/css.v2n1p8>

ABSTRACT

Operative management of bronchogenic cysts is indicated for symptomatic lesions. The standard operative approach entails a thoracotomy and resection of the cyst from the surrounding structure. In recent years however, operative management has shifted to minimally invasive approaches which are associated with shorter length of stay and better postoperative pain control. Here we present four patients with symptomatic giant subcarinal bronchogenic cysts. The first is a 49-year-old man who developed atrial fibrillation secondary to compression of the atria by a giant subcarinal cyst. He underwent a posterolateral thoracotomy and removal of the cyst with complete resolution of atrial fibrillation. His postoperative course was remarkable for readmission to the hospital a week after discharge for pain control that continued to limit his everyday activity for over a month after surgery. The second patient was a 59-year-old woman with persistent cough secondary to airway compression by a growing inflamed giant subcarinal cyst. A robot-assisted approach was utilized to resect the cyst. Last two patients underwent robot-assisted resection of symptomatic giant subcarinal bronchogenic cyst. Compared to the open approach, robotic resection was associated with shorter length of stay and improved pain control.

Key Words: Bronchogenic cyst, Robot assisted, Minimally invasive, Thoracotomy

1. INTRODUCTION

Bronchogenic cysts are benign solitary developmental anomalies of the primitive foregut. They are most commonly located in the mediastinum and account for 5%-10% of mediastinal masses in the pediatric population.^[1] Most of the cysts are incidentally found on imaging performed for symptoms unrelated to the cysts. In the past, the recommendations were to remove them due to risk of rupture and underlying cancer, however recent literature supports observation for asymptomatic lesions and treatment for symptomatic bronchogenic cysts only.^[2,3] The symptoms associated with bronchogenic cysts are related to their size and the pressure they exert on the surrounding structures. They include cough, atrial fib-

rillation, difficulty swallowing, *etc.* The patients presenting with these symptoms should undergo resection of the cyst to relieve the symptoms and prevent further complications. Cyst resection via thoracotomy has long been the mainstay of treatment, however in recent years the focus has shifted to the utilization of minimally invasive techniques including Video-assisted thoracic surgery (VATS).^[4] In this paper we compare open resection of a giant subcarinal bronchogenic cyst to robot-assisted thoracoscopic resection.

2. CASE PRESENTATION

The first patient is a 49-year-old male with a history of multiple admissions to the emergency room for symptomatic

*Correspondence: Min P. Kim; Email: mpkim@houstonmethodist.org; Address: 6550 Fannin Street, Suite 1661, Houston, TX 77030, United States.

atrial fibrillation. As part of the workup, a CT scan of the chest was obtained and was significant for a 6 by 7 cm subcarinal mass compressing the left atrium. Due to the size of the cyst and proximity to the surrounding structures an open approach was elected via a right posterolateral thoracotomy with division of the latissimus dorsi muscle. After the posterior mediastinum was exposed, the pleura overlying the cyst was resected, and a large cyst was identified adherent to the esophagus, bronchus and pericardium (see Figure 1A). The lesion was carefully resected and removed from the surrounding structures (see Figure 1B). The case took 2 hours and 35 minutes. The patient was transferred to the intensive care unit postoperatively. The chest tube was removed on postoperative day two, and he was discharged home on postoperative day four. By the time discharge the patient was in normal sinus rhythm. The patient presented to the hospital one week after discharge complaining of significant pain at the incision site. Once adequate analgesia was accomplished, he was discharged home and continued taking oral pain medications for another month.

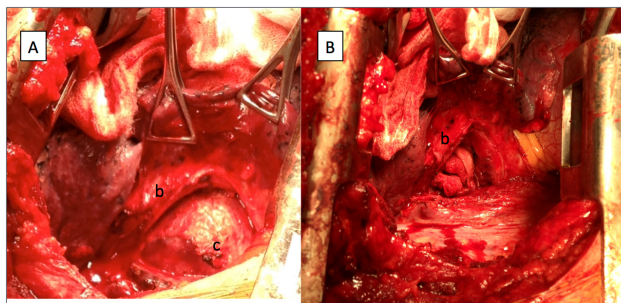


Figure 1. Large subcarinal bronchogenic cyst (c) adjacent to the bronchus (b), esophagus and pericardium (A). Successful removal of the bronchogenic cyst and resulting cavity (B).

The second patient is 59-year-old woman who presented to our clinic for evaluation of a mediastinal mass. She had undergone a CT scan of the chest/abdomen/pelvis in 2009 where an incidental 3.9 cm subcarinal mass was found. This finding prompted further evaluation with a PET/CT scan that did not show any uptake in the mass. As the patient was completely asymptomatic, the risks and benefits of resection were explained to her and she decided to proceed with conservative management with close follow-up. Four years later she presented to our clinic with a persistent cough. A CT scan of the chest was obtained followed by an MRI (see Figure 2A) which revealed that the bronchogenic cyst had increased in size to six centimeters. After a long discussion with the patient, she elected to undergo a robot-assisted resection of the subcarinal mass. In the operating room, the patient was placed in a left lateral decubitus position. Eight millimeter trocars were placed in the 5th intercostal space

mid-axillary line, 8th intercostal space along the tip of the scapula and 8th intercostal space above the spine. A 12 mm camera port was placed in the 7th intercostal space in the posterior axillary line and an assistant 12 mm port in the 9th intercostal space in the mid-axillary line. After entering the chest, the lesion was identified in the subcarinal space, anterior to the esophagus. The pleura overlying the lesion was divided, and the large cyst was separated away from the pleura (see Figure 2B). A thoracic grasper and caudiere was used to manipulate the cyst, and bipolar Maryland dissection to separate it from the esophagus, pericardium and the bronchus, which was difficult due to surrounding inflammation. The cyst wall was then divided and a suture placed through it to facilitate traction and resection of the parts attached to the pericardium and bronchus (see Figure 2C). Finally, the entire cyst was resected, placed in an endocatch bag, removed from the patient and sent for frozen section. The right chest was irrigated with fluid, and a chest tube was placed (see Figure 2D). The case took 4 hours 33 minutes. The results of the pathology were positive for an inflamed bronchogenic cyst. Postoperatively the patient was transferred to the ICU for overnight monitoring and transferred to the floor the following morning. The chest tube was removed on postoperative day one and the patient was discharged home on postoperative day two. On follow up visit she did not report any pain and was off of all pain medication.

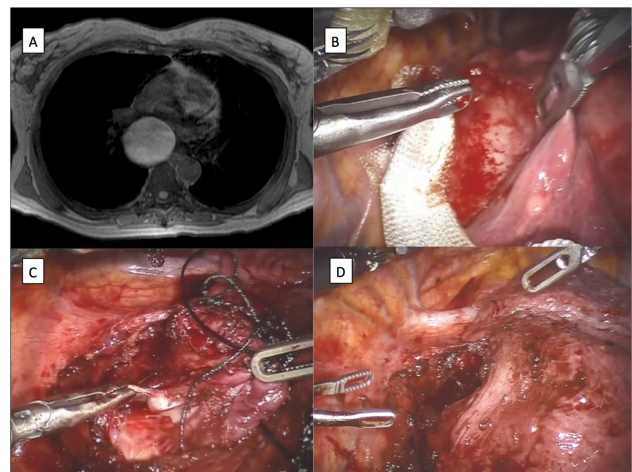


Figure 2. Magnetic resonance imaging of the chest demonstrating a giant subcarinal bronchogenic cyst (A). Visualization of bronchogenic cyst after division of the pleura (B). Retraction of the bronchogenic cyst with suture to aid in manipulation of the cyst (C). Resulting cavity after removal of the cyst (D).

We have since performed two additional robot assisted resections of symptomatic bronchogenic cysts in the subcarinal space. The first patient was a 61-year-old woman with per-

sistent cough secondary to a 6 cm bronchogenic cyst. The lesion was removed using the technique described above in 2 hours 32 minutes and patient was discharged home on post operative day 2. The second patient was a 43-year-old female with back pain and 4 cm infected bronchogenic cyst. Her case took 2 hours 5 minutes and she was discharged home on post operative day 1. Both of the patients had resolution of symptoms and they were off of all pain medication on follow up visit.

3. DISCUSSION

Bronchogenic cysts are most commonly an incidental finding on routine imaging obtained for symptoms unrelated to the cyst. In some cases however they may produce symptoms that are most commonly the result of the size of the cyst and compression of the surrounding structures. Removal of the cyst therefore almost universally resolves these symptoms as was the case in our two patients. Treatment of incidentally found bronchogenic cysts has been controversial. Over two decades ago Patel *et al.* reviewed 18 cases of patients with bronchogenic cysts all of whom underwent surgery for cyst removal. The authors felt that all incidentally found bronchogenic cysts should undergo resection because the diagnosis of a bronchogenic cyst cannot always be safely made preoperatively, and surgical complications in symptomatic patients are more common.^[2] Over a decade later Kirmani *et al.* completed an extensive review of literature

and found that conservative treatment with regular follow-up is a feasible option as more than half of patients with bronchogenic cysts do not develop symptoms and there is only a 0.7% risk of the cyst harboring malignancy.^[3] Surgical approach to bronchogenic cysts has also evolved as more emphasis has been placed on the use of minimally invasive techniques. Video-assisted thoracoscopic approach for resection of a bronchogenic cyst was first utilized in 1991.^[5] In a retrospective review of 113 patients with bronchogenic cysts who underwent a VATS resection Jung *et al.* found only four cases which required conversion to open approach secondary to major adhesions to the bronchus, bronchial tear or left innominate venous injury. The median postoperative stay was 3.7 days.^[4] Robot-assisted procedures are increasingly used for resection of mediastinal masses. Several authors have reported on robotic resection of tumors as well as bronchogenic cysts.^[6,7] The major advantages of the robot over the standard VATS approach include better magnification, 3D image providing depth of field and utilization of the third arm as a tool for continuous retraction. In our experience, the robot therefore allows much better exposure of the cyst and offers better visualization of the operative area. In the presented case we have also demonstrated that larger cysts and those closely adherent to the surrounding structures can safely and effectively be removed using robot-assisted approach while shortening the length of stay and significantly improving postoperative pain management.

REFERENCES

- [1] Shanti CM, Klein MD. Cystic lung disease. *Semin Pediatr Surg.* 2008 Feb; 17(1): 2-8. PMID: 18158136. <http://dx.doi.org/10.1053/j.sempedsurg.2007.10.002>
- [2] Patel SR, Meeker DP, Biscotti CV, *et al.* Presentation and management of bronchogenic cysts in the adult. *Chest.* 1994; 106: 79. PMID: 8020324. <http://dx.doi.org/10.1378/chest.106.1.79>
- [3] Kirmani B, Kirmani B, Sogliani F. Should asymptomatic bronchogenic cysts in adults be treated conservatively or with surgery? *Interact Cardiovasc Thorac Surg.* 2010 Nov; 11(5): 649-59. PMID: 20709698. <http://dx.doi.org/10.1510/icvts.2010.233114>
- [4] Jung HS, Kim DK, Lee GD, *et al.* Video-assisted thoracic surgery for bronchogenic cysts: is this the surgical approach of choice? *Interact Cardiovasc Thorac Surg.* 2014 Nov; 19(5): 824-9. PMID: 25038917. <http://dx.doi.org/10.1093/icvts/ivv228>
- [5] Prates PR, Lovato L, Homsí-Neto A, *et al.* Right ventricular bronchogenic cyst. *Tex Heart Inst J.* 2003; 30: 71-3. PMID: 12638677.
- [6] Xu S, Liu B, Wang X, *et al.* Robotic thoracic surgery of the anterior superior mediastinal bronchogenic cyst. *Ann Transl Med.* 2015 Mar; 3(4): 57. PMID: 25861612.
- [7] Kajiwara N, Kakihana M, Usuda J, *et al.* Extended indications for robotic surgery for posterior mediastinal tumors. *Asian Cardiovasc Thorac Ann.* 2012 Jun; 20(3): 308-13. PMID: 22718720. <http://dx.doi.org/10.1177/0218492311434332>