

## CASE REPORT

# Hand surgeon diagnosis and management of cutaneous infection with *Purpureocillium lilacinum* of the upper extremity: A mimicker of necrotizing fasciitis

Matthew B. Weber, Brady Ernst, Omar Protzuk, Jessica Frankenhoff\*

VCU Medical Center, Richmond, VA, United States

**Received:** October 1, 2023

**Accepted:** November 9, 2023

**Online Published:** December 1, 2023

**DOI:** 10.5430/css.v9n1p1

**URL:** <https://doi.org/10.5430/css.v9n1p1>

## ABSTRACT

*Purpureocillium lilacinum* is a filamentous fungus commonly found in soil that has been recognized as an opportunistic pathogen. Cutaneous infections with *Purpureocillium lilacinum* are relatively rare, and they usually occur in individuals with some predisposing factors such as minor trauma or pre-existing skin conditions. Infections in immunocompetent individuals are unexpected due to the fungus's typically low pathogenicity and the robust immune response of healthy individuals. In immunocompetent hosts, the skin serves as an effective barrier against many fungal infections. While cases of cutaneous infections in immunocompetent hosts have been documented, they are considered rare outliers. Presented is the case of a 93-year-old male who presented to the emergency department with a 10-day history of progressive, painful left upper extremity erythema and swelling. The patient had aggressive progression of hemorrhagic bullae requiring surgical debridement. While the patient's presentation was originally thought to be consistent with necrotizing fasciitis, only cutaneous necrosis was encountered, and the patient was ultimately diagnosed with a superficial *P. lilacinum* infection. The failure of treatment leading to death in the described case could be attributed to a combination of factors including intrinsic resistance of the fungus, delayed diagnosis, underlying health conditions, antifungal susceptibility variations, fungal persistence, and immunosuppressive factors.

**Key Words:** Cutaneous mold, Necrotizing fasciitis, *Purpureocillium lilacinum*, Soft tissue infection, Upper extremity

## 1. INTRODUCTION

*Purpureocillium lilacinum* is a filamentous fungus that was formerly known as *Paecilomyces lilacinus*. It is commonly found in soil and has been recognized as an opportunistic pathogen in various contexts.<sup>[1]</sup> While it is more frequently associated with infections in immunocompromised individuals, there have been reported cases of cutaneous infections in immunocompetent hosts.<sup>[2-5]</sup>

The fungus has been implicated in various infections, including keratitis, onychomycosis, and subcutaneous infections.<sup>[6]</sup>

Cutaneous infections with *Purpureocillium lilacinum* are relatively rare, and they usually occur in individuals with some predisposing factors such as minor trauma or pre-existing skin conditions.<sup>[7]</sup> However, infections in immunocompetent individuals are unexpected due to the fungus's typically low pathogenicity and the robust immune response of healthy individuals.

In immunocompetent hosts, the skin serves as an effective barrier against many fungal infections. The innate immune system and the presence of various antimicrobial pep-

\*Correspondence: Jessica Frankenhoff; Email: [Jessica.frankenhoff@vcuhealth.org](mailto:Jessica.frankenhoff@vcuhealth.org); Address: West Hospital 9<sup>th</sup> Floor 1200 E. Broad St Box 980153 Richmond, VA 23298, United States.

tides contribute to the body's ability to fend off potential pathogens. Infections caused by opportunistic fungi like *Purpureocillium lilacinum* are more likely to take hold in individuals with compromised immune systems, where the immune response is weakened, or in individuals where the skin is incompetent as an infectious barrier.<sup>[8]</sup>

While cases of cutaneous infections in immunocompetent hosts have been documented, they are considered rare outliers. It's thought that these infections might be triggered by a combination of factors, such as the inoculum size of the fungus, local environmental conditions, and individual variations in immune response.

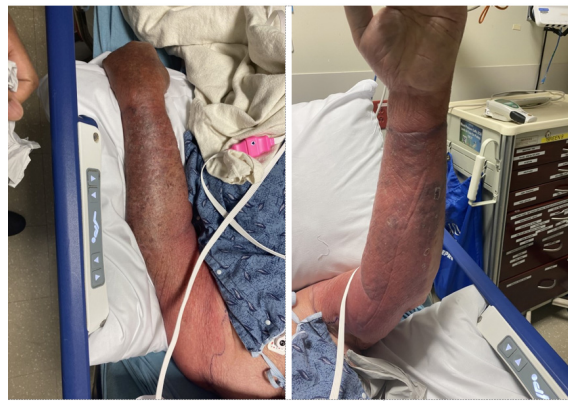## 2. CASE

This is a case of a 93-year-old male who presented to the emergency department with a 10-day history of progressive, painful, left upper extremity erythema and swelling. His past medical history was extensive, and most notable for coronary artery disease with a remote history of coronary artery bypass grafting, atrial fibrillation with pacemaker control, gastrointestinal bleed contraindicating anticoagulation therapy, peripheral arterial disease and chronic venous insufficiency, chronic kidney disease stage III, hyperlipidemia, hypertension, iron deficiency anemia, and hypothyroidism. He was independently living with his wife and performed all activities of daily living on his own.

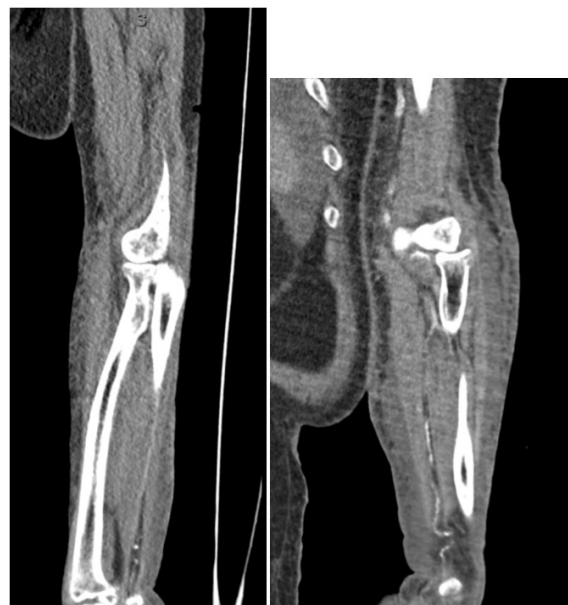He reported that the symptoms began at the elbow and were limited to significant pruritis in the antecubital fossa. He was given a trial of oral steroids for 3 days leading up to his admission with nominal improvement in pruritis. This gradually progressed into painful erythema that subsequently spread throughout the entire extremity. The patient reported receiving bilateral shoulder corticosteroid 3 weeks prior to presentation to the hospital, and initially attributed his pruritis to these injections. He was also an avid gardener and sustained multiple small cuts and abrasions to his arm a week prior to presentation.

On initial presentation to the emergency department, the patient had circumferential erythema, extending from the wrist to the shoulder, which was exquisitely tender to palpation (see Figure 1). Chest radiograph on admission was negative for infection. There was no crepitus noted and no significant open wounds were observed. Cross-sectional imaging of the patient's left arm demonstrated inflammation of the skin and subcutaneous tissues without evidence of gas, fascial inflammation, or deep fluid collections (see Figure 2). The patient's laboratory values and vital signs were benign on presentation (see Table 1). Orthopaedic Hand Surgery was consulted for evaluation of potential necrotizing fasciitis. Contrast-enhanced computed tomography (CT) scan was

negative for any soft tissue emphysema or fluid collection. Based on clinical evaluation (lack of tenderness outside the area of erythema, no pain with passive range of motion of the elbow or wrist), imaging, and labs, there was low suspicion for necrotizing fasciitis. The patient was started on IV antibiotics for suspected cellulitis and was admitted for observation. Infectious disease (I.D.) was additionally consulted. Per their evaluation, they did not suspect any other locus of infection after a thorough physical exam including ocular exam and palpation over the site of the patient's pacemaker. Dermatology additionally evaluated the patient, noting an absence of ocular lesions. I.D. had a concern for necrotizing fasciitis that was not shared by the surgical team, therefore surgery was not performed on the first day of admission.



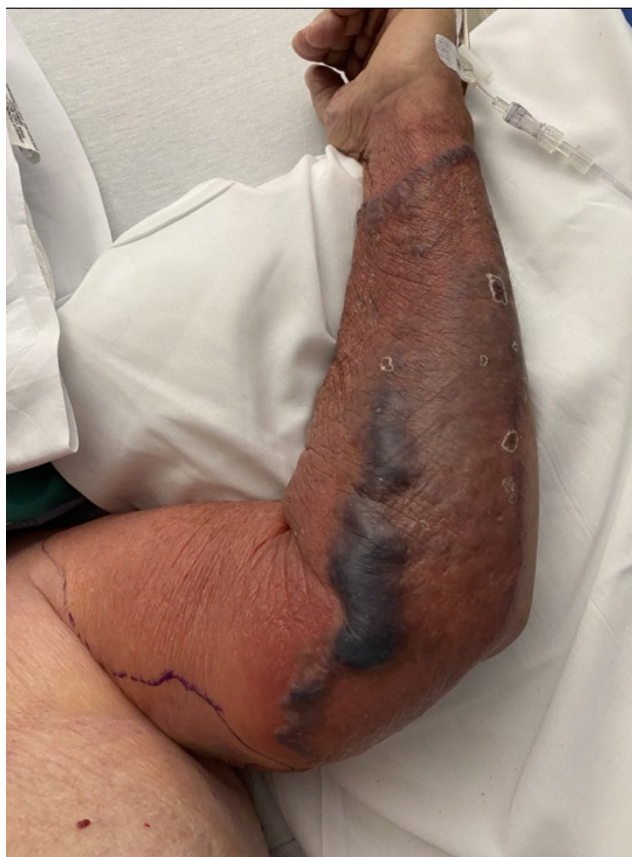**Figure 1.** Presenting physical exam findings on hospital day 1



**Figure 2.** Computed tomography imaging of the left forearm collected on presentation, demonstrating inflammatory changes of the skin and subcutaneous tissues without soft tissue gas or evidence of deep infection

**Table 1.** Laboratory test timetable. Multiple values within a single column are listed in order of draw within that time period.

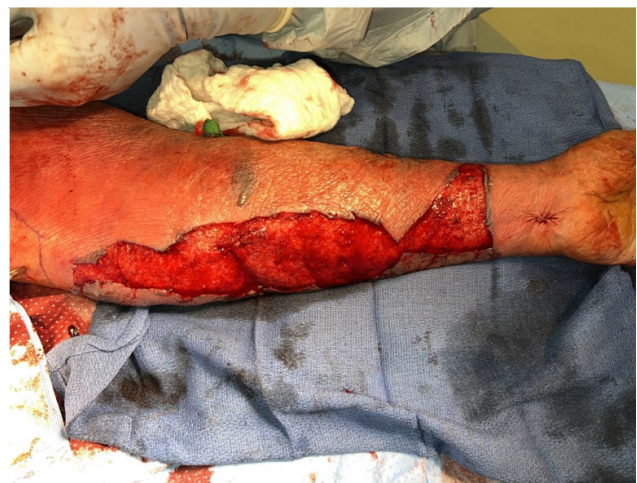Hospital Day	1-2	3-4	5-6	7-8	9-10	11-13	Reference Range (units)
ESR	2						0-15 (mm/hr)
CRP	1.0, 3.5						0.0-0.5 (mg/dL)
WBC	10.5, 10.6	10.4, 9.4	7.9	8.0, 9.5	11.5, 12.1, 10.8, 9.8	9.0, 7.7, 8.5	3.7-9.7 (10e9/L)
Lactate	3.0, 4.2	2.7, 2.4		3.5, 3.2	4.8, 4.6	3.7	0.5-2.0 (mmol/L)
Creatinine	1.88, 0.65	1.62, 1.87, 2.02	2.02, 1.95	1.89, 1.67, 1.77	1.77, 1.92, 1.94, 2.25	2.36, 2.65, 3.00, 3.24	0.6-1.2 (mg/dL)



**Figure 3.** Physical exam findings on hospital day 2

On hospital day 2, the erythema progressed and the patient began forming hemorrhagic bullae to the medial aspect of the elbow despite administration of broad spectrum antibiotics (see Figure 3). The patient was taken for emergent debridement and evaluation of deep soft tissues of the extremity with the Orthopaedic Hand Surgery team after discussion with the Infectious Disease team. Intraoperatively, there were no

signs of necrotizing fasciitis in any of the explored fascial planes of the extremity. There was a notable absence of dishwasher fluid and the bullae were found to contain only blood. No purulent collections were identified. Several areas of devitalized skin were debrided (see Figure 4). Multiple cultures were taken as well as stat frozen skin and fascial pathology samples which did not show areas of necrosis.

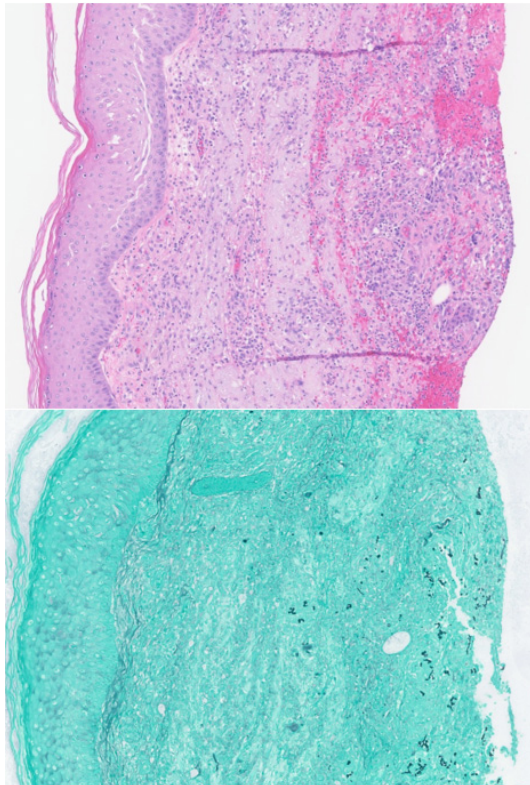


**Figure 4.** Intraoperative findings on hospital day 2

Post-operatively, the patient was treated with antibiotics and local wound care to maintain tissue moisture for a presumptive diagnosis of “severe streptococcal cellulitis with senile purpura” per Infectious Disease. This was subsequently downgraded to “non-purulent cellulitis” and antibiotics were deescalated to ceftriaxone monotherapy. Cellulitis and pain improved over the subsequent days.

Intraoperative cultures, initially negative, returned positive for colonies of *Purpureocillium lilacinum* on hospital day

7. Pharmacologic therapy was therefore transitioned to voriconazole based on recommendations from the Infectious Disease consulting service. Pathology specimens from the index surgery were again reviewed in light of the updated microbiology report. Although not visible on haematoxylin and eosin (H&E) staining, fungal hyphae were noted within the patient's tissues on Grocott methenamine silver (GMS) stain (see Figure 5).

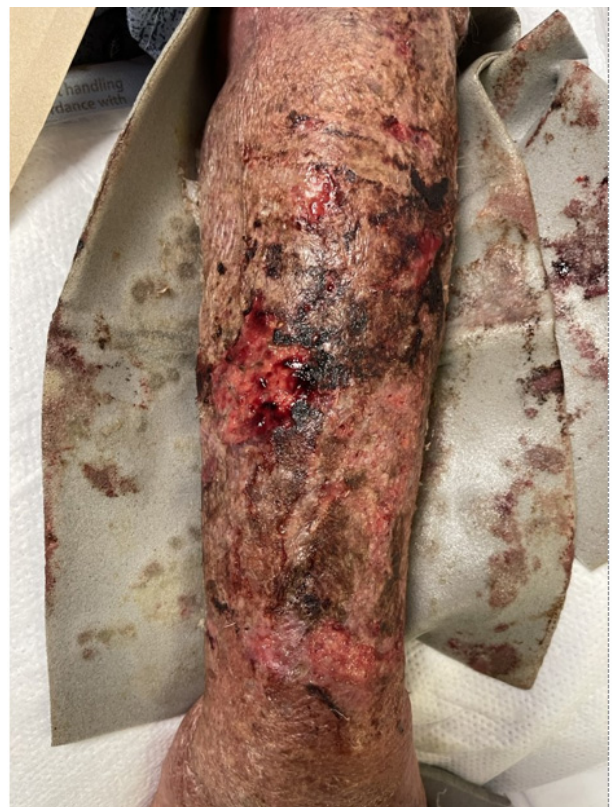

**Figure 5.** Although not visible on haematoxylin and eosin (H&E) staining, fungal hyphae were noted within the patient's tissues on Grocott methenamine silver (GMS) stain

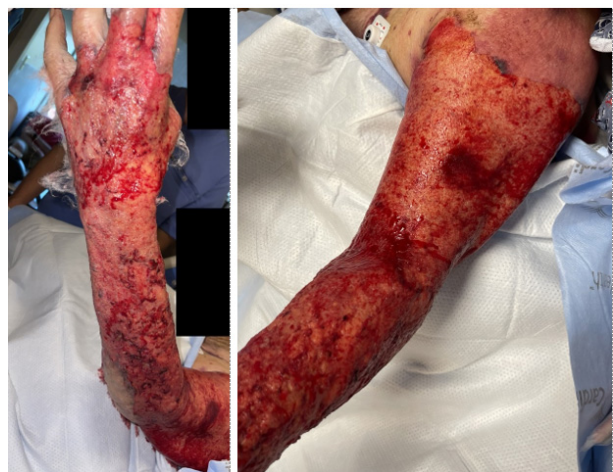On hospital day 8, the patient had extensive progression of hemorrhagic bullae, skin sloughing, and friable epidermis of the entire extremity (see Figure 6). Given the recent confirmation of fungal infection, control with surgical debridement was deemed necessary. The patient was taken to the operating room for extensive circumferential superficial debridement of epidermis and dermis of most of his left upper extremity (see Figure 7).

The patient had exhibited altered mental status and confusion throughout this stay, which progressively worsened. Due to concern for disseminated fungal infection, the patient underwent MRI of the brain and CT of the chest. These studies showed no signs of systemic disease. Soon after, he began to suffer from multisystem organ failure. Kidney function continued to deteriorate with worsening acute on chronic renal

failure and persistently elevated lactate (see Table 1). Despite the exclusive localization of his infection to the upper extremity, his prognosis was guarded. Understanding that systemic antifungals can require 7 days of therapy prior to achieving therapeutic concentrations, the decision was made to transition to palliative care on hospital day 14, which was 6 days after confirmation of his fungal infection. He expired one day after the withdrawal of care.



**Figure 6.** Physical Exam findings on hospital day 8



**Figure 7.** Post Operative Day 1 from extensive debridement on hospital day 9

### 3. DISCUSSION

*Purpureocillium lilacinum* is primarily recognized as an opportunistic pathogen, often seen as ocular infections in those who wear contacts, affecting medical devices such as dialysis catheters, and as cutaneous infections particularly likely to affect those with compromised immune systems. In the case of this elderly gardener with a cutaneous infection associated with pruritis and abrasions, a few key factors may have contributed to the case as described:

- Elderly Age: While the patient is immunocompetent aside from age, it's worth noting that aging is associated with gradual immune system changes, often referred to as immunosenescence.<sup>9</sup> This process can result in a decreased ability to respond effectively to infections. Even in immunocompetent individuals, advanced age might lead to a slightly diminished immune response, potentially creating a conducive environment for opportunistic pathogens like *Purpureocillium lilacinum* to cause infections.
- Gardening Environment: The patient's frequent gardening could indeed be the source of the fungal exposure. Since *Purpureocillium lilacinum* is commonly found in soil and organic matter, individuals who work closely with plants and soil, like gardeners, might be at a higher risk of encountering this fungus.<sup>[4]</sup> The act of scratching the skin could provide an entry point for the fungus, especially if there was a minor cut or abrasion on the skin.

Treatment failure in a case involving extensive surgical debridement and standard antifungal therapy like voriconazole can be perplexing, especially when considering the specifics of the patient's infection caused by *Purpureocillium lilacinum*. There are several factors that could contribute to treatment failure and the unfortunate outcome of the patient's death:

- Intrinsic Antifungal Resistance: One possible reason for treatment failure could be an intrinsic resistance of *Purpureocillium lilacinum* to voriconazole. While voriconazole is commonly used to treat fungal infections, some fungal species, including *Purpureocillium lilacinum*, may exhibit varying levels of resistance to certain antifungal agents.<sup>[10]</sup> In such cases, the fungus might not respond adequately to treatment, leading to a lack of improvement or worsening of the infection.
- Fungal Persistence: Some fungal infections can establish persistent and difficult-to-treat infections, especially in cases where the fungus forms biofilms or resides in protected areas that are difficult to reach through surgical debridement or drug penetration.<sup>1</sup> This could result in a cycle of recurring infection and treatment resistance.

- Delayed Diagnosis: Accurate and timely diagnosis is crucial for successful treatment. In some cases, the diagnosis of *Purpureocillium lilacinum* infections can be challenging, as the symptoms might overlap with other conditions such as necrotizing fasciitis. Delayed diagnosis could result in the infection spreading further and becoming more difficult to manage, even with aggressive surgical debridement and antifungal therapy.

- Underlying Health Conditions: The patient's elderly age and extensive burden of comorbidities might have contributed not only to development of a cutaneous infection, but additionally might have weakened the patient's ability to respond to therapy leading to failure of treatment.

As in this case, an important distinction must be made between necrotizing fasciitis and a simple cutaneous infection or necrotizing erythema. Preoperatively, despite days of symptoms the patient did not demonstrate classic findings of necrotizing fasciitis such as pain with passive range of motion, tenderness outside the area of erythema, elevated white blood cell count, fever, or unstable vital signs. However, when the patient's skin lesions coalesced into hemorrhagic bullae, clinical concern elevated in favor of exploration, even in the absence of the more common signs of necrotizing fasciitis. In retrospect, these bullae were consistent with known cutaneous manifestations of fungal infection with *Purpureocillium lilacinum*.

The severity of necrotizing fasciitis is well known, with life-threatening potential due to uncontrolled spread throughout the fascial planes.<sup>11</sup> Obtaining a swift and accurate diagnosis is critical due to the timely surgical debridement that is typically required. Intraoperative findings of "dishwasher pus," liquified necrotic fat/muscle, and/or venous thrombosis are hallmark findings of this condition, which should prompt radical dissection and further debridement within these fascial planes, up to and including amputation. In addition, there is a role for concurrent treatment with broad spectrum IV antibiotics. At the index surgery, our patient did not exhibit any of these operative findings. This, combined with the intraoperative frozen sections negative for fascial necrosis excluded the diagnosis of necrotizing fasciitis. Reports on the pathology frozen sections initially did not mention fungal infection. Only days later was it noted as an addendum that one of the six tissue sections taken showed fungal elements within an organizing abscess. Given the diagnosis of a cutaneous mold, it was then more appropriate to proceed with a superficial debridement and eventually a targeted antifungal management rather than the extensive deep debridements that necrotizing fasciitis would demand.

In summary, our described patient's case aligns with what

is known about infections caused by *Purpureocillium lilacinum*. The combination of being an elderly gardener who sustained a cutaneous infection by scratching fits into the framework of how this fungus can cause infections even in individuals who are immunocompetent aside from age-related factors. The failure of treatment leading to death in the described case could be attributed to a combination of factors including intrinsic resistance of the fungus, delayed diagnosis, underlying health conditions, antifungal susceptibility variations, fungal persistence, and immunosuppressive factors. A pivotal crossroads was encountered early in this patient's presentation when the consulting hand surgeon was tasked with distinguishing between necrotizing fasciitis and more of a superficial infection. Fungal infections can be highly complex and multifaceted, and even with the best available treatments, there can be instances where the infection proves refractory to therapy, particularly when dealing with opportunistic pathogens like *Purpureocillium lilacinum*.

#### ACKNOWLEDGEMENTS

Not applicable.

#### AUTHORS CONTRIBUTIONS

Dr. Matthew Weber, Dr. Brady Ernst, and Dr. Omar Protzuk were responsible for writing, review, and editing of the submitted manuscript. Dr. Brady Ernst was also involved in the patient's care. Dr. Jessica Frankenhoff was responsible for patient care as well as review and editing of the submitted manuscript.

#### FUNDING

Not applicable.

#### CONFLICTS OF INTEREST DISCLOSURE

The authors declare they have no conflicts of interest.

#### INFORMED CONSENT

Obtained.

#### ETHICS APPROVAL

The Publication Ethics Committee of the Sciedu Press. The journal's policies adhere to the Core Practices established by the Committee on Publication Ethics (COPE).

#### PROVENANCE AND PEER REVIEW

Not commissioned; externally double-blind peer reviewed.

#### DATA AVAILABILITY STATEMENT

The data that support the findings of this study are available on request from the corresponding author. The data are not publicly available due to privacy or ethical restrictions.

#### DATA SHARING STATEMENT

No additional data are available.

#### OPEN ACCESS

This is an open-access article distributed under the terms and conditions of the Creative Commons Attribution license (<http://creativecommons.org/licenses/by/4.0/>).

#### COPYRIGHTS

Copyright for this article is retained by the author(s), with first publication rights granted to the journal.

#### REFERENCES

- [1] Luangsa-ard J, Houbroken J, van Doorn T, et al. *Purpureocillium*, a new genus for the medically important *Paecilomyces lilacinus*. *FEMS Microbiol Lett.* 2011; 321: 141-149. PMID: 21631575. <https://doi.org/10.1111/j.1574-6968.2011.02322.x>
- [2] Saghrouni F, Saidi W, Ben Said Z, et al. Cutaneous hyalohyphomycosis caused by *Purpureocillium lilacinum* in an immunocompetent patient: case report and review. *Med Mycol.* 2013; 51: 664-668. PMID: 23330674. <https://doi.org/10.3109/13693786.2012.757656>
- [3] Hamon L, El Halabi M, Flockerzi FA, et al. *Purpureocillium lilacinum*: Atypical pathogen of mycotic keratitis in an immunocompetent patient. *Ophthalmol.* 2022; 119: 300-303. PMID: 33580805. <https://doi.org/10.1007/s00347-021-01325-4>
- [4] McGeachie DL, Boyce AE, Miller RM. Recurrent cutaneous hyalohyphomycosis secondary to *Purpureocillium lilacinum* in an immunocompetent individual. *Australas J Dermatol.* 2021; 62: e411-e413. PMID: 34170516. <https://doi.org/10.1111/ajd.13657>
- [5] Gutiérrez-Rodero F, Moragón M, Ortiz de la Tabla V, et al. Cutaneous Hyalohyphomycosis Caused by *Paecilomyces lilacinus* in an Immunocompetent Host Successfully Treated with Itraconazole: Case Report and Review. *Eur J Clin Microbiol Infect Dis.* 1999; 18: 814-818. PMID: 10614958. <https://doi.org/10.1007/s100960050407>
- [6] Sprute R, Salmanton-García J, Sal E, et al. Invasive infections with *Purpureocillium lilacinum*: clinical characteristics and outcome of 101 cases from FungiScope® and the literature. *J Antimicrob Chemother.* 2021; 76: 1593-1603. PMID: 33599275. <https://doi.org/10.1093/jac/dkab039>
- [7] Albert R, Lemaigen A, Desoubeaux G, et al. Chronic subcutaneous infection of *Purpureocillium lilacinum* in an immunocompromised patient: Case report and review of the literature. *Med Mycol Case Rep.* 2022; 38: 5-8. PMID: 36147049. <https://doi.org/10.1016/j.mmcr.2022.08.001>
- [8] Pastor FJ, Guarro J. Clinical manifestations, treatment and outcome of *Paecilomyces lilacinus* infections. *Clin Microbiol Infect.* 2006; 12:

- 948-960. PMID: 16961630. <https://doi.org/10.1111/j.1469-0691.2006.01481.x>
- [9] Hof H. Mycoses in the elderly. *Eur J Clin Microbiol Infect Dis.* 2010; 29: 5-13. PMID: 19911208. <https://doi.org/10.1007/s10096-009-0822-5>
- [10] Corrêa-Moreira D, de Lima Neto RG, da Costa GL, et al. Purpure-ocillium lilacinum an emergent pathogen: antifungal susceptibility of environmental and clinical strains. *Lett Appl Microbiol.* 2022; 75: 45-50. PMID: 35342967. <https://doi.org/10.1111/lam.13707>
- [11] Bonne SL, Kadri SS. Evaluation and Management of Necrotizing Soft Tissue Infections. *Infect Dis Clin North Am.* 2017; 31: 497-511. PMID: 28779832. <https://doi.org/10.1016/j.idc.2017.05.011>