

## CASE REPORT

# Thumb metacarpal dislocation after trapeziectomy with ligamentous reconstruction and tendon interposition: A case report

Matthew B. Weber, Jessica Frankenhoff\*

*Department of Orthopaedic Surgery, Virginia Commonwealth University, Richmond, United States*

**Received:** October 3, 2022

**Accepted:** November 22, 2022

**Online Published:** November 29, 2022

**DOI:** 10.5430/css.v8n1p1

**URL:** <https://doi.org/10.5430/css.v8n1p1>

## ABSTRACT

Thumb carpometacarpal (CMC) arthritis is one of the most common and debilitating pathologies evaluated by the hand surgeon, affecting up to 35% of individuals over 55 years of age. Though multifactorial in etiology, dorsal and radial subluxation of the thumb CMC due to incompetency of the volar beak ligament is thought to be among the most important factors contribution to the arthritis. Multiple operative interventions have been proposed to best address this pathology. In the United States, trapeziectomy with ligament reconstruction and tendon interposition (LRTI) as described by Burton and Pellegrini remains the most widely used technique. As an isolated trauma, dislocation of the thumb CMC joint is a rare injury, only comprising approximately 1% of injuries evaluated by hand surgeons. Typically, thumb CMC dislocations occur due to axial load with the thumb in a flexed position. They are most commonly dorsal dislocations, and are thought to occur due to failure of the dorsoradial ligament. To date, no cases of CMC dislocation after LRTI have yet been described in the literature. Here we present a patient with volar thumb CMC dislocation as a rare complication after LRTI. After percutaneous pinning and immobilization followed by hand therapy, the patient has had a successful return to work with improved pain, restored function, and no further instability.

**Key Words:** Thumb, Metacarpal dislocation, Trapeziectomy, Ligamentous reconstruction with tendon interposition

## 1. INTRODUCTION

Thumb carpometacarpal (CMC) arthritis is one of the most common and debilitating pathologies evaluated by the hand surgeon, affecting up to 35% of individuals over 55 years of age.<sup>[1,2]</sup> Though multifactorial in etiology, dorsal and radial subluxation of the thumb CMC due to incompetency of the volar beak ligament is thought to be among the most important factors contribution to the arthritis.<sup>[3]</sup> Multiple operative interventions have been proposed to best address this pathology, including simple trapeziectomy, trapeziectomy with ligament reconstruction, silicone or pyrocarbon

arthroplasty, and CMC arthrodesis.<sup>[4,5]</sup> In the United States, trapeziectomy with ligament reconstruction and tendon interposition (LRTI) as described by Burton and Pellegrini remains the most widely used technique.<sup>[6-8]</sup>

As an isolated trauma, dislocation of the thumb CMC joint is a rare injury, only comprising approximately 1% of injuries evaluated by hand surgeons.<sup>[9]</sup> Typically, thumb CMC dislocations occur due to axial load with the thumb in a flexed position.<sup>[10]</sup> They are most commonly dorsal dislocations, and are thought to occur due to failure of the dorsoradial ligament.<sup>[11]</sup>

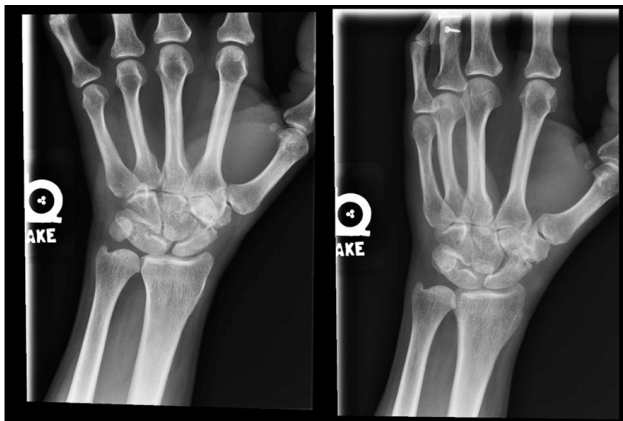
\***Correspondence:** Jessica Frankenhoff; Email: [Jessica.frankenhoff@vcuhealth.org](mailto:Jessica.frankenhoff@vcuhealth.org); Address: West Hospital 9<sup>th</sup> Floor 1200 E. Broad St Box 980153 Richmond, VA 23298, United States.

To date, no cases of CMC dislocation after LRTI have yet been described in the literature. Here we present a patient with volar thumb CMC dislocation as a rare complication after LRTI.

## 2. CASE PRESENTATION

We present the case of a 50-year-old woman with chronic left CMC and STT arthritis. She reported difficulty using her left thumb in her work as a cook, noting pain with pinch and grasp causing her to drop objects. She received moderate relief from two STT (scaphotrapeziotrapezoid) injections as well as thumb splinting and topical anti-inflammatory gel. After conservative treatment failed to provide lasting relief, she was interested in discussing surgical intervention.

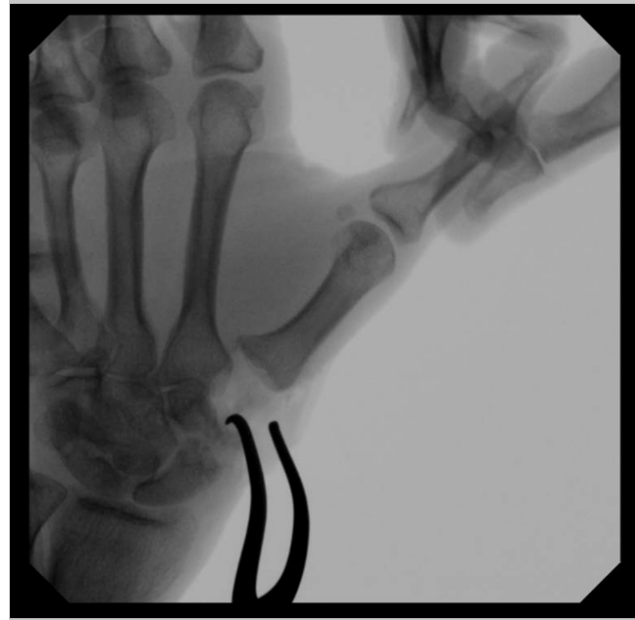On physical exam, the patient was noted to have pain with axial loading of the thumb CMC joint as well as pain with STT compression. She also had hyperextension of the left MCP (metacarpophalangeal) joint to approximately 20 degrees. Imaging revealed degenerative sclerotic changes about the left thumb CMC and STT joints (see Figure 1).



**Figure 1.** Preoperative PA and oblique radiographs of the left hand demonstrating degenerative sclerotic changes about the left thumb CMC and STT joints

In June 2020, the patient underwent trapeziectomy with flexor carpi radialis ligament reconstruction and tendon interposition. The procedure was carried out in the standard technique as described by Burton and Pellegrini, with the exception that the entire flexor carpi radialis was harvested for ligament reconstruction and interposition, which is the usual technique used by the operating surgeon (J.F.). She also had a small portion of the proximal trapezoid removed to address her STT arthritis, which is standard practice when STT arthritis is also present.<sup>[6]</sup> The flexor carpi radialis was passed through a hole in the base of the thumb metacarpal, tensioned to suspend the first metacarpal and then was secured with 4-0 Ethibond suture to the bone/periosteum. The

remainder of the tendon was placed into the dead space between the first metacarpal and scaphoid. A satisfactory result was confirmed fluoroscopically as seen in Figure 2. Due to preoperative hyperextension, the MCP joint was pinned in approximately 20 degrees of flexion. The patient was placed into a thumb spica splint with the thumb in abduction.



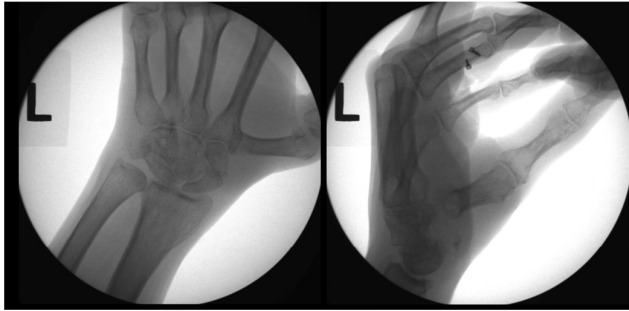
**Figure 2.** Intraoperative radiograph with axial traction applied to the thumb demonstrating complete trapeziectomy and lack of osteophytes between thumb and index metacarpals

At the two-week postoperative visit, the splint was removed and replaced with a thumb spica cast. At the four-week postoperative visit the MCP joint pin was removed and the patient was sent to hand therapy for a custom thumb spica splint with instruction to wear this continuously except for showering for an additional two weeks. Therapy started at six weeks postoperatively, and at the eight- and nine-week therapy sessions the patient noted an improvement in range of motion, a reduction in swelling, as well as a return of functional use of her thumb.

At eleven weeks postoperatively the patient reported to the therapist an increase in pain as a result of a fall off of a bus the week prior. After the fall her thumb became more swollen and sore with pain centered about the thumb MCP joint.

On physical exam, the MCP joint was noted to have abnormal swelling, and the MCP was held in significant flexion with an inability to passively extend the MCP joint. No significant tenderness was detected about the CMC area.

In-office fluoroscopy was used to evaluate the thumb, revealing dislocation of the left thumb metacarpal base (see Figure 3). The thumb metacarpal was noted to be almost perpendicular to the index metacarpal base, with significant and pathologic overlap between the two. On lateral views, this appeared to be a volar dislocation. There was no evidence of thumb metacarpal subsidence to suggest failure of the ligamentous reconstruction. The dislocation was not reducible in office under fluoroscopy, therefore the patient was scheduled for closed versus open reduction and percutaneous pinning.

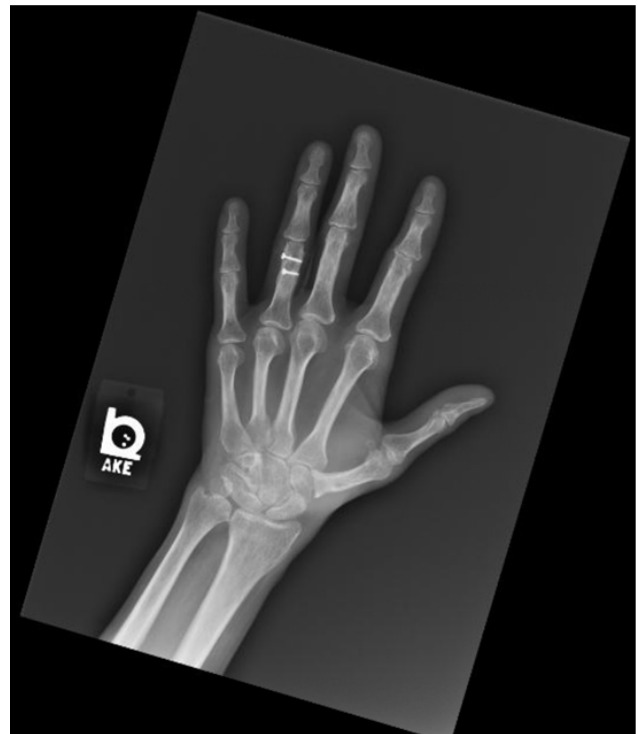

**Figure 3.** In-clinic fluoroscopy AP and lateral views demonstrating dislocation of the left thumb metacarpal from its articulations with the index metacarpal and interposition graft

Intraoperatively, the dislocation was unable to be reduced in a closed fashion under sedation so the previous incision was re-incised, and dissection through scar was carried carefully down to the arthroplasty site. No fluid or synovitis was encountered surrounding the tendon interposition, which itself was found to be intact and appropriately positioned just distal to the scaphoid in the dead space. Likewise, the ligamentous reconstruction was also intact within the bone tunnel. After circumferentially dissecting around the tendon interposition and base of the thumb metacarpal, the thumb metacarpal still resisted multiple attempts at reduction. The tendon interposition was then removed to allow for enhanced visualization and mobility of the metacarpal base, at which point further soft tissue could be released and the thumb metacarpal base could be positioned adjacent and now more parallel to the index metacarpal. However, the thumb metacarpal demonstrated re-dislocation if not held in place manually. The metacarpal base was held in appropriate position, after which it was pinned to the index metacarpal with two 0.062 inch Kirschner wires. The tendon interposition was returned to the trapeziectomy dead space. Postoperatively, the patient remained splinted with periodic scheduled wound checks from weeks two through six. At six weeks postoperatively, her pins were removed and she was kept immobilized in a well-padded fiberglass cast. Her cast was then removed at eight

weeks and a removable thumb spica splint was again provided with instructions to begin hand therapy at the ten-week mark.

At four months, she was seen for her final scheduled post-operative visit, at which time she reported no limitations with activities or work due to pain. On physical exam, she had a normal appearance to her left hand with no tenderness over the CMC joint space. She demonstrated satisfactory circumduction, and was able to approximate her thumb tip to her other fingertips as well as the base of the small finger. Final X-rays showed maintenance of suspension of her thumb metacarpal without subsidence and without dislocation (see Figure 4).



**Figure 4.** Final radiograph taken after pin removal demonstrating maintenance of thumb metacarpal suspension without subsidence and without dislocation

At nearly 24 months the patient has had no further difficulties with pain, disability, or dislocation of the left thumb.

### 3. DISCUSSION

While CMC dislocation has not previously been reported after LRTI, other more common complications have been well documented. These include paresthesias, Complex Regional Pain Syndrome, wound and scar related issues, tendon rupture, symptomatic subsidence, and prolonged swelling.<sup>[12,13]</sup> Rarely is reoperation required, with figures cited as low as 2.5%-2.9% across all techniques of CMC

arthroplasty.<sup>[14,15]</sup> Dislocation has been commonly reported as a complication of arthroplasty with synthetic implants and resurfacing, however the majority of these reports refer to dislocation/extrusion of the implants themselves, rather than dislocation of the thumb metacarpal from its expected alignment.<sup>[16,17]</sup> Furthermore, the techniques associated with synthetic arthroplasty differ substantially from LRTI in that ligament reconstruction provides greater stability and restraint to motion of the thumb metacarpal base than resurfacing or interposition grafting procedures without ligament reconstruction. Extrusion of the tendon interposition graft has also been reported after LRTI, however that was not a factor in this particular case.<sup>[18]</sup>

Mobility and laxity of the base of the thumb metacarpal after LRTI is also well-studied, with much focus given to subsidence and dorsal subluxation. Subsidence is frequently cited as one of the main complications of LRTI.<sup>[12,19]</sup> However, the clinical relevance of radiographic subsidence is still a subject of debate.<sup>[20]</sup> Dorsoradial metacarpal base subluxation have also been tracked in the literature.<sup>[20,21]</sup> While these measures indicate potential for mobility issues of the thumb metacarpal base after LRTI, in no previously reported case has this resulted in a dislocation.

When traumatic dislocations do occur, the thumb metacarpal most often dislocates dorsally, with the thumb held in adduction. In this case, the patient's thumb had dislocated in near perpendicular abduction volarly. Volar CMC dislocations have been previously described, although they are rare.<sup>[22,23]</sup> Although atypical in presentation, this patient was successfully managed with a standard treatment of percutaneous pinning and splint immobilization.<sup>[24,25]</sup> Unlike many cases of primary dislocation which variably require ligament reconstruction, our patient had already gone ligament reconstruction as an element of the index operation, and this was

found to be intact.

Wollstein et al. described the case of a chronic, recurrent thumb CMC dislocation treated with trapeziectomy and a modified LRTI.<sup>[26]</sup> At work and in the office, that patient's preoperative dislocation was reducible with effort, but demonstrated a natural tendency to dislocate, as was the case with our patient. Wollstein et al. highlight the role of attentive postoperative hand therapy to address soft tissue imbalances at the CMC joint, likely coincident with and related to the pathophysiology of thumb osteoarthritis itself. In that particular case it is also worth noting that LRTI was not the antecedent, but rather the therapeutic solution for the chronic dislocation.

In summary, we present the novel case of a patient who experienced a traumatic thumb CMC dislocation approximately ten weeks after LRTI. Unlike many primary dislocations which are ligament-disruptive, held in adduction, and dorsally dislocated, our patient's dislocation was volar and in abduction with an intact ligament reconstruction. Whether the patient was made more or less susceptible to having this particular type of dislocation by undergoing LRTI is impossible to know, though probable. The patient had no known underlying connective tissue disorder to explain hyperlaxity at that joint, suggesting no particular predisposing pathology beyond simple trauma. It may also be the case that osteoarthritis-related capsular degeneration and other soft tissue imbalances may have been a factor in overall joint instability. After percutaneous pinning and immobilization followed by hand therapy, the patient has had a successful return to work with improved pain, restored function, and no further instability.

## CONFLICTS OF INTEREST DISCLOSURE

The authors declare they have no conflicts of interest.

## REFERENCES

- [1] Dahaghin S, Bierma-Zeinstra SM, Ginai AZ, et al. Prevalence and pattern of radiographic hand osteoarthritis and association with pain and disability (the Rotterdam study) [published correction appears in *Ann Rheum Dis*. 2005 Aug; 64(8):1248. *Ann Rheum Dis*. 2005; 64(5): 682-687. PMID: 15374852. <https://doi.org/10.1136/ard.2004.023564>
- [2] Sodha S, Ring D, Zurakowski D, et al. Prevalence of osteoarthritis of the trapeziometacarpal joint. *J Bone Joint Surg Am*. 2005; 87(12): 2614-2618. PMID: 16322609. <https://doi.org/10.2106/00004623-200512000-00003>
- [3] Doerschuk SH, Hicks DG, Chinchilli VM, et al. Histopathology of the palmar beak ligament in trapeziometacarpal osteoarthritis. *J Hand Surg Am*. 1999; 24(3): 496-504. PMID: 10357527. <https://doi.org/10.1053/jhsu.1999.0496>
- [4] Berger AJ, Meals RA. Management of osteoarthritis of the thumb joints. *J Hand Surg Am*. 2015; 40(4): 843-850. PMID: 25754790. <https://doi.org/10.1016/j.jhsa.2014.11.026>
- [5] Huang K, Hollevoet N, Giddins G. Thumb carpometacarpal joint total arthroplasty: a systematic review. *J Hand Surg Eur Vol*. 2015; 40(4): 338-350. PMID: 25600851. <https://doi.org/10.1177/1753193414563243>
- [6] Burton RI, Pellegrini VD Jr. Surgical management of basal joint arthritis of the thumb. Part II. Ligament reconstruction with tendon interposition arthroplasty. *J Hand Surg Am*. 1986 May; 11(3): 324-32. [https://doi.org/10.1016/S0363-5023\(86\)80137-X](https://doi.org/10.1016/S0363-5023(86)80137-X)
- [7] Wolf JM, Delaronde S. Current trends in nonoperative and operative treatment of trapeziometacarpal osteoarthritis: a survey of US hand

- surgeons. *J Hand Surg Am.* 2012; 37(1): 77-82. PMID: 22119601. <https://doi.org/10.1016/j.jhsa.2011.10.010>
- [8] Deutch Z, Niedermeier SR, Awan HM. Surgeon Preference, Influence, and Treatment of Thumb Carpometacarpal Arthritis. *Hand.* 2018; 13(4): 403-411. PMID: 28685589. <https://doi.org/10.1177/1558944717717506>
- [9] Mueller JJ. Carpometacarpal dislocations: report of five cases and review of the literature. *J Hand Surg.* 1986; 11: 184-188. [https://doi.org/10.1016/S0363-5023\(86\)80048-X](https://doi.org/10.1016/S0363-5023(86)80048-X)
- [10] Strauch RJ, Behrman MJ, Rosenwasser MP. Acute dislocation of the carpometacarpal joint of the thumb: an anatomic and cadaver study. *J Hand Surg Am.* 1994 Jan; 19(1): 93-8. [https://doi.org/10.1016/0363-5023\(94\)90229-1](https://doi.org/10.1016/0363-5023(94)90229-1)
- [11] Owings FP, Calandruccio JH, Mauck BM. Thumb ligament injuries in the athlete. *Orthop Clin N Am.* 2016; 47(4): 799-807. PMID: 27637666. <https://doi.org/10.1016/j.ocl.2016.06.001>
- [12] Naram A, Lyons K, Rothkopf DM, et al. Increased Complications in Trapeziectomy With Ligament Reconstruction and Tendon Interposition Compared With Trapeziectomy Alone. *Hand.* 2016 Mar; 11(1): 78-82. PMID: 27418894. <https://doi.org/10.1177/1558944715617215>
- [13] Wajon A, Carr E, Edmunds I, et al. Surgery for thumb (trapeziometacarpal joint) osteoarthritis. *Cochrane Database Syst Rev.* 2009; 4: CD004631. <https://doi.org/10.1002/14651858.CD004631.pub3>
- [14] Cooney WP 3rd, Leddy TP, Larson DR. Revision of thumb trapeziometacarpal arthroplasty. *J Hand Surg Am.* 2006 Feb; 31(2): 219-27. PMID: 16473682. <https://doi.org/10.1016/j.jhsa.2005.10.018>
- [15] Megerle K, Grouls S, Germann G, et al. Revision surgery after trapeziometacarpal arthroplasty. *Arch Orthop Trauma Surg.* 2011 Feb; 131(2): 205-10. PMID: 20559647. <https://doi.org/10.1007/s00402-010-1128-x>
- [16] Lallemand B, Cheval D, Camps C, et al. Outcome of Silicone Implant for Treatment After Failure of Primary Trapeziometacarpal Surgery. *J Hand Surg Am.* 2020; 45(5): 451.e1-451.e5. PMID: 31818540. <https://doi.org/10.1016/j.jhsa.2019.09.013>
- [17] Logan J, Peters SE, Strauss R, et al. Pyrocardan Trapeziometacarpal Joint Arthroplasty-Medium-Term Outcomes. *J Wrist Surg.* 2020 Dec; 9(6): 509-517. Epub 2020 Aug 21. PMID: 33282537. <https://doi.org/10.1055/s-0040-1714685>
- [18] Satteson ES, Langford MA, Li Z. The management of complications of small joint arthrodesis and arthroplasty. *Hand Clin.* 2015 May; 31(2): 243-66. PMID: 25934200. <https://doi.org/10.1016/j.hcl.2015.01.002>
- [19] Shonuga O, Nicholson K, Abboudi J, et al. Thumb-basal joint arthroplasty outcomes and metacarpal subsidence: A prospective cohort analysis of trapeziectomy with suture button suspension-plasty versus ligament reconstruction with tendon interposition. *Hand.* 2021 Mar 31; 1558944721994227. PMID: 33789518. <https://doi.org/10.1177/1558944721994227>
- [20] Reissner L, Marks M, Schindele S, et al. Comparison of clinical outcome with radiological findings after trapeziectomy with ligament reconstruction and tendon interposition. *J Hand Surg Eur Vol.* 2016; 41(3): 335-339. PMID: 26637826. <https://doi.org/10.1177/1753193415616959>
- [21] Miura T, Ando M, Tanaka S, et al. Assessment of Dorsal Subluxation in Thumb Carpometacarpal Osteoarthritis. *J Hand Microsurg.* 2018 Dec; 10(3): 125-129. PMID: 30483017. <https://doi.org/10.1055/s-0038-1636730>
- [22] Sawalha S. Volar dislocation of the thumb carpometacarpal joint: A case report. *Injury Extra.* 2008; 39(10): 332-4. <https://doi.org/10.1016/j.injury.2008.05.009>
- [23] Farzan M, Siassi M, Espandar R. Thumb carpometacarpal joint volar dislocation: A case report. *Acta Med Iran.* 2002; 40(1): 52-4.
- [24] Watt N, Hooper G. Dislocation of the trapezio-metacarpal joint. *J Hand Surg Br.* 1987 Jun; 12(2): 242-5. PMID: 3624988. [https://doi.org/10.1016/0266-7681\\_87\\_90024-6](https://doi.org/10.1016/0266-7681_87_90024-6)
- [25] Kim JS, Hussain K, Higginbotham DO, et al. Management of thumb carpometacarpal joint dislocations: A systematic review. *J Orthop.* 2021 Apr 1; 25: 59-63. PMID: 33927510. <https://doi.org/10.1016/j.jor.2021.03.015>
- [26] Wollstein R, Michael D, Harel H. Postoperative Therapy for Chronic Thumb Carpometacarpal (CMC) Joint Dislocation. *Am J Occup Ther.* 2016 Jan-Feb; 70(1): 7001350020p1-4. PMID: 26709434. <https://doi.org/10.5014/ajot.2016.017210>