

CASE REPORTS

Brief report: De Garengeot's hernia

M. Hunter Witt^{*1}, Adam R. Eppler², Ahmed M. Mahmoud³

¹Department of Surgery, WellSpan Health York Hospital, York, PA, United States

²Department of Surgery, University of Mississippi Medical Center, Jackson, Mississippi, United States

³Mission Surgical Clinic, Riverside, CA, United States

Received: April 17, 2019

Accepted: July 1, 2019

Online Published: September 17, 2019

DOI: 10.5430/css.v5n1p9

URL: <https://doi.org/10.5430/css.v5n1p9>

ABSTRACT

We describe a case of a 70-year-old female who presented with pain and swelling in her right groin. CT scan of the abdomen and pelvis found Amyand's hernia with evidence of inflammation of the appendiceal tip consistent with appendicitis. Laparoscopic appendectomy and open hernia repair revealed an incarcerated hernia. Using blunt dissection, the inflamed tip of the appendix was found in the femoral canal. The appendix was removed. The patient had a De Garengeot's hernia, not the Amyand's hernia initially suspected. Patient was discharged home the following day.

Key Words: Hernia, De Garengeot's Hernia, Femoral hernia, Incarcerated hernia

1. INTRODUCTION

First described in 1731, De Garengeot's hernia is a rare subtype of femoral hernia. A previous case report by Comman et al. discussed performed the surgery through a TAPP approach and laparoscopic appendectomy.^[1] We had discussed performing our operation in this fashion but were unable to reduce the inflamed head of the appendix into the abdominal cavity, continued manipulation also increased the risk of perforating the appendiceal body. As with our case, it can often be misdiagnosed with only 44% of CT studies successfully diagnosing femoral hernia appendicitis.^[2] We describe a case in a 70 year old female.

2. CASE DESCRIPTION

A 70-year-old female presented to our facility with a four day history of increasing pain and swelling in her right groin. She denied fevers or chills. Physical exam revealed a tender region in the right groin and induration with associated skin changes. Our emergency department performed a CT

abdomen/pelvis with IV contrast to determine the contents of the hernia. Figure 1 is the most prominent view of the hernia, and this was read by our radiologists as an Amyand's hernia with evidence of inflammation of the appendiceal tip consistent with appendicitis. The appendix was likely healthy upon herniation into the femoral canal and became strangulated, even if reducible the risk of perforation remains high and decision was made to perform an appendectomy no matter the findings in the operating room. The patient was started on antibiotics and was taken to the operating room for a laparoscopic appendectomy and open hernia repair. Upon entering the abdomen, first examination of the right lower quadrant revealed Figure 2. We attempted to reduce the hernia contents into the abdominal cavity with no success. The base of the appendix and mesoappendix were stapled and ligated, thus allowing for a safer exploration of the groin in an open fashion with the appendix free to be delivered. Upon performing the dissection of the groin, inflammation was noted throughout inferior tissue prior to entering the

*Correspondence: M. Hunter Witt; Email: mwitt2@wellspan.org; Address: Department of Surgery, WellSpan Health York Hospital, York, PA, United States.

inguinal canal. Using blunt dissection, the inflamed tip of the appendix was found in the femoral canal. The appendix was removed as can be seen in Figure 3. The patient had a De Garengot's hernia, not the Amyand's hernia we had initially suspected. The patient tolerated the procedure well and had an unremarkable post-operative course, discharged home the following day.

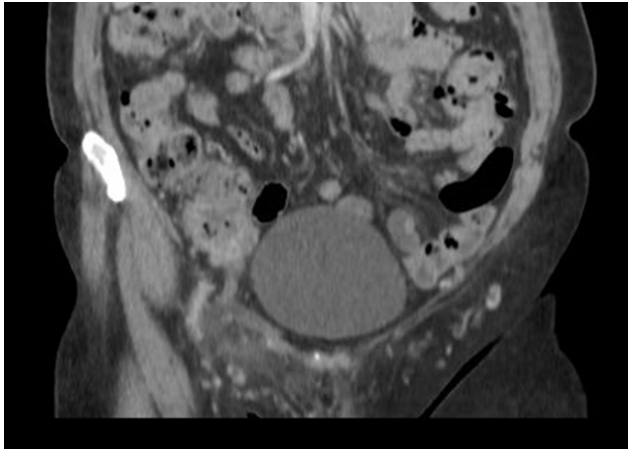


Figure 1. CT scan of the abdomen/pelvis revealing appendix entering groin

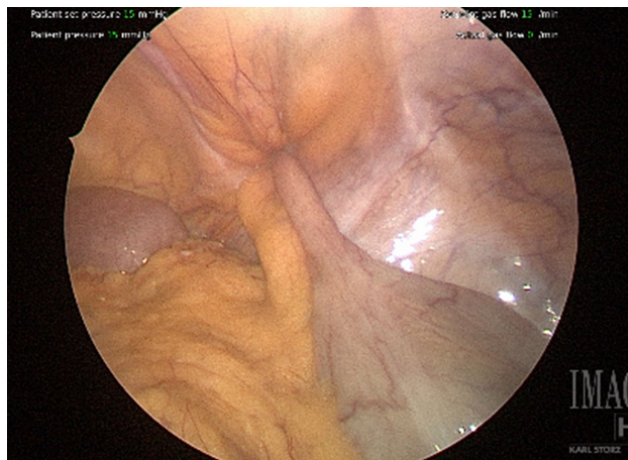


Figure 2. Laparoscopic view of hernia

3. DISCUSSION

Right lower quadrant abdominal pain is a frequent complaint of patients who need surgical evaluation in the emergency de-

partment. Although appendicitis, colitis, nephrolithiasis and many other diagnoses may be more common, we must not forget these rare hernias such as De Garengot. There is a predisposition of femoral hernias especially in postmenopausal women. Imaging studies may not be specific enough to determine the exact diagnosis. Early surgical treatment is indicated to establish the diagnosis and treat the underlying cause of the patient's symptoms.

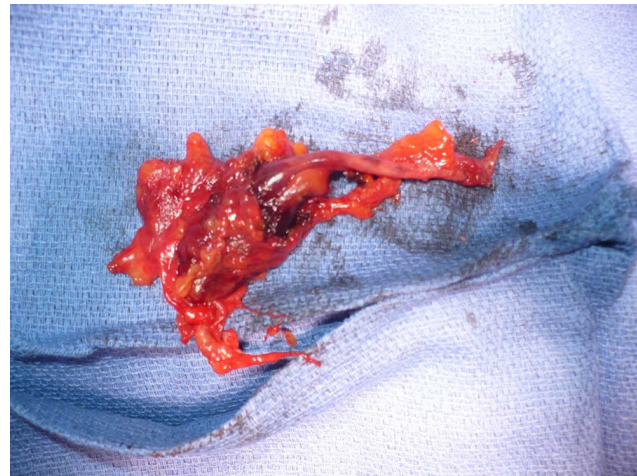


Figure 3. Gross specimen removed from patient, tip appendicitis well demonstrated

De Garengot's hernia is a rare subtype of an incarcerated femoral hernia. This case reports an elderly woman with right groin pain initially diagnosed with an Amyand's hernia. Intraoperatively we discovered the patient had her appendix incarcerated in her femoral hernia. An appendectomy was performed, and an open inguinal incision was utilized to retrieve the appendix. Early surgical intervention is necessary to accurately diagnose and treat patients with possible De Garengot's hernia.

ACKNOWLEDGEMENTS

We would like to thank Diane Shih, MD for her training and mentorship, as well as Rodney Grim, PhD for help with submitting this manuscript.

CONFLICTS OF INTEREST DISCLOSURE

The authors declare they have no conflicts of interest.

REFERENCES

- [1] Comman A, Gaetzschmann P, Hanner T, et al. DeGarengot hernia: transabdominal preperitoneal hernia repair and appendectomy. *JLS*. 2007; 11(4): 496-501.
- [2] Saylam B, Gülseren MO, Şimşek B, et al. Incarcerated appendix within femoral hernia. *Formos J Surg*. 2014; 47(6): 231-232. <https://doi.org/10.1016/j.fjs.2014.06.001>