

## CASE REPORTS

# Refractory bleeding from ectopic varices stopped by percutaneous transhepatic portal vein recanalization and stenting

Guido Poggi\*<sup>1</sup>, Cesare Massa Saluzzo<sup>2</sup>, Benedetta Montagna<sup>1</sup>, Chiara Picchi<sup>1</sup>, Francesco Salerno<sup>3</sup>

<sup>1</sup>*Oncology and Hepatology Unit, Institute of Care Città di Pavia, Pavia, Italy*

<sup>2</sup>*Interventional Radiology, Institute of Care Città di Pavia, Sandonato Group, Pavia, Italy*

<sup>3</sup>*Internal Medicine Unit, IRCCS, Policlinico San Donato, Milano, Italy*

**Received:** May 23, 2016

**Accepted:** June 21, 2016

**Online Published:** June 26, 2016

**DOI:** 10.5430/crim.v3n3p52

**URL:** <http://dx.doi.org/10.5430/crim.v3n3p52>

## ABSTRACT

Ectopic varices is an uncommon cause of gastrointestinal bleeding. We reported a case of severe bleeding due to jejunal varices which arose as a complication of extrahepatic portal vein thrombosis. The patient was successfully treated by portal vein recanalization and percutaneous transhepatic stent placement.

**Key Words:** Gastrointestinal bleeding, Portal vein thrombosis, Partial splenic embolization, Jejunal varicose vein, Portal vein recanalization

## 1. INTRODUCTION

Ectopic varices due to portal vein thrombosis are an uncommon complication sometimes occurring after abdominal surgery complicated by portal vein obstruction.<sup>[1]</sup> Bleeding from such ectopic varices can be difficult to be diagnosed and managed.<sup>[2]</sup> Here, we report a case of severe bleeding from jejunal varices occurring four months after right liver lobectomy and hepatico-jejunostomy.

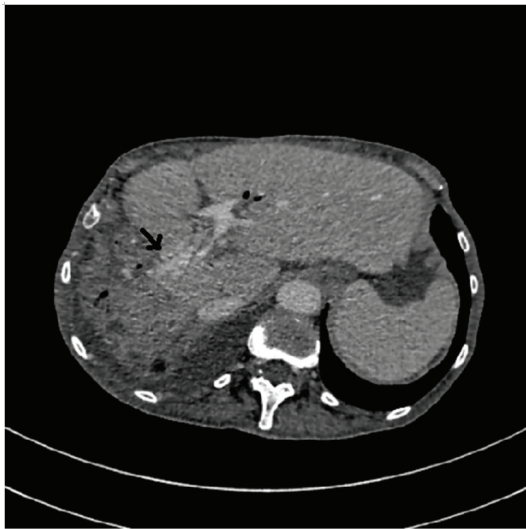
## 2. CASE PRESENTATION

A 74-year-old white woman was admitted to our hospital because of melena. Four months earlier she had undergone a right liver lobectomy and left hepatico-jejunostomy (Roux-en-Y fashion) with portal vein reconstruction for an extrahepatic bile duct carcinoma. A week before admission to our hospital she complained of recurring episodes of hema-

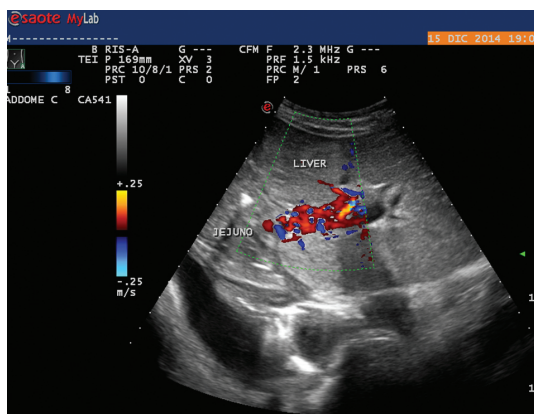
tochezia. On examination she appeared pale, the blood pressure was 90/50 mmHg and the pulse 110 beats per minute; the temperature and respiratory rate were normal. She complained of abdominal discomfort and deep asthenia. The blood haemoglobin level and hematocrit were 7.1 g/dl and 21.5% respectively. Upper gastrointestinal endoscopy excluded either oesophageal and gastric bleeding varices or ulcerous lesions. Colonoscopy was also normal up to the caecum except for the presence of blood clots in the lumen. Small-bowel endoscopy also showed clots in the jejunum but only below the jejuno-jejunostomy (Roux-en-Y). Abdominal color-Doppler ultrasound and angio-CT scan disclosed the complete obstruction of the surgical end-to-end portal vein anastomosis; the main portal vein was patent and also the superior mesenteric vein whose flow was reversed just before the junction. The intra-hepatic branches of left portal vein

\*Correspondence: Guido Poggi; Email: [guidopoggi64@gmail.com](mailto:guidopoggi64@gmail.com); Address: Oncology and Hepatology Unit, Institute of Care Città di Pavia, Pavia 27100, Italy

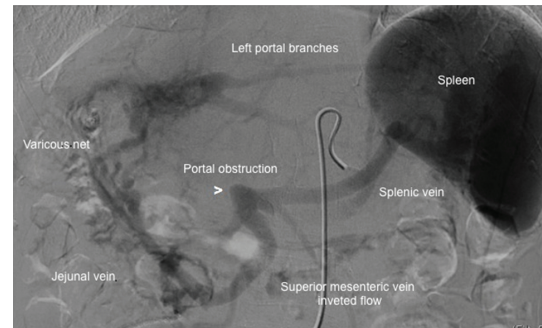
were patent and apparently were receiving all their blood flow from a newly developed veno-venous anastomosis (with varicous net) on the side of hepatic-jejunosomy (see Figures 1 and 2). We performed a selective contrast angiography of the celiac artery and the superior mesenteric artery. Venous phase clearly showed portal vein occlusion at the origin; flow was stolen by a large jejunal vein draining into a net of dilated veins at the level of hepatic jejunosomy (see Figure 3) and connected with left intrahepatic portal system; no signs of active bleeding were found. In order to reduce venous flow into the varicous net, an Amplatzer Plug was positioned into the proximal splenic artery. This maneuver caused a prompt flow reduction, but unfortunately, during the next days, the patient still showed hematochezia and severe anemia.



**Figure 1.** Portal-phase of abdominal CT scan shows a veno-venous anastomosis on the side of hepatico-jejunosomy (black arrow)



**Figure 2.** Color-doppler US of the liver shows a net of venous vessels at the level of hepatico-jejunosomy



**Figure 3.** Venous phase during celiac artery angiography shows portal obstruction (white arrowhead) and a net of dilated veins connected with left intrahepatic portal vein branches

Therefore, we planned an endovascular portal vein recanalization by a percutaneous and transhepatic approach. US-guided puncture of a small peripheral left portal branch was performed with a 20 gauge Chiba needle. After 0.018" wire replacement a 45 cm length 8-French sheath was introduced into the main left portal branch. Portal vein occlusion was successfully recanalized with 0.035" hydrophilic wire and a 4 French vertebral catheter. A dilatation with 5 mm balloon of the occluded segment was performed in order to cross the obstruction with the 8 F introducer sheath. A stent graft Viabhan™ 8 mm × 100 mm was positioned with its proximal end at the level of left main portal branch and its distal end exactly at the origin of portal vein and it was post-dilated at 8 mm. Hepatopetal flow was restored with varicous net immediate detension. Low dose of low molecular weight heparin was administrated before and after the procedure. No further blood transfusions were required. After sixteen months patient was well and her hemoglobin value was 13.1 g/dl. Abdominal contrast-enhanced CT scan confirmed pathological varicous veins disappearance and portal vein patency.

### 3. DISCUSSION

Extrahepatic portal vein stenosis or obstruction could be the consequence of thrombophlebitis, compression or direct tumor invasion. Other causes are congenital abnormalities, thrombophilic disorders either congenital or acquired, portal stasis associated with hepatic cirrhosis or adhesions from previous surgery. The resulting portal hypertension induces collateral vessel formation and varices appearance. Gastroesophageal varices at the level of the junction are the most common and they are usually clinically relevant, but ectopic varices can be observed along the all gastrointestinal tract from duodenum to the rectum; prior abdominal surgery predisposes ectopic varices development at the sites of tissue adhesion.<sup>[1,2]</sup>

While the endoscopic variceal band ligation or sclerother-

apy are the usual treatments of oesophageal varices, the best treatment of jejunal varices has still not been determined and many different treatments have been reported. Overall, these treatments can be grouped into two categories: those designed to reduce portal hypertension, such as portal venous dilatation and stenting, splenectomy and surgical or endovascular shunts and those aimed at the obliteration of varices such as endoscopic therapy, re-anastomosis, surgical ligation or embolization.<sup>[3-7]</sup> While the aim of the first group treatments is reducing portal hypertension, which is the leading cause of the varicose veins occurrence and bleeding, the purpose of the second group is to immediately stop the bleeding. Obviously the direct obliteration of varices implies a risk of recurrence, as it does not solve the underlying cause. Conversely, in case of portal decompression, the main risks are either the hepatic encephalopathy or the shunt thrombosis.

In our patient we planned a portal vein recanalization and stenting because splanchnic blood flow was all drained through hepatico-jejunosomy varicous and hypertensive venous net. Many studies showed that percutaneous portal vein stenting procedure is effective and safe. Concern about risks

of migration, misplacement or stent thrombosis are overestimated. Kim *et al.* evaluated efficacy and safety of stent placement in the management of portal venous stenosis after curative surgery for both pancreatic and biliary neoplasm.<sup>[8]</sup> They found excellent stent patency rate of 89% and clinical efficacy during a mean follow-up period of 23.5 months. Acute portal vein thrombosis occurred in only one patient 8 days after the procedure. To prevent stent thrombosis some Authors reported the use of anticoagulation therapy during and after stent placement even if there is still not consensus on when to start therapy, which anticoagulant use and for how long patients should be treated.<sup>[9]</sup> In our patient we prefer to use prophylactic dose of subcutaneous low-molecular weight heparin for the first three months after the procedure and warfarin subsequently.

In conclusion this case emphasizes that the diagnosis and treatment of bleeding jejunal varices remains a clinical challenge. In this setting the partial splenic embolization has not prove to be effective while the percutaneous transhepatic stenting is confirmed to be a safe and effective treatment.

## REFERENCES

- [1] Hamlyn AN, Morris JS, Lunzer MR, *et al.* Portal hypertension with varices in unusual sites. *Lancet.* 1974; 2: 1531-4. [http://dx.doi.org/10.1016/S0140-6736\(74\)90283-9](http://dx.doi.org/10.1016/S0140-6736(74)90283-9)
- [2] Paquet KJ, Lazar A, Bickhart J. Massive and recurrent gastrointestinal hemorrhage due to jejunal varices in an afferent loop-diagnosis and management. *Hepato-gastroenterology.* 1994; 41: 276-277. PMID:7959553
- [3] Harville LE, Rivera FJ, Palmaz JC, *et al.* Variceal hemorrhage associated with portal vein thrombosis: treatment with a unique portal venous stent. *Surgery.* 1992; 111: 585-90. PMID:1598680
- [4] Johnson DBS, Narasimhan D. Successful treatment of bleeding jejunal varices using mesoportal recanalization and stent placement: report of a case and review of the literature. *Clin Radiol.* 1997; 52: 562-565. [http://dx.doi.org/10.1016/S0009-9260\(97\)80339-X](http://dx.doi.org/10.1016/S0009-9260(97)80339-X)
- [5] Dagenais M, Pomier-Layrargues G, Dufresne M, *et al.* Transhepatic portal vein stenting for treatment of ruptured duodenopancreatic varices in a patient with chronic pancreatitis. *Surgery.* 1994; 115: 669-673. PMID:8197556
- [6] Yoshioka T, Uchida H, Kitano S, *et al.* Long-term palliative treatment of hepatocellular carcinoma extending into the portal vein and bile duct by chemoembolization and metallic stenting. *Cardiovasc Intervent Radiol.* 1997; 20: 390-393. PMID:9271653 <http://dx.doi.org/10.1007/s002709900175>
- [7] Watanabe Y, Sato M, Abe Y, *et al.* Metallic stents for low invasive recanalization of the portal veins with cancerous invasion - first case report. *Hepato-gastroenterology.* 1998; 45: 551-553. PMID:9638449
- [8] Kim KR, Ko GY, Sung KB, *et al.* Percutaneous transhepatic stent placement in the management of portal venous stenosis after curative surgery for pancreatic and biliary neoplasms. *AJR Am J Roentgenol.* 2011; 196: 446-50. PMID:21427310 <http://dx.doi.org/10.2214/AJR.10.5274>
- [9] Yamakado K, Nakatsuka A, Tanaka N, *et al.* Malignant portale venous obstruction treated by stent placement: significant factors affecting patency. *J Vasc Interv Radiol.* 2001; 12: 1407-1415. [http://dx.doi.org/10.1016/S1051-0443\(07\)61699-6](http://dx.doi.org/10.1016/S1051-0443(07)61699-6)