

CASE REPORTS

All trans retinoic acid induced hypercalcemia and diffuse alveolar hemorrhage in acute promyelocytic leukemia: Practical guidelines for diagnosis and treatment based on a case report and literature review

Tony Ibrahim¹, Giovanni Faddoul², Maria Baz³, Fadi Haddad³, Fadi Nasr¹

1. Hematology-Oncology department, Faculty of Medicine of the Saint Joseph University, Beirut, Lebanon. 2. Mount Sinai Health System, Medical Practice, New York, USA. 3. Internal Medicine department, Faculty of Medicine of the Saint Joseph University, Beirut, Lebanon

Correspondence: Tony Ibrahim. Address: Hematology-Oncology department, Faculty of Medicine of the Saint Joseph University, Damascus road B.P. 11-5076, Riad El-Solh, 1107 2180, Beirut, Lebanon. Email: ibrahim_toni@hotmail.com

Received: September 14, 2015

Accepted: October 7, 2015

Online Published: October 25, 2015

DOI: 10.5430/crim.v2n4p64

URL: <http://dx.doi.org/10.5430/crim.v2n4p64>

Abstract

As experience with all trans-retinoic acid (ATRA) in acute promyelocytic leukemia (APL) has grown, its' toxicity profile became more extensive. We initially present a case of APL in which hypercalcemia and Diffuse Alveolar Hemorrhage occurred simultaneously after introduction of ATRA, followed by a systematic review of the literature. A comity of 5 specialists analyzed and discussed each reported case on the basis of the CAse REport (CARE) guidelines. Level III guides were suggested for diagnosis and treatment.

Keywords

All trans-retinoic acid, Hypercalcemia, Diffuse alveolar hemorrhage, Acute pro-myelocytic leukemia

1 Introduction

Although all trans-retinoic acid (ATRA) has been a breakthrough in the treatment of acute promyelocytic leukemia (APL) since 1988, number of complications appeared and were considered to be related to the treatment itself^[1-8]. The most dreadful was called retinoic acid syndrome (RAS), also known as differentiation syndrome, which was believed to be due to maturation of blast cells. It occurs in approximately one fourth of patients and comprises a variety of symptoms including fever, dyspnea and hypotension. Hopefully, this syndrome has shown its mortality drop from 30% to less than 10% in the last years due to early recognition and treatment^[9, 10]. As experience with this drug continued to grow, however, the toxicity profile became more extensive and side effects, like hypercalcemia and diffuse alveolar hemorrhage (DAH), considered extremely rare in the beginning, were more reported lately in the literature^[11, 12]. Hence, practical guides are needed in order to prevent delay in diagnosis and ensure appropriate treatment initiation^[10, 13, 14]. In this article we present initially a case of APL in which hypercalcemia and DAH occurred simultaneously after ATRA therapy, and ultimately suggest practical level III guides based on systematic literature review and expert discussion.

2 Case history

A 75-year-old female patient was admitted to our hematology department after being diagnosed with high risk APL. Her medical history was unremarkable except for coronary artery bypass grafting 3 years ago with normal cardiac function. She did not smoke cigarette nor consumed alcohol. She was on aspirin, candesartan and atorvastatin. On physical exam, she had fever (temperature 39 degree Celsius) and bruising was found on her right arm and left thigh. The remaining of the physical exam was unremarkable. Initial labs showed a hemoglobin of 9.1 g/dl, whole blood count of 15,200/mm³ with 84% blast cells, and 30,000 platelets/mm³ in peripheral blood. The remaining blood labs were in normal ranges (including creatinine, corrected calcium, phosphorus, uric acid, electrolytes, and liver function tests) except for an LDH of 850 I.U (normal lab 300-500), a prothrombin time (PT) of 45% (international normalized ratio-INR of 1.75), high D-Dimers (DD) 20 microgram/ml but normal fibrinogen and partial thromboplastin time. Bone marrow aspirate confirmed the invasion of medulla by blast cells with Auer rods and a t15:17 was detected on cytogenetic study.

Induction treatment was initiated with ATRA p.o (45 mg/kg divided in two doses) on day 1 along with Idarubicin 12 mg/m² iv on days 2, 4, 6 and 8. Hydration with 3 liters normal saline along with allopurinol p.o. 300 mg qd were started on day 1 as well as red blood cells, fresh frozen plasma (FFP) and platelets transfusions aiming at preventing tumor lysis syndrome, maintaining hemoglobin concentration above 8 g/dl, maintaining PT, fibrinogen, DD in normal ranges and platelets above 50,000, respectively. Treatment of febrile neutropenia was started using Piperacilline-Tazobactam 4.5 g iv q6h along with trimethoprim-sulfamethoxazole (160 mg/800 mg p.o 3 times per week), acyclovir (400 mg p.o bid) and fluconazole 400 mg iv qd for pneumocystis, herpes and invasive fungal infection prophylaxis respectively.

On day 3 she started complaining of dyspnea with desaturation and chest X-ray showed diffuse bilateral infiltrates. The diagnosis of RAS was adopted, hence dexamethasone 10 mg iv qd was started and ATRA was continued. She had transient recovery of her symptoms on days 4, 5 and 6 along with radiographic amelioration. Corrected serum calcium concentration had risen from a baseline of 2.1 mmol/l on day 2, to 3 mmol/l on day 6 (normal lab 1.9-2.3 mmol/l) even though she had FFP infusions every 6 hours to maintain INR in normal range since day 1. Serum parathyroid hormone (PTH) and vitamin D were in normal ranges (PTH = 26.2 pg/ml with normal lab ranging between 6 and 36; vitamin D = 22 ng/ml normal lab 30-80). Furosemide (40 mg IV/d) was added.

On day 7 she developed worsening of her respiratory symptoms and progression of pulmonary infiltrates was shown on chest radiography. ATRA was stopped and she was transferred to the intensive care unit (ICU) requiring noninvasive mechanical ventilation which was unsuccessful to prevent intubation and mechanical ventilation on day 9. She remained afebrile all this time. Bronchoscopy was performed on day 10 showing hemorrhagic fluid on bronchoalveolar lavage with hemosiderin-laden macrophages on cytology studies, elements in favor of diffuse alveolar hemorrhage. Cultures were sterile. No biopsy was done. Dexamethasone was risen to 20 mg iv qd.

On subsequent days her respiratory needs were getting better along with normalization of serum calcium concentration on day 12. But on day 14 she developed febrile neutropenia with septic shock. *Pseudomonas aeruginosa* was isolated from mucus and blood cultures. Despite best care she died on day 18.

3 Methodology and results

A systematic literature review was done by the authors in the following data bases: Pubmed, Embase and Cochrane Library using the combination of mesh terms, one from each of the following groups: Group A-“all trans-retinoic acid”, “ATRA”; Group B-“acute leukemia”, “acute myeloid leukemia”, “acute myeloblastic leukemia”, “AML”, “acute promyelocytic leukemia”, “APL”; Group C-“hypercalcemia”, “calcium”; Group D-“diffuse alveolar hemorrhage”, “DAH”, “pulmonary hemorrhage”. The order of combination was: A and B and C (example: “ATRA” and “APL” and “hypercalcemia”), or A and B and D, or A and B and C and D. In total, nine articles presenting 8 reported cases of

hypercalcemia associated with ATRA use in APL were found (see Table 1), as well as three articles presenting 6 reported cases of DAH (see Table 2). An article reporting the occurrence of hypercalcemia associated with ATRA in multiple myeloma was not included in the analysis [15]. A second non available article was excluded from this review [16]. We did not find any case reporting the simultaneous occurrence of hypercalcemia and DAH in APL as in our patient. Figure 1 illustrates the findings of the literature review.

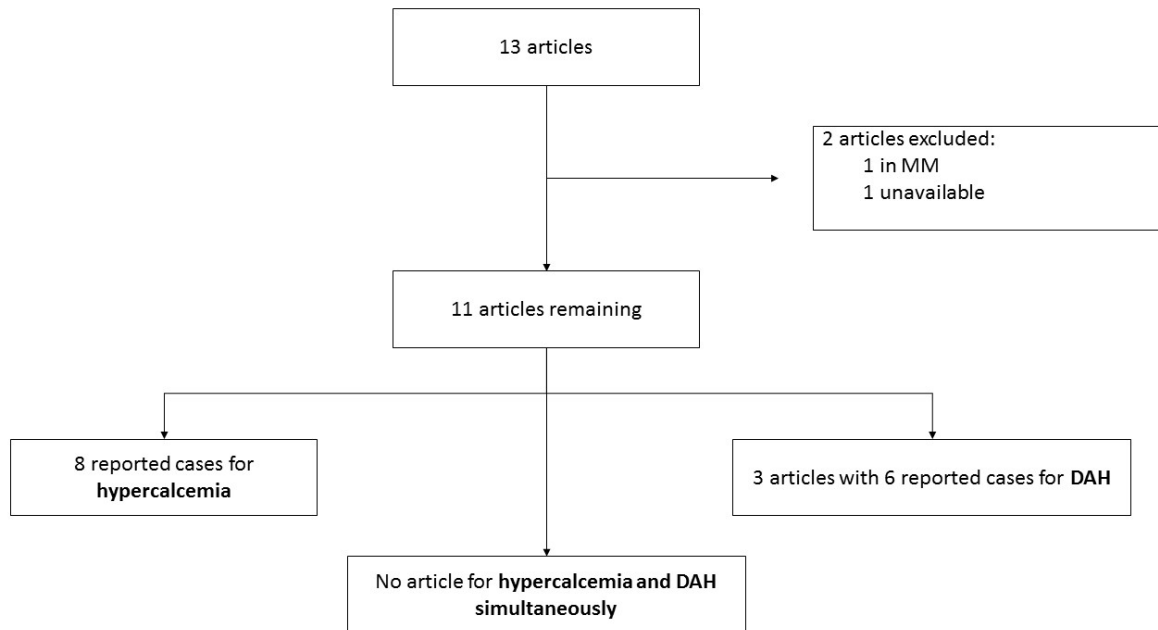


Figure 1. Summary of the literature review result

Table 1. Summary of reports on alveolar hemorrhage associated with ATRA treatment in PML

| First author and year of publication (ref.) | Age/Sex | Treatment protocol | Time to ATRA syndrome/AH | Treatment strategy | Outcome (Time till improvement if applicable) |
|---|---------------|---|--------------------------|---|---|
| Nicols M <i>et al.</i> 1998 [12] | 18 y.o Female | ATRA + DEXA 10 mg bid then qd + Hydroxyurea | 15/15† | 1 g methylprednisolone IV/d for 3 days then DEXA IV 10 mg bid | Improved (3 days from initiation of MP) |
| Raanani P <i>et al.</i> 2000 [31] | 36 y.o male | ATRA then Dauno + Ara-C | 20/20† | DEXA IV 10 mg BID + ↑ ATRA | Improved (22 days from ↓ ATRA) |
| | 59 y.o male | ATRA then Dauno + Ara-C ‡ | 6/7* | DEXA IV 10 mg BID + ↑ ATRA | Died - septic shock |
| Jun J <i>et al.</i> 2002 [14] | 23 y.o female | ATRA then Ida + Ara-C | 12/16* | ↑ ATRA + prednisolone 20-40 mg/day, divided doses | Improved (not available) |
| | 40 y.o female | ATRA then Ida + Ara-C | 2/2† | ↑ ATRA + prednisolone 20-40 mg/day, divided doses | Died – RF |
| | 23 y.o female | ATRA then Ida + Ara-C | Not available/7* | ↑ ATRA + prednisolone 20-40 mg/day, divided doses | Died – RF |

Note. AH: alveolar hemorrhage; Ara-C: cytarabine; ATRA: all trans retinoic acid; DEXA: dexamethasone; Ida: idarubicine; RF: respiratory failure.

*AH developed during the course of ATRA syndrome.

† AH developed concomitant with ATRA syndrome.

‡ chemotherapy not specified but presumed to be the same as the first case in the article.

↑ stop.

Table 2. Summary of reports on hypercalcemia associated with ATRA treatment in PML

| | Age (years old)/sex | Treatment protocol | Time to ↑Ca.† Max (Ca). Σ. | Treatment (outcome) | Subsequent therapy for PML (outcome) | Conclusion And Hypothesis |
|--------------------------------------|---------------------|--|--|---|---|---|
| Akiyama H <i>et al.</i> 1992 [20] | 19/male | Dauno + Ara-C then ATRA 40 mg/m ² /day | D 57 (11.3 mg/dl) n/a | ↑ ATRA (Ca ↓ within 20 d) | n/a | - Low PTH; Low Vit D |
| Sakakibara M <i>et al.</i> 1993 [22] | 14/ female | Induction: MIT + BHAC+ Pdl + 6-MP then ATRA 45 mg/m ² /day | D 19 (18.7 mg/dl) Fatigue Headache ARF Arrhythmia | NS+ ↑ ATRA for 8 days (Ca ↓ within 2 d) | ATRA 25 mg/m ² /d (No ↑ Ca CR at this dose) | ↑ bone turn over related to ATRA |
| Suzumiya J <i>et al.</i> 1994 [24] | 52/male | Induction: ATRA 45 mg/m ² /day (after third recurrence) | D 6 (14.0 mg/dl) No symptoms | NS +Fur.: (No Response) Then Prednisone + elcatonine (No Response) Then ↑ ATRA: (Ca ↓ within 6 d) | ATRA 12.5 mg/m ² (Ca ↑ again [prednisolone + elcatonine] No CR at this dose) | Unclear mechanism-related to ATRA |
| Lemez P. 1995 [21] | 44/female | Induction: Dauno + Ara-C then ATRA 45 mg/m ² /day | D 32 (13.2 mg/dl) No symptoms | NS + F + ↓ ATRA 27 mg/m ² /d (Ca ↓ within 5 d) | ATRA 27 mg/m ² /d (No ↑ Ca CR at this dose) | No hypothesis mentioned about the mechanism |
| Sakamoto O <i>et al.</i> 2001 [23] | 11/male | ATRA 47 mg/m ² /day reduced to 39 mg/m ² /d | D 25 (12.7 mg/dl) Headache Nausea ARF | NS hydration (No Response) then ↑ ATRA (Ca ↓ within 7 d) | 2 nd course same dose: (Ca ↑ again pamidronate: 30 mg iv → Ca ↓ within 2 d, without ↓ ATRA) | ↑ bone resorption |
| Bennett M 2005 [27] | 24/female | Induction: Dauno + Ara-C + ATRA 45 mg/m ² /d + voriconazole 200 mg q12h** | D 13‡ (14.2 mg/dl) No symptoms | ↑ ATRA + pamidronate 90mg iv (Hypocalcemia) | ATRA same dose after Voriconazole cessation (No ↑ Ca) | Effect of voriconazol on CYP 450 and ↑ serum ATRA |
| Hisatake J <i>et al.</i> 2008 [13] | 24/male | Induction: ATRA then Idarubicin + Ara-C + fosfluconazole | D 30 n/a Nausea vomiting fatigue | ↑ ATRA + prednisolone + elcatonin (Ca ↓ within 5 d) | n/a | Effect fosfluconazole on CYP 450 and ↑ serum ATRA |
| Cordoba R <i>et al.</i> 2008 [28] | 38/male | Induction: ATRA 45 mg/m ² /d + Ida 12 + Itraconazole 200 mg BID (prophylaxis) | 3 rd course Maintenance: 14.7 mg/dl ARF | NS + furosemide+ ↑ ATRA → (Ca ↓ within 4 d) | 4 th course maintenance: (↑ Ca treated with Zoledronic acid 4 mg iv), Then ATRA same dose + Prophylactic Zoledronic acid (4 mg IV) on day +1 of subsequent consolidation (No ↑ Ca) | Effect of Itraconazol on CYP 450 and ↑ serum ATRA |

6-MP: 6 mercaptopurine; Ara-C: cytarabine; ARF: acute renal failure; ATRA: all-trans-retinoic acid; BHAC: enocitabin; Ca ↑: hypercalcemia.; Ca ↓: calcium normalized; D: day; Dauno: Daunorubicine; F: furosemide; Max (Ca): maximum plasma corrected calcium concentration; MIT: mitoxantrone; n/a: not applicable or not mentioned; NS: normal saline; Pdl: prednisolone; PTH: parathyroid hormone; Σ: symptoms; † stop.

† time from ATRA introduction.

‡ time from ATRA + Voriconazole use.

** treatment for aspergillosis.

A committee of 5 specialists (two in hematology-oncology [I. T.; N. F.], one in nephrology [F.G], one in infectious diseases [H. F.], and finally one in internal medicine [B. M.]) analyzed and discussed each case listed in Tables 1 and 2 on

the basis of the CAse REport (CARE) guidelines^[17]. The following four questions were answered for each article included in the analysis: (1) Did the cited complication appeared only after ATRA use? (2) Have the author listed all the drugs used before or simultaneously with ATRA? (3) What diagnostic tests have been performed and did the results affect therapeutic strategy? (4) What were the treatment options used and what was the outcome for each one? Practical guidelines were then written for each complication.

4 Discussion

4.1 Hypercalcemia

Retinoic acid was reported to induce hypercalcemia in phase I studies at higher doses (more than 60 mg/m²/d versus the standard dose 45 mg/m²/d)^[18, 19]. This complication was occasionally published as case reports before 2001, and the majority (5 out of 6) were from Asian origin^[16, 20-24]. The pathophysiology of ATRA induced hypercalcemia was unclear. Although, some speculated that it would be due to an increase in parathyroid-hormone-related protein (PTH-rp)^[24], others found evidence of accelerated bone turn over not related to PTH neither PTH-rp nor vitamin D^[16, 20, 22, 23]. All authors, however, agreed on the causality of ATRA. After the introduction ofazole drugs for fungal prophylaxis in the induction and consolidation phases of acute leukemias^[25, 26], more reports have described hypercalcemia induced by the interaction between ATRA andazole (voriconazole, fosfluconazole and itraconazole). It was speculated that the later class of drugs increased serum ATRA concentration and toxicity by inhibiting CYP 450 enzymes needed to its metabolism^[13, 27-29]. Conventional treatment with saline hydration and diuretics was not sufficient to normalize calcium levels, and subsequent therapies were needed. Table 1 summarizes the therapeutic strategies adopted. The question regarding the best strategy, stopping fungal prophylaxis^[30] or ATRA, is not answered yet. Proposed level III guides for hypercalcemia associated with ATRA in APL are listed below:

- In case of hypercalcemia developed after the introduction of ATRA, clinicians should first check possible drugs interaction.
- Searching for etiologies of hypercalcemia by means of specialized tests is not necessary if serum calcium was in normal range prior to the introduction of ATRA.
- In case of asymptomatic hypercalcemia, the authors suggest NS hydration, calcium restriction with or without furosemide as the first line therapy.
- In case of severe, symptomatic or unresolving hypercalcemia the authors suggest the use of iv bisphosphonate after evaluating the risks for osteonecrosis of the jaw (ONJ). Although the only bisphosphonate used with success in the literature was pamidronate 90 mg iv^[27], we believe that no biologic nor clinical reasons would contraindicate the use of other drugs in the same category (*i.e.* zoledronic acid).
- Close calcium monitoring is warranted after bisphosphonate to detect and treat hypocalcemia especially when FFP is concomitantly infused for hemorrhagic prophylaxis.
- There is no evidence supporting the use of prophylactic iv bisphosphonate during consolidation in patients developing hypercalcemia during induction; it should be restricted however to cases of hypercalcemia recurring after reintroduction of ATRA.
- There are no proven clinical nor biologic data suggesting a possible role for corticoids in ATRA induced hypercalcemia.
- Little proof exists for the use of calcitonine derivatives in the prevention or treatment of ATRA induced hypercalcemia unless bisphosphonate are contraindicated.

- Given the efficacy of ATRA in promoting complete remission (CR) and the need for azole in preventing invasive fungal infections, the authors suggest continuing both drugs unless hypercalcemia becomes refractory to the above treatments.

4.2 Diffuse alveolar hemorrhage

In the pre-ATRA era, pulmonary bleeding in patients with APL was mostly due to disseminated intravascular coagulation^[31]. Although pulmonary distress is the most common symptom in RAS^[10], DAH due to ATRA is quite rare limited to six case reports in the literature (see Table 2)^[12, 14, 31]. Like RAS, maturing myeloid cells seem to invade lung parenchyma and promote local inflammation and leakage of red blood cells in the alveolar space, hallmarks of pulmonary hemorrhage, without loss of the capillary basement membrane integrity^[10, 12]. The reason why pulmonary capillaritis developed rarely following ATRA use was unknown and no immune complex deposition were found on immunofluorescence when biopsies were done^[12]. One proposed explanation would be related to a possible direct effect of ATRA on capillary endothelium allowing red blood cells to leak into the alveolar space^[10, 12]. The authors of the six reports initially debated whether DAH was indeed a manifestation of the basic disease, or an adverse event related to the treatment itself or secondary to other conditions, which caused delay in treatment initiation^[12, 14, 31]. On the other hand no factor was found to predict the development pulmonary capillaritis following ATRA use, and no single symptom (*i.e.* progressive hemoptysis) or radiologic finding (*i.e.* diffuse bilateral ground glass opacities on thoracic CT) could confirm this diagnosis. It was possible only when bronchoscopy and biopsy were performed, complicating further the picture in this group of patients with an increased risk of procedure related morbidity and mortality^[12]. Finally, questions regarding the best treatment strategy in these cases and whether ATRA should be reintroduced in subsequent treatments are not answered yet. Listed below are Level III guidelines proposed by the authors.

Concerning the diagnosis and treatment of DAH associated with ATRA in APL:

- The authors suggest that physicians should have a high index of suspicion of ATRA induced DAH in front the clinical and diagnostic findings below:
 - Hemoptysis developed after initiation of ATRA without any sign of hemorrhage in other tissues, and especially if DIC is found to be resolving on lab tests.
 - Progression of respiratory distress despite appropriate treatment (corticosteroids and ATRA cessation).
 - Diffusely bilateral and poorly defined nodules, ground-glass opacity, and consolidation seen on chest x-ray and thoracic CT.
- The authors suggest not to perform advanced etiologic tests (*i.e.* serologic tests for capillaritis) because they would not change the therapeutic strategy but could delay treatment initiation.
- The authors suggest that thoracic VCT would be performed to rule out other etiologies of respiratory distress (*i.e.* Pulmonary Embolism) rather than to confirm DAH. It would show poorly defined centrilobular nodules and diffuse ground-glass opacity with or without interlobular septal thickening.
- Bronchoscopy should be performed only if infectious etiologies are suspected, rather than to confirm DAH. Three subsequent lavage tubes should be sent for cytological analysis and detection of hemosiderin label macrophage. These later could be of great diagnostic value especially if retrieved in growing percentage on subsequent tubes (an argument in favor of the alveolar origin of blood).
- The authors recommend against pulmonary biopsy.
- The authors recommend to stop ATRA and initiate iv corticoids; the most appropriate protocol was used by Nicols *et al.* and consisted of 1 g methylprednisolone/d IV for 3 days followed by dexamethasone 10 mg IV BID

or equivalent until resolution of respiratory failure^[12]. Treatment of DIC and thrombocytopenia should also be continued.

- The authors suggest that ATRA could be reintroduced in consolidation with steroids prophylaxis.
- Finally clinicians should always remember that septic choc especially from pulmonary origin remains the leading cause of death in these patients most likely to be intubated, and ventilator induced pneumonia should be highly suspected in case of re-deterioration.

5 Conclusion

In this article, we present the first case in the literature to demonstrate in one patient two rare but serious complications of ATRA use in APL, which are hypercalcemia and DAH. Because reversibility depends mainly on early recognition and prompt treatment initiation, the authors built on level III recommendations, based on literature review of case reports and expert discussion which could help physicians in their practice. Further studies are needed to improve knowledge of these two conditions and adapt treatment strategies. Finally the medical team should not be distracted from recognizing other more frequent conditions like septic choc.

Consent

Written informed consent was obtained from the patient's husband for publication of this Case report and any accompanying images. A copy of the written consent is available for review by the Editor-in-Chief of this journal.

Conflicts of interest to declare

None.

References

- [1] Doria-Rose VP, Harlan LC, Stevens J, *et al.* Treatment of de novo acute myeloid leukemia in the United States: a report from the Patterns of Care program. *Leuk Lymphoma*. 2014; 55: 2549-2555. PMID:24467221 <http://dx.doi.org/10.3109/10428194.2014.885517>
- [2] Drago MJ, Kim BS, Bennett D, *et al.* All-trans-retinoic acid-induced scrotal ulcers in a patient with acute promyelocytic leukemia. *Cutis*. 2013; 91: 246-247. PMID:23772430
- [3] Dreosti LM, Bezwoda W, Gunter K. Bone marrow necrosis following ALL-trans retinoic acid therapy for acute promyelocytic leukaemia. *Leuk Lymphoma*. 1994; 13: 353-356. PMID:8049655 <http://dx.doi.org/10.3109/10428199409056301>
- [4] Higuchi T, Yamazoe M, Yamaguchi N, *et al.* Hemophagocytic lymphohistiocytosis following differentiation syndrome in acute promyelocytic leukemia. *Leuk Lymphoma*. 2011; 52: 1601-1603. PMID:21657955 <http://dx.doi.org/10.3109/10428194.2011.574758>
- [5] Huang ME, Ye YC, Chen SR, *et al.* Use of all-trans retinoic acid in the treatment of acute promyelocytic leukemia. *Blood*. 1988; 72: 567-572. PMID:3165295
- [6] Tariq Z, Phinney RC, Mohamed I. A case of life-threatening retinoic acid syndrome and review of literature. *Am J Ther*. 2014; 21: 28-30. PMID:23567795 <http://dx.doi.org/10.1097/MJT.0b013e31822aece5>
- [7] Shih CH, Wu HB. All-trans retinoic acid-induced, life-threatening complete atrioventricular block. *J Chin Med Assoc*. 2015; 78: 316-319. PMID:25726499 <http://dx.doi.org/10.1016/j.jcma.2014.05.018>
- [8] Visani G, Manfroi S, Tosi P, *et al.* All-trans-retinoic acid and pseudotumor cerebri. *Leuk Lymphoma*. 1996; 23: 437-442. PMID:9031073 <http://dx.doi.org/10.3109/10428199609054851>
- [9] Cardinale L, Asteggiano F, Moretti F, *et al.* Pathophysiology, clinical features and radiological findings of differentiation syndrome/all-trans-retinoic acid syndrome. *World J Radiol*. 2014; 6: 583-588. PMID:25170395 <http://dx.doi.org/10.4329/wjr.v6.i8.583>
- [10] Weinberger SE, Larson RA. Differentiation (retinoic acid) syndrome. In: *Up To Date, Post TW (Ed), Up To Date, Waltham, MA.* (Accessed on June 25, 2015).

- [11] Hatake K, Uwai M, Ohtsuki T, *et al.* Rare but important adverse effects of all-trans retinoic acid in acute promyelocytic leukemia and their management. *Int J Hematol.* 1997; 66: 13-19. [http://dx.doi.org/10.1016/S0925-5710\(96\)00578-6](http://dx.doi.org/10.1016/S0925-5710(96)00578-6)
- [12] Nicolls MR, Terada LS, Tuder RM, *et al.* Diffuse alveolar hemorrhage with underlying pulmonary capillaritis in the retinoic acid syndrome. *Am J Respir Crit Care Med.* 1998; 158: 1302-1305. PMID:9769296 <http://dx.doi.org/10.1164/ajrccm.158.4.9709085>
- [13] Hisatake J, Shimozuma J. Hypercalcemia associated with all-trans retinoic acid therapy for microgranular type acute promyelocytic leukemia. *Rinsho Ketsueki.* 2008; 49: 408-412. PMID:18646608
- [14] Jung JI, Choi JE, Hahn ST, *et al.* Radiologic features of all-trans-retinoic acid syndrome. *AJR Am J Roentgenol.* 2002; 178: 475. PMID:11804921 <http://dx.doi.org/10.2214/ajr.178.2.1780475>
- [15] Niesvisky R, Siegel DS, Busquets X, *et al.* Hypercalcemia and increased serum interleukin-6 levels induced by all-trans retinoic acid in patients with myeloma. *Br J Haematol.* 1995; 89: 217-218. <http://dx.doi.org/10.1111/j.1365-2141.1995.tb08936.x>
- [16] Nagasawa M, Okawa H. All-trans retinoic acid induced hypercalcemia in a patient with acute promyelocytic leukemia: its relation to increased PTH-rP. *Int J Hematol.* 1994; 59: 143-412. PMID:8018908
- [17] Gagnier JJ, Kienle G, Altman DG, *et al.* The CARE guidelines: consensus-based clinical case reporting guideline development. *J Med Case Rep.* 2013; 7: 223. PMID:24228906 <http://dx.doi.org/10.1186/1752-1947-7-223>
- [18] Rizvi NA, Marshall JL, Ness E, *et al.* Phase I study of 9-cis-retinoic acid (ALRT1057 capsules) in adults with advanced cancer. *Clin Cancer Res.* 1998; 4: 1437-1442. PMID:9626460
- [19] Smith MA, Adamson PC, Balis FM, *et al.* Phase I and pharmacokinetic evaluation of all trans retinoic acid in pediatric patients with cancer. *J Clin Oncol.* 1992; 10: 1666-1673. PMID:1403049
- [20] Akiyama H, Nakamura N, Nagasaka S, *et al.* Hypercalcemia due to all-trans retinoic acid. *Lancet.* 1992; 339: 308-309. [http://dx.doi.org/10.1016/0140-6736\(92\)91382-1](http://dx.doi.org/10.1016/0140-6736(92)91382-1)
- [21] Lemez P. Hypercalcemia cause by all-trans retinoic acid (ATRA) treatment in a case of acute promyelocytic leukaemia was manageable after decreasing the ATRA dose to 27 mg/m²/ day. *Eur J Haematol.* 1995; 55: 275-276. PMID:7589349 <http://dx.doi.org/10.1111/j.1600-0609.1995.tb00276.x>
- [22] Sakakibara M, Ichikawa M, Amano Y, *et al.* Hypercalcemia associated with all-trans retinoic acid in the treatment of acute promyelocytic leukemia. *Leuk Res.* 1993; 17: 441-443. [http://dx.doi.org/10.1016/0145-2126\(93\)90100-Y](http://dx.doi.org/10.1016/0145-2126(93)90100-Y)
- [23] Sakamoto O, Yoshinari M, Rikiishi T, *et al.* Hypercalcemia due to all-trans retinoic acid therapy for acute promyelocytic leukemia: a case report of effective treatment with bisphosphonate. *Pediatr Int.* 2001; 43: 688-690. PMID:11737750 <http://dx.doi.org/10.1046/j.1442-200X.2001.01457.x>
- [24] Suzumiya J, Asahara F, Katakami H, *et al.* Hypercalcemia caused by all-trans retinoic acid treatment of acute promyelocytic leukaemia: case report. *Eur J Haematol.* 1994; 53: 126-127. PMID:8088385 <http://dx.doi.org/10.1111/j.1600-0609.1994.tb01878.x>
- [25] National Comprehensive Cancer Network. Acute Myeloid Leukemia (Version 1.2015). Available from: http://www.nccn.org/professionals/physician_gls/pdf/aml.pdf. Accessed June 28, 2015.
- [26] National Comprehensive Cancer Network. Prevention and Treatment of Cancer-Related Infections (Version 2.2015). Available from: http://www.nccn.org/professionals/physician_gls/pdf/infections.pdf. Accessed June 28, 2015.
- [27] Bennett MT, Sirrs S, Yeung JK, *et al.* Hypercalcemia due to all trans retinoic acid in the treatment of acute promyelocytic leukemia potentiated by voriconazole. *Leuk Lymphoma.* 2005; 46: 1829-1831. PMID:16263588
- [28] Cordoba R, Ramirez E, Lei SH, *et al.* Hypercalcemia due to an interaction of all-trans retinoic acid (ATRA) and itraconazole therapy for acute promyelocytic leukemia successfully treated with zoledronic acid. *Eur J Clin Pharmacol.* 2008; 64: 1031-1032. PMID:18584165 <http://dx.doi.org/10.1007/s00228-008-0517-3>
- [29] Ozpolat B, Mehta K, Lopez-Berestein G. Regulation of a highly specific retinoic acid-4-hydroxylase (CYP26A1) enzyme and all-trans-retinoic acid metabolism in human intestinal, liver, endothelial, and acute promyelocytic leukemia cells. *Leuk Lymphoma.* 2005; 46: 1497-1506. PMID:16194896 <http://dx.doi.org/10.1080/10428190500174737>
- [30] Ananda-Rajah MR, Grigg A, Downey MT, *et al.* Comparative clinical effectiveness of prophylactic voriconazole/posaconazole to fluconazole/itraconazole in patients with acute myeloid leukemia/myelodysplastic syndrome undergoing cytotoxic chemotherapy over a 12-year period. *Haematologica.* 2012; 97: 459-463. PMID:22058198 <http://dx.doi.org/10.3324/haematol.2011.051995>
- [31] Raanani P, Segal E, Levi I, *et al.* Diffuse alveolar hemorrhage in acute promyelocytic leukemia patients treated with ATRA-a manifestation of the basic disease or the treatment. *Leuk Lymphoma.* 2000; 37: 605-610. PMID:11042521 <http://dx.doi.org/10.3109/10428190009058513>