

CASE REPORTS

Intravenous leiomyomatosis with intracardiac extension: A case report with review of literature

Zhang Jin, Chen Xin, Lu Chengzhi, Wang Li

Department of Cardiology, Tianjin First Center Hospital, Tianjin, China

Correspondence: Chen Xin. Address: Department of Cardiology, Tianjin First Center Hospital, China.
Email: chenxin966@126.com

Received: May 31, 2015

Accepted: August 21, 2015

Online Published: September 14, 2015

DOI: 10.5430/crim.v2n4p22

URL: <http://dx.doi.org/10.5430/crim.v2n4p22>

Abstract

Intravenous leiomyomatosis (IVL) with intracardiac extension is a rare disease which has low diagnosis rate before operation. The article reported that a 46-year-old patient suffering from IVL with intracardiac extension was admitted in the Tianjin First Center Hospital on September 2, 2014. CT and PET-CT revealed bilateral ovarian cyst, pelvic nodules, bilateral pulmonary nodules, and a mass which existed from IVC to right ventricle (maximum area of 12 cm × 4 cm). The patient was diagnosed as IVL with intracardiac extension. Then the patient underwent myomectomy and bilateral adnexectomy successfully under the cardiopulmonary bypass. The patient recovered well after operation and received regular follow-up. Episode of tumor has not recurred during the follow-up. IVL doesn't have specific clinical manifestation, and its diagnosis mainly depends on the pathologic examination. Besides, imaging examination plays an important role in diagnosing it as a supplementary means. Operation is the main therapy. It is worth noting that complete resection is the key point. Total assessment for tumor extent is required before operation. Most of patients have good prognosis. However, it is possible to relapse, which lead to a necessary long-term follow-up.

Keywords

Intravenous leiomyomatosis, Intracardiac extension, Diagnosis, Treatment

1 Introduction

Intravenous leiomyomatosis (IVL) is a kind of rare benign mesodermal tumor of the uterus. Up to now, more than 200 cases have been reported in English literature. The growth pattern of IVL, which is entirely different from uterine fibroids, is very similar to malignant tumor. Mechanical obstruction will occur in 10%~30% of the patients due to the tumor involving the IVC and right cardiac cavity as well as lung. 0.1% of the patients suffer sudden death^[1, 2]. The lack of sufficient clinical awareness about such lesions usually puzzled clinician in diagnosis and treatment. The article reports a case of intravenous leiomyomatosis with intracardiac extension and reviews related literature.

2 Clinical summary

A 46-year-old female initially presented with chest tightness, shortness of breath and back pain while she didn't seek medical treatment. As worsening of symptoms accompanied by facial and leg edema, nausea and vomiting within 4 days,

the patient was admitted in the Tianjin First Center Hospital on September 2, 2014. Since she was ill, she didn't experience cough, hemoptysis, spontaneous pneumothorax, chylothorax, abdominal pain, hepatomegaly and ascites. Right heart failure was initially considered. We treated her with diuretic.

ECG revealed sinus bradycardia, ventricular premature beat. Echocardiography revealed right cardiac enlargement and a membranous mass in the right atrium. The mass protruded across the tricuspid valve throughout the cardiac cycle. Further coronary CTA revealed a mass which existed from IVC to right ventricle (maximum area of 12 cm × 4 cm) and pulmonary multiple nodules instead of numerous thin walled cysts within the lungs. Cardiac space-occupying lesions originating from the IVC was considered rather than Lymphangioliomyomatosis.

By enquiring medical history in detail again, the patient suffered from uterine fibroids and underwent hysterectomy 4 years before admission. Both of Enhanced CT and PET-CT revealed bilateral ovarian cyst, pelvic nodules, bilateral pulmonary nodules, and a mass originating from bilateral internal iliac vein through IVC to right ventricle (see Figure 1). Combining the medical history with imaging examination, intravenous leiomyomatosis with intracardiac extension was eventually diagnosed.

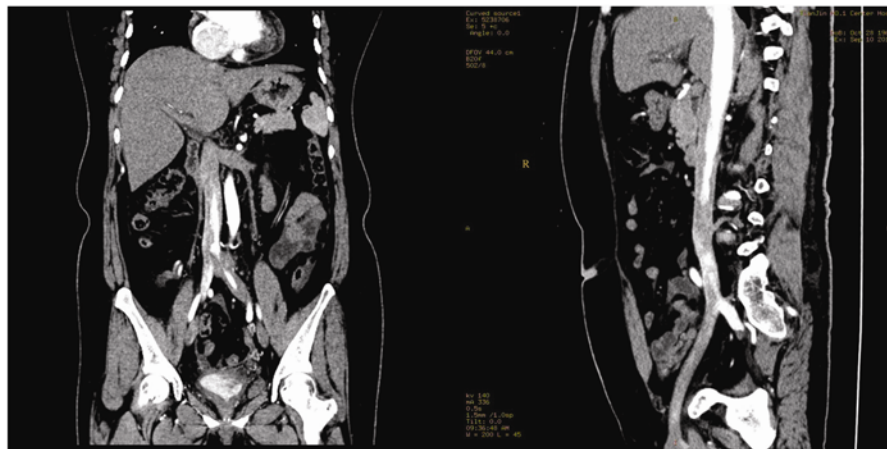


Figure 1. Enhanced CT scan revealed present of tumor in IVC

After diagnosed, we rushed her into surgery, which needs cooperation between various disciplines. Simultaneously, we performed the right heart and inferior vena cava neoplasm resection and bilateral adnexectomy. Cardiopulmonary bypass (CPB) was established by heart surgeons. On beating heart right atriotomy, a cystic structure (30 cm in length) was easily removed from the right heart chambers by slight traction, after a cystic IVC portion was sharply excised at a safe distance through an IVC incision on abdomen. On median laparotomy, gynecologist found absence of the uterus and bilateral ovarian cystic masses (left size of 5 cm × 4 cm × 3 cm, right size of 4 cm × 3 cm × 2 cm). Bilateral ovaries were excised. Weaning from CPB and rest of procedure were uneventful.

Finally, postoperative pathological diagnosis revealed intravenous leiomyomatosis. Pathology results showed that intravenous incanus streak mass (29 cm in length, 1.0 cm~2.8 cm in diameter) (see Figure 2), left ovarian serous cystadenoma with ovarian haemorrhage and hyperemia as well as right ovarian cortex nodular hyperplasia with leiomyomatosis in ovary portal.

The patient's postoperative course was complicated with poor wound healing of chest. Debridement suture was done once again. The patient had a good recovery. Clinical follow up of the patient after discharge revealed that there was no evidence of recurrence.

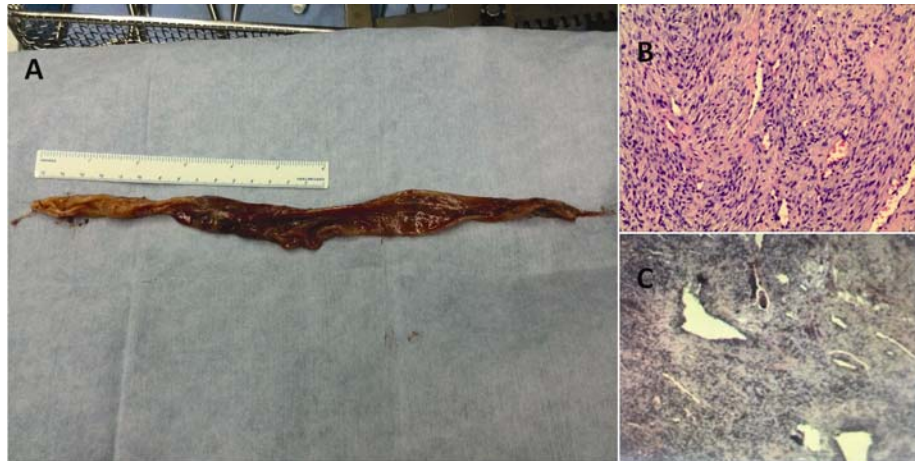


Figure 2. Pathological examination. A: giant tumor mass (29 cm in length, 1.0 cm~2.8 cm in diameter); B: hematoxylin-eosin staining; C: immunohistochemical staining

3 Discussion

In 1896, Birch-Hirschfeld reported firstly the clinical case which is related to the feature of IVL. The IVL with intracardiac extension was found firstly by Durck in 1907^[3]. Until 1975, this disease was defined as IVL by Norris and Parmley^[4]. It is described as a benign smooth muscle cell tumor that grows within the extrauterine venous channels without invading them.

The exact etiology of this neoplasm is not entirely known. Two contrasting theories have been presented, both of which have supporting evidence. Knauer proposed that the neoplasm arose from estrogen-induced smooth muscle cell proliferation in the wall of the uterine veins^[5]. While Sitzenfy declared that the neoplasm originated from uterine leiomyoma that invade the venous system^[6]. It is easy to remove tumor embolus from IVC of the patient in this case. Therefore, we tend to support the second theory. Dal and Quade found that the invasiveness of IVL may be closed related closely to the chromosome abnormalities^[7].

IVL is common disease among childbearing age women and is almost accompanied by uterine leiomyoma or a history of uterine leiomyoma, while the average age of diagnosis is 47 years old^[8]. The clinical manifestation is unspecific. Initial symptoms include vaginal bleeding, pelvic pain, fatigue, abdominal pain, ascites, peripheral edema, deep vein thrombosis, chest tightness, chest pain, palpitations, shortness of breath, syncope and so on, which are often associated with tumor growth. However, some patients may be asymptomatic.

The diagnosis of IVL depends mainly on the acquaintance of this disease. Clinically, IVL should be highly suspected in patients with uterine leiomyoma or hysterectomy combined with lower limb venous thrombosis, right heart dysfunction or right heart tumors. The patients with uterine leiomyoma and bilateral adnexa involvement also may suffer from IVL, especially when postoperative pathological findings reveal that worm-like streak tumor invade the removal tissues vascular.

In addition to symptoms and past medical history, imaging examination is necessary. Abdominal ultrasound and echocardiography can evaluate tumor size, scope and nature, assess risks by observing motion of right heart tumors, and differentiate diagnosis of other heart tumor^[9]. Enhanced CT can show the scope, size and the relationship between tumor and blood-vessel wall of the lesions in uterus, adnexa, vein and heart. It also can display the sharp of vascular lesions clearly and stereoscopically, assess the condition accurately, and monitor the growth and recurrence of tumor effectively and easily. It is used to be preferred examination for diagnosis of IVL. MRI has a good resolution for soft tissue, defines

the range of lesions clearly, and shows characteristics of tumor within vein ^[8]. PET-CT has obvious advantages in differentiating between benign lesions and malignant lesions.

The IVL with intracardiac extension needs to be distinguished from cardiac tumor such as atrial myxoma. However, it is very large probability that atrial myxoma exist in left atrial. When atrial myxoma is current, basic pathological change doesn't exist in the range of pelvic cavity, iliac vein and IVC. The IVL involving IVC needs to be differentiated from Budd-Chiari syndrome, IVC thrombus, kidney and liver cancer extending to IVC, IVC angioleiomyoma and IVC leiomyosarcomas. But these diseases mostly are not based on the uterine disease. Intravenous cancer embolus is originated from primary site of cancer. Abdominal ultrasound and inferior cavography are helpful to diagnosis. Besides, we also should distinguish between IVL and Lymphangioliomyomatosis. The clinical manifestation of Lymphangioliomyomatosis includes hemoptysis, spontaneous pneumothorax and chylothorax. Additionally, CT reveals numerous thin walled cysts within the lungs. There is not above feature in IVL. Consequently, it is not difficult to make a diagnosis.

IVL is slow-growing disease and has a good prognosis. However, tumor embolism can increase the risk of disease. Most patients are asymptomatic before neoplasms extend to right heart. The patients with neoplasm intracardiac extension could develop severe hemodynamic disorder. As a consequence, once the diagnosis is made, operation should be performed immediately. Total removal of intravenous leiomyomatosis is the key of successful treatment ^[10]. The optimum and safest strategy is a single or 2-stage procedure with an abdominal approach and subsequent thoracic approach. The abdominal stage should ensure complete extravascular tumor excision and control of the vascular entry site. The thoracic stage, preferably with short total CPB on the beating heart, should allow easy tumor withdrawal from the right cardiac chambers and IVC. The advantages of 2-stage strategy are shorter operative time and less risk of bleeding, as systemic heparinization mandatory for a single CPB. However, the risks of a second general anesthesia are actually avoided in a single procedure. Besides, the advantage of a single strategy is that the complications, such as tumor embolism, tumor progression and hemodynamic disorder, can be avoided between 2 major surgical procedures ^[11].

IVL can recur at any time. Whether or not to remove the tumor completely is related to recurrence. Recurrence rate of 30% from 7 months to 17 years follow-up has been reported. All these patients need long-term follow-up, and have to undergo another surgery if necessary ^[12].

In this case report, the patient was admitted due to the right heart failure. Echocardiography revealed right heart space-occupying lesions, so we initially considered heart tumor. However, it was very strange that we found the mass originated from IVC by other imaging examinations. Then we enquired the medical history repeatedly and knew that the patient had already undergone hysterectomy 4 years ago. After we reviewed a lot of literature, IVL was suspected in this patient. Finally, IVL was confirmed by PET-CT. Because IVL invaded right heart, sudden death would occur at any time. Consequently, we performed successfully a single stage right heart and inferior vena cava neoplasm resection and bilateral adnexectomy in time. Intravenous leiomyomatosis was revealed clearly by postoperative pathological diagnosis. The patient recovered and left hospital finally. Up to now, recurrence is not found during the follow-up. Closely follow-up is on-going.

In summary, IVL is benign smooth muscle cell tumor, but is considered clinically malignant. It is hard to diagnose the non-invasive neoplasms extending within venous at an early stage. IVL is metastatic and easy to recurrence. Operation is the primary therapeutic method. During long-term follow-up, when recurrence is observed, re-intervention is actually universally recommended to achieve long-term disease-free survival.

References

- [1] Elkington NM, Carlton M. Recurrent intravenous leiomyomatosis with extension up the inferior vena cava. *Aust N Z J Obstet Gynaecol.* 2005; 45: 167. PMID:15760324 <http://dx.doi.org/10.1111/j.1479-828X.2005.00355.x>

- [2] Esmaeilzadeh M, Tavakolli A, Safaei A. Recurrent intracardiac leiomyomatosis. *Can J Cardiol.* 2007; 23: 1085-1086. [http://dx.doi.org/10.1016/S0828-282X\(07\)70879-6](http://dx.doi.org/10.1016/S0828-282X(07)70879-6)
- [3] Harris LM, Karakousis CP. Intravenous leiomyomatosis with cardiac extension: tumor thrombectomy through an abdominal approach. *J Vasc Surg.* 2000; 31: 1046-1051. PMID:10805899 <http://dx.doi.org/10.1067/mva.2000.104601>
- [4] Norris HJ, Parmley T. Mesenchymal tumors of the uterus. V. Intravenous leiomyomatosis. A clinical and pathologic study of 14 cases. *Cancer.* 1975; 36: 2164-2178. <http://dx.doi.org/10.1002/cncr.2820360935>
- [5] Knauer E. Beitrag zur anatomie der uterusmyome. *Beitr Geburtsh Gynaekol.* 1903; 1: 695.
- [6] Sitzenfry A. Ueber venenmyome des uterus mit intravaskularem wachstum. *Z Geburtsh Gynaekol.* 1911; 68: 1-25.
- [7] Dal Cin P, Quade BJ, Neskey DM, *et al.* Intravenous leiomyomatosis is characterized by a der(14)t(12;14)(q15;q24). *Genes Chromosomes Cancer.* 2003; 36: 205-206. PMID:12508249 <http://dx.doi.org/10.1002/gcc.10159>
- [8] Lam PM, Lo KW, Yu MY, *et al.* Intravenous leiomyomatosis: two cases with different routes of tumor extension. *J Vasc Surg.* 2004; 39: 465-469. PMID:14743155 <http://dx.doi.org/10.1016/j.jvs.2003.08.012>
- [9] Baca Lopez FM, Martinez-Enriquez A, Castrejon-Aivar FJ, *et al.* Echocardiographic study of an intravenous leiomyoma: case report and review of the literature. *Echocardiography.* 2003; 20: 723-725. PMID:14641377 <http://dx.doi.org/10.1111/j.0742-2822.2003.02152.x>
- [10] Kocica MJ, Vranes MR, Kostic D, *et al.* Intravenous leiomyomatosis with extension to the heart: rare or underestimated? *J Thorac Cardiovasc Surg.* 2005; 130: 1724-1726. PMID:16308028 <http://dx.doi.org/10.1016/j.jtcvs.2005.08.021>
- [11] Dalainas I. Vascular smooth muscle tumors: review of the literature. *Int J Surg.* 2008; 6: 157-163. PMID:17531562 <http://dx.doi.org/10.1016/j.ijvsu.2007.03.004>
- [12] Castelli PCR, Piffaretti G, Tozzi M. Intravenous leiomyomatosis with right heart extension: successful two-stage surgical removal. *Ann Vasc Surg.* 2006; 20: 405-407. PMID:16583249 <http://dx.doi.org/10.1007/s10016-006-9024-0>