

## CASE REPORTS

# Chemotherapy induced inflammation due to cosmetic oils: A case report

Yasmin Hassoun<sup>1</sup>, Nabil J Khoury<sup>2</sup>, Hind Rafei<sup>3</sup>, Alain Mina<sup>3</sup>, Arafat Tfayli<sup>3</sup>

1. Department of Internal Medicine, University of Cincinnati, Cincinnati, USA. 2. Department of Diagnostic Radiology, American University of Beirut, Beirut, Lebanon. 3. Department of Internal Medicine, American University of Beirut, Beirut, Lebanon

**Correspondence:** Arafat Tfayli. Address: American University of Beirut Medical Center, Naef K; Basile Cancer Institute, PO Box 11-0236, Riad El-Solh 1107 2020, Lebanon. Email: at35@aub.edu.lb

**Received:** May 28, 2015

**Accepted:** June 26, 2015

**Online Published:** July 12, 2015

**DOI:** 10.5430/crim.v2n3p49

**URL:** <http://dx.doi.org/10.5430/crim.v2n3p49>

## Abstract

We report the case of a 24-year-old male diagnosed with Hodgkin's lymphoma who exhibited localized inflammation in oil-augmented muscles when exposed to chemotherapy. Such a reaction may be attributed to a drug-oil interaction. Our literature review indicates no prior reported cases on adverse events owed to drug-oil interactions.

## Keywords

Chemotherapy, Oil-injection, Drug interaction, Inflammation

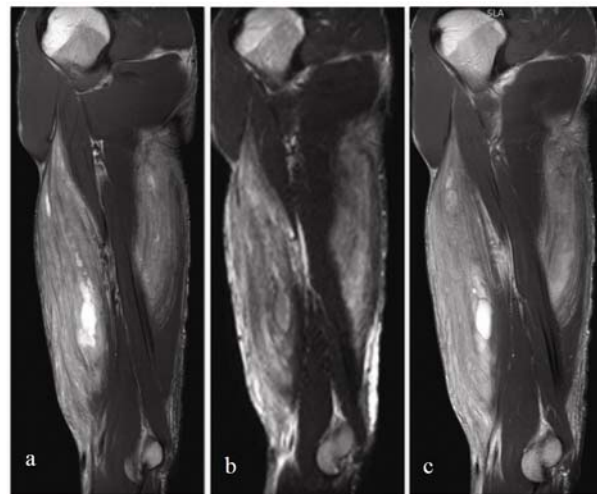
## 1 Introduction

We report the case of a male patient diagnosed with Hodgkin's lymphoma who exhibited localized inflammation in oil-augmented muscles when exposed to chemotherapy. To our knowledge the case is the first in the literature to report such a reaction.

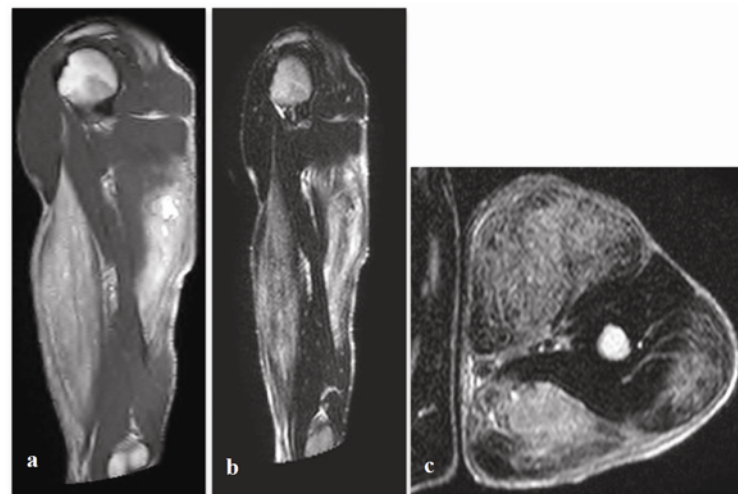
## 2 Case presentation

Our patient is a 24-year-old male diagnosed with Hodgkin's lymphoma and was receiving the ABVD (Adriamycin, Bleomycin, Vinblastine and Dacarbazine) chemotherapy regimen who presented with fever, pain, swelling and warmth of the biceps and triceps 10 days after receiving second cycle of chemotherapy. Physical examination was remarkable for hypertrophy of the triceps and biceps muscles bilaterally with signs of a local inflammatory reaction characterized by edema, redness, tenderness and hotness over both muscle groups, there was no limitation to motion. Review of the patient's social history revealed injection of an oily material into the biceps and triceps two years prior to the diagnosis of Hodgkin's lymphoma at his local gym. Laboratory work up showed neutropenia with an absolute neutrophil count of 952/cu.mm, but otherwise normal chemical profile including a normal CPK. Chest X-Ray and pan Cultures were negative for a source of infection. During the first admission, the patient was started on Cefepime assuming an infectious etiology for the condition. The fever subsided shortly after initiation of antibiotics; muscle symptoms however persisted. Antibiotics were stopped and not used in later cycles. MRI of right (see Figure 1) and left (see Figure 2) upper extremities

showed diffuse abnormal signal intensity involving the biceps and triceps muscles (mainly the long head and the lateral head) with feathery appearance of the muscles in keeping with injected oily material that is spread diffusely within the muscles with diffuse edema suggestive of inflammatory myositis, the subcutaneous fat planes showed diffuse edema. Silicone suppression series were later applied to the images to ensure that the injected material was an oil rather than silicone; Results confirmed that the material was oil. Myositis was managed using NSAIDs. Patient was discharged 3 days after initial presentation with resolution of fever and neutropenia, muscle symptoms persisted 10 days after presentation. Patient continued his scheduled chemotherapy and received a total of 6 cycles and NSAIDs were administered routinely during each cycle. Muscle symptoms recurred with another 2 cycles of chemotherapy with symptoms starting shortly after each cycle. Symptoms were similar as the same initial presentation of rapidly resolving fever not requiring antibiotics and muscle induration, edema, redness and heat of the biceps and triceps.



**Figure 1.** MR Imaging of the Right Arm. a: Sagittal T1-weighted (TR = 685; TE = 80) image; b: STIR image. Both showing faint diffuse increased signal intensity of the biceps and triceps muscles. In addition, a large focal high signal intensity collection is noted in the biceps with smaller collections in both biceps and triceps muscles; c: Sagittal T1-weighted post Gadolinium administration (TR = 685; TE = 80), there is mild diffuse enhancement of the affected muscles compatible with some muscle inflammation. There is also mild enhancement of the subcutaneous tissues



**Figure 2.** MR Imaging of the Left Arm. a: Sagittal T1-weighted image; b: STIR image; c: Axial T2-weighted image. These figures show diffuse increased signal intensity with feathery appearance involving the biceps and triceps muscle on both T1 and STIR sequences. The long and lateral heads of the triceps are most affected. The findings are in keeping with diffuse infiltration by the fat signal intensity substance with also inflammatory changes involving the affected portions of the muscles. The abnormality is seen reaching the deltoid muscle proximally and posteriorly. In addition, there are small collections of fat signal intensity involving the triceps muscle the largest measuring 1.5 cm. There is associated mild diffuse subcutaneous fat planes oedema of the entire arm

### 3 Discussion

Our literature review shows no prior reports of systematic manifestations from the use of injectable oils of any type with concurrent use of chemotherapy or any other drug. We are thereby reporting the first such case of a systematic reaction from previously injected oil enhancers. One possible explanation for such a reaction is centered upon the properties of the chemotherapeutic agents of the ABVD regimen. Adriamycine and Vincristine are both lipophilic agents and would have a tendency to concentrate in a lipid media. The inflammatory reaction involving the biceps and triceps symmetrically raises the possibility that the cytotoxic drugs concentrated in the oily material injected in the muscles. Myositis did not develop in

the first few doses then started to occur with repeated cycles probably due to cumulative drug dose. Later on, NSAIDs were given routinely which might explain why myositis became less prominent in future cycles. Cytotoxic drugs have a narrow therapeutic index and are dosed in accordance to their volume of distribution to have a minimal toxicity profile with optimal efficiency. Higher concentration of the drug within the oil, and therefore the muscle, could have produced local toxicity manifesting as local inflammation, especially since symptoms were localized to these muscles and not generalized to other muscles. Roles of Adriamycin and Vincristine in muscle dysfunction have been reported<sup>[1-3]</sup>. More evidence to support our hypothesis of a possible oil-drug reaction particularly chemotherapy comes from experience with the use of Bevacizumab injection into vitrectomized eyes with silicone injection to replace the vitreous humor. We found one study on the topic by Xu *et al.* of the pharmacokinetics of Bevacizumab in ocular tissue of normal rabbit eyes compared to those injected with silicone<sup>[4]</sup>. Eyes injected with silicone showed an altered distribution of Bevacizumab and a different profile of the drug level in tissues<sup>[4]</sup>. Similar changes of drug pharmacokinetics when suspended in silicone oil have been noted with intra ocular injection of ceftazidime, vancomycin, ganciclovir and triamcinolone<sup>[5, 6]</sup>.

We were unable to determine the nature of the injected oil used by our patient, as he was unable to provide us with a sample for chemical analysis. The case report however remains important in shedding light on concentration of chemotherapeutic agents in cosmetic oils leading to inflammatory reaction. This becomes especially important in an era where injectable oil for cosmesis is a common practice.

## References

- [1] Ferrans VJ, Clark JR, Zhang J, *et al.* Pathogenesis and prevention of doxorubicin cardiomyopathy. *Tsitologia*. 1997; 39(10): 928-37. PMID:9505340.
- [2] Di Gregorio F, Favaro G, Fiori MG. Functional evaluation of acute vincristine toxicity in rat skeletal muscle. *Muscle Nerve*. 1989; 12(12): 1017-23. PMID:2560143 <http://dx.doi.org/10.1002/mus.880121210>
- [3] Duarte-Karim M, Ruyschaert JM, Hildebrand J. Affinity of adriamycin to phospholipids a possible explanation for cardiac mitochondrial lesions. *Biochem. Biophys. Res. Commun.* 1976; 71(2): 658-663. [http://dx.doi.org/10.1016/0006-291X\(76\)90838-X](http://dx.doi.org/10.1016/0006-291X(76)90838-X)
- [4] Xu Y, You Y, Du W, *et al.* Ocular pharmacokinetics of bevacizumab in vitrectomized eyes with silicone oil tamponade. *Invest. Ophthalmol. Vis. Sci.* 2012; 53(9): 5221-6. PMID:22786911 <http://dx.doi.org/10.1167/iops.12-9702>
- [5] Hegazy HM, Kivilcim M, Peyman GA, *et al.* Evaluation of toxicity of intravitreal ceftazidime, vancomycin, and ganciclovir in a silicone oil-filled eye. *Retina*. 1999; 19(6): 553-7. PMID:10606458 <http://dx.doi.org/10.1097/00006982-199911000-00013>
- [6] Spitzer MS, Kaczmarek RT, Yoeruek E, *et al.* The distribution, release kinetics, and biocompatibility of triamcinolone injected and dispersed in silicone oil. *Invest. Ophthalmol. Vis. Sci.* 2009; 50(5): 2337-43. PMID:19098319 <http://dx.doi.org/10.1167/iops.08-2471>