

CASE REPORTS

Hepatitis E presenting as acalculous cholecystitis

Stefania Chetcuti Zammit, Neville Azzopardi, Edgar Pullicino

Department of Gastroenterology, Mater Dei Hospital, MALTA

Correspondence: Stefania Chetcuti Zammit. Address: Department of Gastroenterology, Mater Dei Hospital, Msida MSD 2090, MALTA. Email: stf_che@yahoo.com

Received: December 09, 2014

Accepted: June 11, 2015

Online Published: June 28, 2015

DOI: 10.5430/crim.v2n3p30

URL: <http://dx.doi.org/10.5430/crim.v2n3p30>

Abstract

We report a case of a 30-year-old female who presented with right upper quadrant pain and jaundice 30 days after consuming uncooked food in Thailand. Ultrasound examination of the hepatobiliary system revealed a distended gallbladder, thickened wall, sludge and a positive Murphy's sign, suggesting acalculous cholecystitis. Hepatitis E IgM antibodies were positive. She was treated conservatively with N-acetylcysteine, intravenous antibiotics and cholestyramine, pending the hepatitis E IgM result, with a gradual but full recovery. The association of acalculous cholecystitis with Hepatitis E is rarely described in the literature. Hepatitis E infection should be suspected in patients presenting with ultrasonographic changes in the gallbladder, in areas where hepatitis E is endemic or where there is a suggestive history.

Keywords

Acalculous cholecystitis, Hepatitis E, Gallbladder thickening, Jaundice

1 Introduction

There are very few reported cases of acalculous cholecystitis in association with hepatitis E. We describe a case of a female patient who presented with jaundice and gallbladder changes on ultrasound which were subsequently found to be secondary to viral hepatitis E infection.

2 Case report

A 30-year-old female presented to our hospital with a 5 day history of jaundice, epigastric and right upper quadrant pain with associated nausea, decreased appetite and severe itching. She denied loose bowel motions at the time. She had travelled to Pakistan and Thailand 2 months previously where she had eaten mangos and pineapples from a street stall.

Physical examination was unremarkable except for an icteric tinge and tenderness in the epigastrium and right upper quadrant. She was afebrile. She had significantly deranged liver function tests at presentation (see the Table). Ultrasound examination of the biliary system demonstrated a thickened, distended gallbladder wall with sludge in the lumen and a positive sonographic Murphy's sign (see the Figure). Hepatitis C antibodies and PCR, Adenovirus IgA, Leptospira serology, CMV serology and EBV PCR were all negative. Hepatitis A IgG was positive but Hepatitis A IgM was negative.

Hepatitis B serology was negative except for Hepatitis B surface antibody consistent with previous hepatitis B vaccination. Hepatitis E IgM was found to be positive.

She was treated with intravenous hydration and ceftriaxone. In view of severe itching she was also started on cholestyramine. N-acetylcysteine was commenced due to liver failure pending the hepatitis E serology results. Her liver function tests showed gradual improvement and the patient was discharged home eight days following her admission to hospital (see the Table).

Table. Blood results during the patient's hospital stay and after discharge home

	Day 1	Day 2	Day 3	Day 4	Day 5	Day 6	Day 7	Day 8	Day 7 after discharge home
Alkaline Phosphatase (40-129 u/l)	212	208	195	188	169	157	149	147	119
Alanine Amino Transferase (1.0-41 u/l)	1965	1602	1736	1226	860	671	392	302	157
Gamma Glutamyl Transferase (11.0-50 u/l)	110	100	94	88	76	70	59	57	48
Bilirubin ($\leq 22 \mu\text{mol/L}$)	163.50	182.10	164.50	170.00	136.90	120.5	98.60	82.60	53.4
Albumin (35-50g/L)	32.1	36.3	35.5	33.5	33.1	32.8	37.5	39.5	39.0
Platelets ($150-450 \times 10^9/\text{L}$)	194	175	188	208	215	220	245	245	240
INR (0.8 to 1.2)	1.52	1.36	1.33	1.30	1.30	1.20	1.20	1.10	1.0
White cell count ($3.5-10.5 \times 10^9/\text{L}$)	6.90	7.70	6.4	6.8	5	4.6	5.3	4.6	5.5
CRP (< 6)	95	101	120	125	114	93	85	80	15

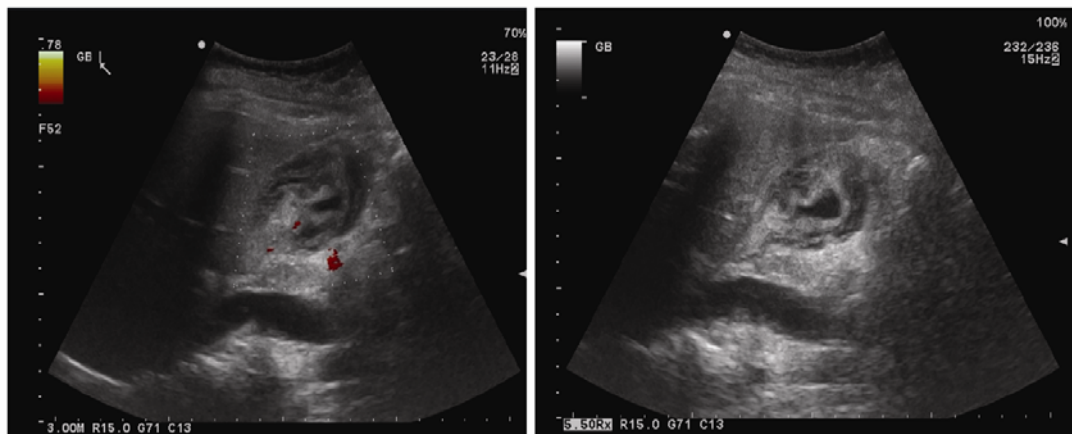


Figure. Ultrasound of the gallbladder showing a thickened gallbladder wall and sludge within the lumen

3 Discussion

We report the case of a patient with imported hepatitis E from a developing country. Hepatitis E infection can also be acquired through the consumption of uncooked or undercooked meat in industrialised countries. Public health data in 2014 in the UK demonstrated a 92.8% positive Hepatitis E plasma antibody rate in slaughtered pigs with 47% of these being IgM positive [1]. This underlines the importance of having a high index of suspicion for the infection in symptomatic patients presenting with typical features but who have no history of foreign travel.

Gallbladder changes on ultrasound have been described in 50%-100% of adults with acute viral hepatitis. The commonest findings are gallbladder collapse and gallbladder wall thickening [2-7] and are more frequently observed in patients with: hepatitis A infection, females, high bilirubin level [8] and high liver enzymes [9, 10]. Patients with structural gallbladder changes on ultrasound and acute hepatitis A infection have a poorer prognosis [11].

Acute acalculous cholecystitis can have a high complication rate and mortality if not treated early. Sensitivity and specificity of ultrasonography in diagnosing acute acalculous cholecystitis is reported to be up to 93% and 100% respectively [12-16].

Most studies refer to 2 major or 1 major and 2 minor criteria that need to be satisfied for the diagnosis of acute acalculous cholecystitis. Major criteria include a thickened gallbladder wall of 3.5 mm or more, pericholecystic fluid or subserosal oedema, intramural gas and sloughed mucosal membrane. Minor criteria include echogenic bile (sludge) and hydrops [17-26]. Gallbladder wall thickness should not be used as the only feature that identifies cholecystitis as it can be a non-specific finding in other diseases such as heart failure and kidney disease [27]. Our patient was a healthy young female with no past medical history that could have explained the gallbladder findings.

Other features that are commonly observed in acute hepatitis infection on ultrasound imaging include accentuated brightness and more extensive demonstration of the portal vein walls and decreased echogenicity of the liver [28]. However increased brightness and clear visualization of portal vein radicle walls can also be found in healthy patients [29].

Our patient did not satisfy the above criteria but had a thickened gallbladder wall with sludge in the lumen and a positive sonographic Murphy's sign in the absence of gallstones. These features point towards acute inflammation of the gall bladder. Murphy's sign can help distinguish acute acalculous cholecystitis from a distended gallbladder caused by prolonged fasting. However Murphy's sign may be masked by altered mental status or medications. A positive Murphy's sign has a sensitivity of 86% to 97% [30-32].

Our patient had very high alanine amino transferase and bilirubin levels, commonly found in patients with acute viral hepatitis. She also had hypoalbuminaemia and a raised INR consistent with liver failure. All of these started to improve eventually. Despite the acute infection, white cell count was normal. The CRP level was elevated. CRP is usually high in acute viral hepatitis, especially in hepatitis A infection [33] and correlates well with deranged liver function tests [34].

To our knowledge, the only case report in the literature of acalculous cholecystitis in hepatitis E was that of a child who developed hydrops of the gallbladder [2]. The incidence of acalculous cholecystitis in hepatitis E is reported to be between 76% to 85% in the current literature [35, 36].

Several mechanisms have been proposed to explain gallbladder wall thickening in patients with acute hepatitis. Hepatocyte necrosis is extensive in patients with acute hepatitis, causing an inflammatory reaction in the tissues surrounding the liver, including the gallbladder wall [37]. Viral hepatitis leads to increased activation of the factor XII-coagulation pathway causing damage to the blood vessels supplying the gallbladder, resulting in ischaemia [38]. The hepatitis virus in bile juice can cause direct injury to the muscular layers of the gallbladder [39], as well as lymphatic obstruction. However, the condition most likely results from an increase in bile viscosity, due to prolonged stasis, that eventually leads to an obstruction of the cystic duct [40].

Treatment of acalculous cholecystitis in association with viral hepatitis is initially conservative with intravenous hydration. Early cholecystectomy should be carried out if complications such as perforation, gangrene or abscess are suspected [41]. Antibiotics might play a role in acalculous cholecystitis as initially the diagnosis of viral hepatitis might not be evident, as in our case. Antibiotics might also have a role in the early management of complications or possibly prevent secondary bacterial infection. Our patient was managed conservatively with intravenous fluids, antibiotics and N-acetylcysteine due to the severely deranged liver function tests pending the diagnosis of Hepatitis E.

Viral hepatitis should be highly suspected in those patients with acute signs of cholecystitis, absence of gallstones on ultrasound and deranged liver function tests. Early recognition is important due to the potential lethal complications that can result if this infection is undetected.

4 Conclusion

Hepatitis E infection should be highly suspected in patients with evidence of acalculous cholecystitis on ultrasound who present with typical signs and symptoms, especially if they have a recent travel history to areas with a high incidence of hepatitis E infection.

Acknowledgements

The authors would like to thank Dr Christine Azzopardi from the Radiology Department (Mater Dei Hospital, Malta) for providing and interpreting ultrasound images.

References

- [1] Tedder R. Hepatitis E Virus infection in UK pigs at the time of slaughter. UCL on behalf of Blood Borne Virus Unit Virus Reference Dept Public Health England, 2013. <http://web.archive.nationalarchives.gov.uk/20140707135733/http://www.defra.gov.uk/ahvla-en/files/pig-survey-hepatitisE-results.pdf>.
- [2] Sinha R, Negi V, Sawhney MPS, *et al.* A Rare Association of Hydrops of Gallbladder with Hepatitis E Infection. *J Nep Paedr Soc.* 2011; 31: 216-222-223.
- [3] Maresca G, De Gaetano AM, Mirk P, *et al.* Sonographic patterns of the gallbladder in acute viral hepatitis. *J Clin Ultrasound.* 1984; 12(3): 141-6. PMID:6423687 <http://dx.doi.org/10.1002/jcu.1870120305>
- [4] Sharma MP, Dasarathy S. Gallbladder abnormalities in acute viral hepatitis: a prospective ultrasound evaluation. *J Clin Gastroenterol.* 1991; 13(6): 697-700. <http://dx.doi.org/10.1097/00004836-199112000-00018>
- [5] Giorgio A, Francica G, Amoroso P, *et al.* Morphologic and motility changes of the gallbladder in response to acute liver injury. A prospective real-time sonographic study in 255 patients with acute viral hepatitis. *J Ultrasound Med.* 1989; 8(9): 499-506. PMID:2674472
- [6] Portincasa P, Moschetta A, Di Ciaula A, *et al.* Changes of gallbladder and gastric dynamics in patients with acute hepatitis. *Eur J Clin Invest.* 2001; 31(7): 617-22. PMID:11454017 <http://dx.doi.org/10.1046/j.1365-2362.2001.00834.x>
- [7] Zivković R, Trajer A. Ultrasound diagnosis of acute viral hepatitis. *Acta Med Croatica.* 1998; 52(2): 109-13. PMID:9682498
- [8] Suk KT, Kim CH, Baik SK, *et al.* Gallbladder wall thickening in patients with acute hepatitis. *J Clin Ultrasound.* 2009; 37(3): 144-8. PMID:19035335 <http://dx.doi.org/10.1002/jcu.20542>
- [9] Kim MY, Baik SK, Choi YJ, *et al.* Endoscopic sonographic evaluation of the thickened gallbladder wall in patients with acute hepatitis. *J Clin Ultrasound.* 2003; 31(5): 245-9. PMID:12767019 <http://dx.doi.org/10.1002/jcu.10167>
- [10] Maudgal DP, Wansbrough-Jones MH, Joseph AE. Gallbladder abnormalities in acute infectious hepatitis. A prospective study. *Dig Dis Sci.* 1984; 29(3): 257-60. PMID:6697864 <http://dx.doi.org/10.1007/BF01296260>
- [11] Ahn JH, Chung JJ, Yu JS, *et al.* Prognostic value of gallbladder wall thickening in patients with acute hepatitis A. *Ultrasonography.* 2015; 34(2): 139-43. PMID:25672770 <http://dx.doi.org/10.14366/usg.14052>
- [12] Mirvis SE, Vainright JR, Nelson AW, *et al.* The diagnosis of acute acalculous cholecystitis: a comparison of sonography, scintigraphy, and CT. *AJR Am J Roentgenol.* 1986; 147(6): 1171-5. PMID:3535451 <http://dx.doi.org/10.2214/ajr.147.6.1171>
- [13] Zeman AK, Burrell MI, Cahou CF, *et al.* Cholescintigraphy, ultrasound, and computerized tomography in the evaluation of biliary tract disorders. *Semin Nucl Med.* 1979; 9: 22-35. [http://dx.doi.org/10.1016/S0001-2998\(79\)80005-7](http://dx.doi.org/10.1016/S0001-2998(79)80005-7)
- [14] Ralls PW, Colletti PM, Halls JM, *et al.* Diagnostic utility of cholescintigraphy and ultrasound in acute cholecystitis. *Am J Surg.* 1981; 141: 446-451. [http://dx.doi.org/10.1016/0002-9610\(81\)90138-0](http://dx.doi.org/10.1016/0002-9610(81)90138-0)
- [15] Ralls PW, Colletti PM, Halls JM, *et al.* Prospective evaluation of 99m Tc-IDA cholescintigraphy and grey-scale ultrasonography in the diagnosis of acute cholecystitis. *Radiology.* 1982; 144: 369-371 18.
- [16] Deitch EA, Engel JM. Acute acalculous cholecystitis. *Am J Surg.* 1981; 142(2): 290-2. [http://dx.doi.org/10.1016/0002-9610\(81\)90295-6](http://dx.doi.org/10.1016/0002-9610(81)90295-6)

- [17] Barie PS, Eachempati SR. Acute acalculous cholecystitis. *Curr Gastroenterol Rep.* 2003; 5: 302-309. PMID:12864960 <http://dx.doi.org/10.1007/s11894-003-0067-x>
- [18] Beckman I, Dash N, Sefczek RJ, *et al.* Ultrasonographic findings in acute acalculous cholecystitis. *Gastrointest Radiol.* 1985; 10: 387-389. PMID:3902551 <http://dx.doi.org/10.1007/BF01893137>
- [19] Mariat G, Mahul P, Prev TN, *et al.* Contribution of ultrasonography and cholescintigraphy to the diagnosis of acute acalculous cholecystitis in intensive care unit patients. *Intensive Care Med.* 2000; 26: 1658-1663. PMID:11193273 <http://dx.doi.org/10.1007/s001340000684>
- [20] Deitch EA, Engel JM. Ultrasonic detection of acute cholecystitis with pericholecystic abscesses. *Am Surg.* 1981; 47: 211-214. PMID:7015938
- [21] Shuman WP, Rogers JV, Rudd TG, *et al.* Low sensitivity of sonography and cholescintigraphy in acalculous cholecystitis. *AJR Am J Roentgenol.* 1984; 142: 531-534. PMID:6607639 <http://dx.doi.org/10.2214/ajr.142.3.531>
- [22] Mirvis SE, Vainright JR, Nelson AW, *et al.* The diagnosis of acute acalculous cholecystitis: a comparison of sonography, scintigraphy, and CT. *AJR Am J Roentgenol.* 1986; 147: 1171-1175. PMID:3535451 <http://dx.doi.org/10.2214/ajr.147.6.1171>
- [23] Boland GWL, Slater G, Lu DSK, *et al.* Prevalence and significance of gallbladder abnormalities seen on sonography in intensive care unit patients. *AJR Am J Roentgenol.* 2000; 174: 973-977. PMID:10749232 <http://dx.doi.org/10.2214/ajr.174.4.1740973>
- [24] Deitch EJM. Ultrasound in elective biliary tract surgery. *Am J Surg.* 1980; 140: 277-283. [http://dx.doi.org/10.1016/0002-9610\(80\)90022-7](http://dx.doi.org/10.1016/0002-9610(80)90022-7)
- [25] Molenat F, Boussuges A, Valantin V, *et al.* Gallbladder abnormalities in medical ICU patients: an ultrasonographic study. *Intensive Care Med.* 1996; 22: 356-358. PMID:8708175 <http://dx.doi.org/10.1007/BF01700459>
- [26] Imhof M, Raunest J, Ohmann C, *et al.* Acute acalculous cholecystitis complicating trauma: a prospective sonographic study. *World J Surg.* 1992; 16(6): 1160-1165. PMID:1455890 <http://dx.doi.org/10.1007/BF02067089>
- [27] Shlaer WJ, Leopold GR, Scheible FW. Sonography of the thickened gallbladder wall: a nonspecific finding. *AJR Am J Roentgenol.* 1981; 136(2): 337-9. PMID:6781256 <http://dx.doi.org/10.2214/ajr.136.2.337>
- [28] Kurtz AB, Rubin CS, Cooper HS, *et al.* Ultrasound findings in hepatitis. *Radiology.* 1980; 136(3): 717-23. PMID:7403553 <http://dx.doi.org/10.1148/radiology.136.3.7403553>
- [29] Giorgio A, Amoroso P, Fico P, *et al.* Ultrasound evaluation of uncomplicated and complicated acute viral hepatitis. *J Clin Ultrasound.* 1986; 14: 675-679. PMID:3098787 <http://dx.doi.org/10.1002/jcu.1870140903>
- [30] Ralls PW, Colletti PM, Lapin SA, *et al.* Real-time sonography in suspected acute cholecystitis. Prospective evaluation of primary and secondary signs. *Radiology.* 1985; 155(3): 767-71. PMID:3890007 <http://dx.doi.org/10.1148/radiology.155.3.3890007>
- [31] Bree RL. Further observations on the usefulness of the sonographic Murphy sign in the evaluation of suspected acute cholecystitis. *J Clin Ultrasound.* 1995; 23(3):169-172. PMID:7730462 <http://dx.doi.org/10.1002/jcu.1870230304>
- [32] Singer AJI, McCracken G, Henry MC, *et al.* Correlation among clinical, laboratory, and hepatobiliary scanning finding in patients with suspected acute cholecystitis. *Ann of Emerg Med.* 1996; 28: 267-272. [http://dx.doi.org/10.1016/S0196-0644\(96\)70024-0](http://dx.doi.org/10.1016/S0196-0644(96)70024-0)
- [33] Atono YI, Sata M, Tanikawa K. Kinetics of C-reactive protein in acute viral hepatitis. *Gastroenterol Jpn.* 1989; 24(6): 655-62. PMID:2514117
- [34] Amer Taha T. Evaluation of C- Reactive Protein (CRP) Titer in Patients with Acute Hepatitis A Virus Infection. *Journal of al-qadisiyah for pure science (quarterly).* 2011; 16(1): 1-10.
- [35] Ibrahim AS, Alkhal A, Jacob J, *et al.* Hepatitis E in Qatar imported by expatriate workers from Nepal: epidemiological characteristics and clinical manifestations. *J Med Virol.* 2009; 81: 1047-51. PMID:19382273 <http://dx.doi.org/10.1002/jmv.21474>
- [36] Sudhamsu KC. Ultrasound findings in acute viral hepatitis. *Kathmandu Univ Med J (KUMJ).* 2006; 4(4): 415-8.
- [37] Juttner HU, Ralls PW, Quinn MF, *et al.* Thickening of the gallbladder wall in acute hepatitis: ultrasound demonstration. *Radiology.* 1982; 142: 465. PMID:7054838 <http://dx.doi.org/10.1148/radiology.142.2.7054838>
- [38] Glenn F, Becker CG. Acute acalculous cholecystitis. An increasing entity. *Ann Surg.* 1982; 195: 131-136. PMID:7055388 <http://dx.doi.org/10.1097/00000658-198202000-00002>
- [39] Dogra R, Singh J, Sharma MP. Enterically transmitted non-A, non-B hepatitis mimicking acute cholecystitis. *Am J Gastroenterol.* 1995; 90: 764. PMID:7733085
- [40] Dupriest AW, Khaveja SC, Cowley AA. Acute cholecystitis complicating trauma. *Ann Surg.* 1979; 89(1): 84-89. <http://dx.doi.org/10.1097/00000658-197901000-00016>
- [41] Kaya S, Eskazan AE, Ay N, *et al.* Acute Acalculous Cholecystitis due to Viral Hepatitis A. *Case Rep Infect Dis.* 2013. PMID:24106622 <http://dx.doi.org/10.1155/2013/407182>