

CASE REPORT**Large negative U waves associated with hypokalemia****Brian A. Dalrymple¹, Laszlo Littmann²**

1. Carolinas Hospitalist Group, Carolinas Medical Center, Charlotte, NC, USA. 2. Department of Internal Medicine, Carolinas Medical Center, Charlotte, NC, USA.

Correspondence: Laszlo Littmann. Address: Department of Internal Medicine, Carolinas Medical Center, P. O. Box 32861, Charlotte, NC 28232, USA. Email: Laszlo.Littmann@carolinashealthcare.org

Received: October 15, 2014

Accepted: October 22, 2014

Online Published: November 7, 2014

DOI: 10.5430/crim.v2n1p69

URL: <http://dx.doi.org/10.5430/crim.v2n1p69>

Abstract

Negative U waves in the electrocardiogram are highly specific indicators of hypertensive, valvular or ischemic heart disease. Hypokalemia, on the other hand, is usually associated with large positive U waves. In this report we present a case where a routine preoperative electrocardiogram showed large negative U waves in the chest leads. Thorough cardiac evaluation ruled out any of the listed structural or functional abnormalities. At the time of the recording, the patient had profound hypokalemia. After normalization of the serum potassium, the large negative U waves resolved. To our knowledge, this is the first reported case of negative U waves in hypokalemia. We offer a possible explanation for this unusual finding.

Keywords

Electrocardiogram, U waves, Hypokalemia, Hypertension, Ischemia

1 Introduction

Hypokalemia is frequently associated with large positive U waves in the electrocardiogram (ECG). In this report we present a case of severe hypokalemia where the ECG showed large negative U waves. To our knowledge, this is the first reported case of negative U waves in hypokalemia. We propose a possible mechanism to explain this unusual finding.

2 Case presentation

A 43-year-old man with a long history of T11 paraplegia and chronic stage IV sacral decubiti was hospitalized for ischemic left foot. At the time of admission he was hypotensive and was considered to be septic. The patient was quickly stabilized with antibiotics and IV fluid hydration. Because of a gangrenous left foot, he was scheduled to undergo above-knee amputation. A routine preoperative ECG was normal except for the presence of up to 2½ mm (0.25 mV) large, distinct negative U waves in leads V₃-V₅ and more shallow negative U waves in V₂ and V₆ (see Figure 1).

The patient had no history of hypertension or heart disease. His blood pressure was low or normal throughout his hospitalization. He had no cardiac complaints and his cardiac exam was benign.

Because of the known association of negative U waves with valvular heart disease and severe ischemic heart disease involving the left anterior descending coronary artery, and because of the scheduled vascular surgery, further cardiac testing was performed [1, 2]. Plasma troponin level was negative. Transthoracic echocardiogram showed normal chamber sizes, an estimated left ventricular ejection fraction of 55%-60%, and no valvular abnormalities. There was no suggestion of left ventricular hypertrophy; septal thickness was 0.75 cm and posterior wall thickness was 0.72 cm. On a nuclear heart scan myocardial perfusion was normal at baseline and following injection of regadenosone. Gated SPECT images demonstrated normal myocardial thickening and wall motion. The calculated ejection fraction with this technique was 65%.

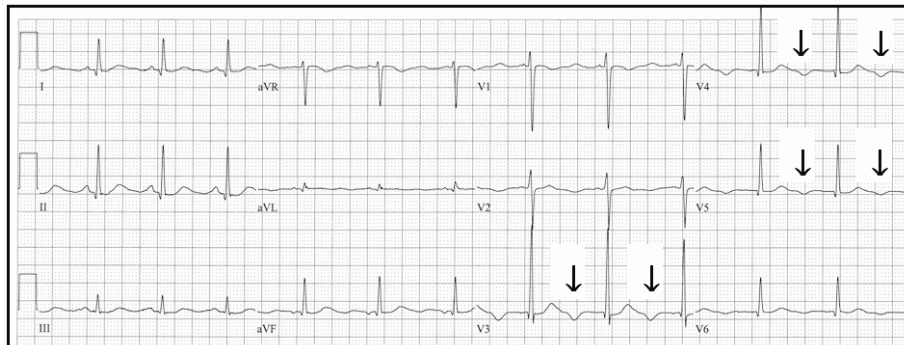


Figure 1. Routine preoperative electrocardiogram demonstrating large negative U waves in leads V3-V5 (arrows) and more shallow negative U waves in V2 and V6. At the time of this recording, the serum potassium level was 2.4 mmol/L.

At the time of the recording of the ECG shown in Figure 1, the patient’s serum potassium level was very low at 2.4 mmol/L. Intracellular (lymphocyte or erythrocyte) levels of potassium were not measured. Two days after intravenous and oral potassium replacement, the serum potassium was 3.7 mmol/L. A repeat ECG at this time showed almost complete resolution of the negative U waves except for trivial negative U waves in V4 and V5 (see Figure 2). Of note, the QT intervals were normal in both recordings. Continuous telemetry monitoring did not reveal any dysrhythmia. The patient underwent above knee amputation without complication.

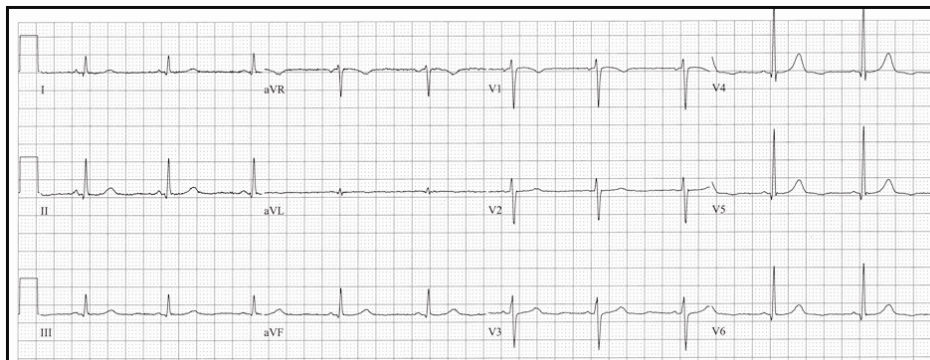


Figure 2. Two days after the initial electrocardiogram, the large negative U waves have resolved. At the time of this recording, the serum potassium level was 3.7 mmol/L.

3 Discussion

Negative U waves are infrequently recognized by physicians and are not recognized by ECG interpretation softwares. Negative U waves, however, are important findings in the ECG because their presence is highly specific for severe

hypertension or structural heart disease^[1, 2]. In patients with hypertension, the negative U waves typically follow negative T waves (the strain pattern); positive T waves followed by negative U waves are uncommon^[3, 4]. Normalization of the blood pressure may result in less negativity of the U waves or even in the U waves becoming upright^[5]. The most common valvular heart disease associated with negative U waves is severe aortic regurgitation, but negative U waves have also been demonstrated in patients with mitral regurgitation or congenital heart disease^[2, 6]. The most worrisome clinical association with negative U waves, however, is ischemic heart disease. Resting U-wave inversion can be a marker of left main disease or severe stenosis of the left anterior descending coronary artery^[7]. Transient negative U waves have been demonstrated in patients with spontaneous or exercise-induced angina, during attacks of variant angina, and in the acute stage of anterior ST-elevation myocardial infarction^[8-15].

Severe hypokalemia is frequently characterized by the presence of large positive U waves in the ECG^[16]. The exact mechanism is debated^[17-19]. The most widely accepted explanation is hypokalemia-induced early afterdepolarization which results in widening of the action potential duration at the myocyte level reflected by widening of the Q-U interval in the surface ECG^[20]. A large upright U wave is a risk factor for early afterdepolarization-induced triggered activity which can initiate torsade de pointes ventricular tachycardia and ventricular fibrillation^[20, 21]. Severe hypokalemia can masquerade as myocardial ischemia in the ECG, but troponin levels usually remain negative^[22].

A thorough literature search revealed only one previous publication which demonstrated large negative U waves in a patient with hypokalemia, but that was in the setting of uncontrolled hypertension^[23]. To our knowledge, negative U waves have never been described in hypokalemia without evidence of hypertension or structural heart disease. It is uncertain why in our case severe hypokalemia caused large negative rather than positive U waves. One possible explanation is that hypokalemia-related positive U waves were localized to the intraventricular septum or the right ventricular free wall, and the negative U waves seen in the mid-anterior leads reflected a left-to-right U wave vector. Close scrutiny of the initial hypokalemic ECG did reveal large, distant upright U waves in lead V₁ which temporally coincided with the negative U waves in V₃ and V₄ (see Figure 3). It is interesting that in the only other publication demonstrating negative U waves in hypokalemia, similar large positive U waves were inscribed in leads V₁ and V₂^[23]. Normalization of the serum potassium level in our case not only resulted in normalization of the negative U waves in the mid-precordial leads, but also in the alleviation of the large positive U waves in V₁ (see Figure 2). Recording of other right-sided chest leads would have been useful but was not performed.

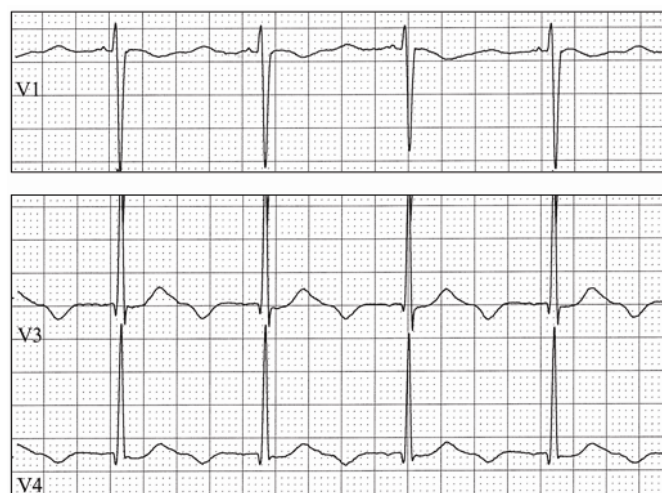


Figure 3. Enlargement of selected chest leads from Figure 1. In lead V₁, large distant positive U waves temporally coincide with the negative U waves seen in V₃ and V₄. See text.

4 Conclusion

Physicians should be educated about the association of negative U waves with severe structural heart disease including ischemic heart disease involving the left anterior descending coronary artery. They should, however, also be made aware of its possible relationship with hypokalemia. A prospective and systematic review of ECGs of patients with hypokalemia could shed light to the prevalence and clinical significance of this phenomenon.

References

- [1] Watanabe N. Clinical significance of the negative U wave in electrocardiogram. *Jpn Circ J.* 1967; 31(1): 9-31. <http://dx.doi.org/10.1253/jcj.31.9>
- [2] Kishida H, Cole JS, Surawicz B. Negative U wave: a highly specific but poorly understood sign of heart disease. *Am J Cardiol.* 1982; 49(8): 2030-6. [http://dx.doi.org/10.1016/0002-9149\(82\)90225-9](http://dx.doi.org/10.1016/0002-9149(82)90225-9)
- [3] Surawicz B, Kemp RL, Bellet S. Polarity and amplitude of the U wave of the electrocardiogram in relation to that of the T wave. *Circulation.* 1957; 15(1): 90-7. <http://dx.doi.org/10.1161/01.CIR.15.1.90>
- [4] Kemp RL, Surawicz B, Bettinger JC, et al. Prognostic significance of negative U waves in the electrocardiogram in hypertension. *Circulation.* 1957; 15(1): 98-101. <http://dx.doi.org/10.1161/01.CIR.15.1.98>
- [5] Georgopoulos AJ, Proudfit WL, Page IH. Relationship between arterial pressure and negative U waves in electrocardiograms. *Circulation.* 1961; 23(5): 675-80. <http://dx.doi.org/10.1161/01.CIR.23.5.675>
- [6] Venkatachalam S, Rimmerman CM. Electrocardiography in aortic regurgitation: it's in the details. *Cleve Clin J Med.* 2011; 78(8): 505-6. <http://dx.doi.org/10.3949/ccjm.78a.10141>
- [7] Gerson MC, McHenry PL. Resting U wave inversion as a marker of stenosis of the left anterior descending coronary artery. *Am J Med.* 1980; 69(4): 545-50. [http://dx.doi.org/10.1016/0002-9343\(80\)90465-9](http://dx.doi.org/10.1016/0002-9343(80)90465-9)
- [8] Palmer JH. U wave inversion. *Br Heart J.* 1948; 10(4): 247-51. <http://dx.doi.org/10.1136/hrt.10.4.247>
- [9] Papp C. U wave in coronary disease. *Circulation.* 1957; 15(1): 105-10. <http://dx.doi.org/10.1161/01.CIR.15.1.105>
- [10] Miwa K, Murakami T, Kambara H, et al. U wave inversion during attacks of variant angina. *Br Heart J.* 1983; 50(4): 378-82. <http://dx.doi.org/10.1136/hrt.50.4.378>
- [11] Gerson MC, Phillips JF, Morris SN, et al. Exercise-induced U-wave inversion as a marker of stenosis of the left anterior descending coronary artery. *Circulation.* 1979; 60(5): 1014-20. <http://dx.doi.org/10.1161/01.CIR.60.5.1014>
- [12] Yamaguchi T, Yotsukura M, Kabasawa S, et al. Giant negative U waves during acute myocardial infarction and ischemia. *J Electrocardiol.* 1997; 30(2): 105-8. [http://dx.doi.org/10.1016/S0022-0736\(97\)80017-9](http://dx.doi.org/10.1016/S0022-0736(97)80017-9)
- [13] Matsuguchi T, Koiwaya Y, Nakagaki O, et al. Transient U wave inversion during variant angina. *Am Heart J.* 1984; 108(4): 899-904. [http://dx.doi.org/10.1016/0002-8703\(84\)90452-6](http://dx.doi.org/10.1016/0002-8703(84)90452-6)
- [14] Miwa K, Miyagi Y, Fujita M, et al. Transient terminal U wave inversion as a more specific marker of myocardial ischemia. *Am Heart J.* 1993; 125(4): 981-6. [http://dx.doi.org/10.1016/0002-8703\(93\)90104-H](http://dx.doi.org/10.1016/0002-8703(93)90104-H)
- [15] Sovari AA, Farokhi F, Kocheril AG. Inverted U wave, a specific electrocardiographic sign of cardiac ischemia. *Am J Emerg Med.* 2007; 25(2): 235-7. <http://dx.doi.org/10.1016/j.ajem.2006.11.004>
- [16] Diercks DB, Shumaik GM, Harrigan RA, et al. Electrocardiographic manifestations: electrolyte abnormalities. *J Emerg Med.* 2004; 27(2): 153-60. <http://dx.doi.org/10.1016/j.jemermed.2004.04.006>
- [17] Lepeschkin E. Genesis of the U wave. *Circulation.* 1957; 15(1): 77-81. <http://dx.doi.org/10.1161/01.CIR.15.1.77>
- [18] Surawicz B. U wave: facts, hypotheses, misconceptions, and misnomers. *J Cardiovasc Electrophysiol.* 1998; 9(10): 1117-28. <http://dx.doi.org/10.1111/j.1540-8167.1998.tb00890.x>
- [19] Conrath CE, Ophhof T. The patient U wave. *Cardiovasc Res.* 2005; 67(2): 184-6. <http://dx.doi.org/10.1016/j.cardiores.2005.05.027>
- [20] Tai Fu L, Kato N, Takahashi N. Hypopotassemia-induced U wave in electrocardiogram (an experimental study for possible mechanism). *Basic Res Cardiol.* 1984; 79(4): 494-502. <http://dx.doi.org/10.1007/BF01908150>
- [21] Antzelevitch C, Sicouri S. Clinical relevance of cardiac arrhythmias generated by afterdepolarizations: role of M cells in the generation of U waves, triggered activity and torsade de pointes. *J Am Coll Cardiol.* 1994; 23(1):259-77. [http://dx.doi.org/10.1016/0735-1097\(94\)90529-0](http://dx.doi.org/10.1016/0735-1097(94)90529-0)
- [22] Petrov DB, Sardovski SI, Milanova MH. Severe hypokalemia masquerading myocardial ischemia. *Cardiol Res.* 2012; 3(5): 236-8. <http://dx.doi.org/10.4021/cr222w>
- [23] Kanemoto N, Nakayama K, Ide M, et al. Giant negative U waves in a patient with uncontrolled hypertension and severe hypokalemia. *J Electrocardiol.* 1992; 25(2): 163-6. [http://dx.doi.org/10.1016/0022-0736\(92\)90121-F](http://dx.doi.org/10.1016/0022-0736(92)90121-F)