

CASE REPORT

A rare case of May-Thurner-like syndrome in an elderly lady

Chris Pui Yan Yee ¹, Kapil Sahnan ², Robert Hywel Thomas ¹, Kaji Sritharan ¹

1. Department of Vascular Surgery, St Mary's Hospital, London, United Kingdom. 2. Department of Radiology, St Mary's Hospital, London, United Kingdom.

Correspondence: Kapil Sahnan. Address: St Mary's Hospital, London, United Kingdom. Email: ks303@doctors.org.uk

Received: February 23, 2014

Accepted: March 5, 2014

Online Published: March 12, 2014

DOI: 10.5430/crim.v1n2p19

URL: <http://dx.doi.org/10.5430/crim.v1n2p19>

Abstract

An elderly lady presented with decreased mobility, sputum production and intermittent confusion.

She was treated for chest sepsis, fast atrial fibrillation, and acute kidney injury, and also noted to have a swollen left leg. Venous duplex imaging showed extensive thrombus within the left common iliac, left external iliac and left common femoral veins.

A CT Venogram showed compression of the left common iliac vein between an osteophyte at L5 and a calcified ipsilateral common iliac artery. It also showed a pelvic kidney with an extra renal pelvis and large renal cyst which was indirectly contributing to venous compression by splinting the left iliac artery.

A decision was made after discussion at the Vascular MDT that the patient was not fit enough for surgery and to manage her medically with anticoagulation.

Discussion: Proximal DVT's are rarer than distal thrombosis, but have similar causes. One of the rarer causes of proximal DVT is May-Thurner syndrome and its variants known collectively as non-thrombotic iliac vein lesions. May-Thurner originally described DVT formation caused by extrinsic compression of the left common iliac vein between the overriding contralateral (right) common iliac artery and adjacent lumbar vertebrae. The best imaging modality is a CT Venogram. Duplex ultrasonography can be used, although it can be difficult to visualize the iliac veins.

The mainstay of management is surgical thrombectomy, or thrombolysis, followed by stenting of the affected vessel. However, if intervention is not appropriate, then it can be managed medically with anticoagulation.

Keywords

May-Thurner syndrome, Iliac vein thrombosis

1 Introduction

May-Thurner Syndrome is a rare cause of proximal DVT formation. Usually affecting young women, the syndrome now encompasses variants of the original description, which was of thrombosis formation secondary to left iliac vein compression between the contralateral iliac artery and lumbar spinal vertebrae. Our case details a never-before described variant of May-Thurner Syndrome.

2 Case presentation

An 87 year old lady presented to the emergency department with decreased mobility, confusion and a productive cough. On examination she was found to be in atrial fibrillation and have left sided chest signs. Her abdomen was soft and non-tender with no masses. She had a unilateral swollen leg to her proximal thigh. There was a full complement of palpable lower arterial pulses and no skin changes.

Her past medical history included hypertension, hypothyroidism and she was known to have a large cyst on her left kidney. She was taking anti-hypertensives and thyroxine. She had no relevant family history and was an ex-smoker.

Initial investigations confirmed sepsis with a white cell count of $17 \times 10^9/L$ and a C-reactive protein of 237mg/L. Her urea and electrolytes showed an acute kidney injury with a raised creatinine of 280umol/L and μ rea 32mmol/L. Chest radiography confirmed a lower respiratory tract infection.

Venous ultrasonography scan was performed which demonstrated an acute occlusive thrombus in the left common iliac, external iliac and common femoral veins.

She was admitted to a medical high dependency unit and commenced on antibiotics in accordance to the local hospital guidelines for community-acquired pneumonia, and fluid resuscitated for her acute kidney injury. Digoxin was given for her fast atrial fibrillation and intravenous heparin for a presumed proximal deep vein thrombosis (DVT) after discussion with the vascular team.

A Computerised Tomography Venogram (CTV) showed extrinsic compression of the left common iliac vein by the ipsilateral calcified common iliac artery and L5 osteophyte as shown in Figures 1, 2 and 4.

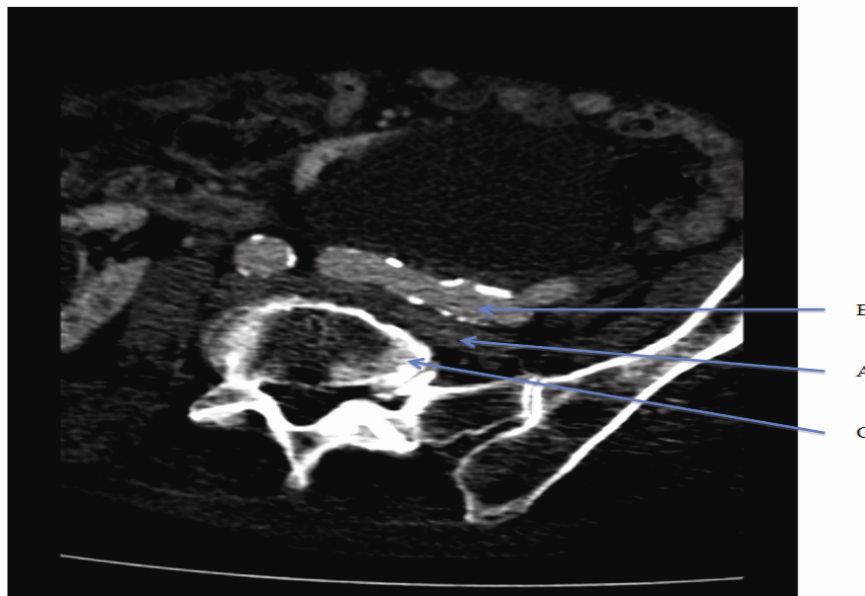


Figure 1. Compression of Left common iliac vein (A) between Left common iliac artery (B) and L5 (C)

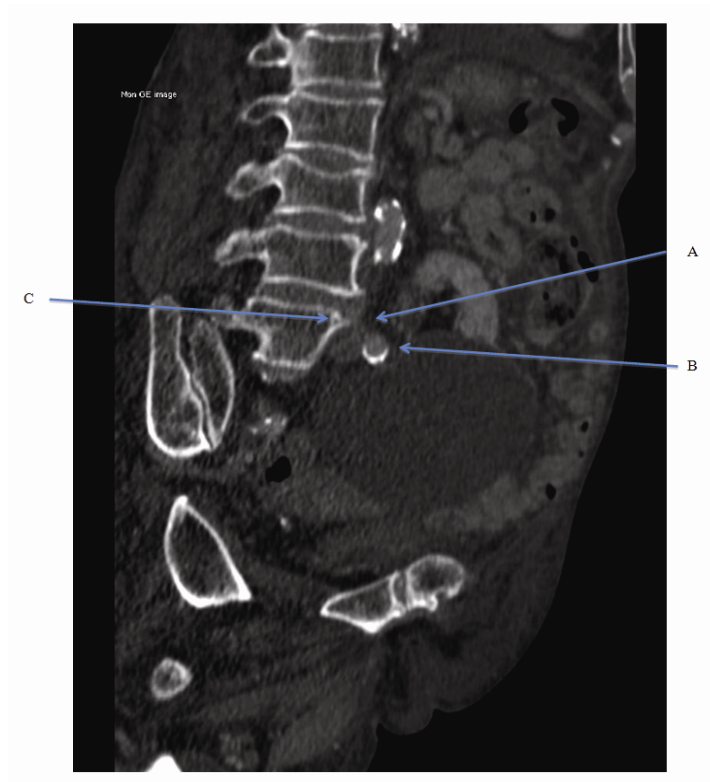


Figure 2. Sagittal section showing compressed Left common iliac vein (A), Left common iliac artery (B), L5 Osteophyte (C)

In addition there was a pelvic kidney noted with an extra renal pelvis (see Figure 3) indirectly contributing to the compression of the common iliac vein by splinting the left common iliac artery (see Figure 4).

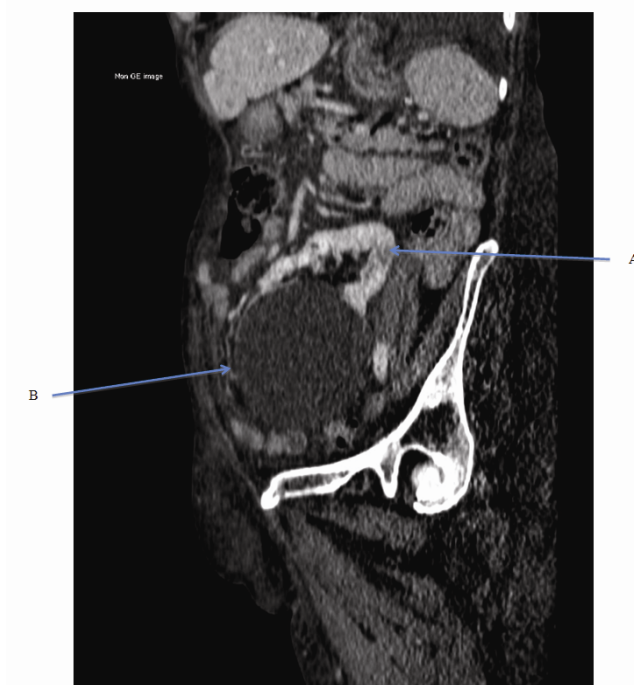


Figure 3. Sagittal section showing Pelvic Kidney (A), Extra Renal Pelvis (B)

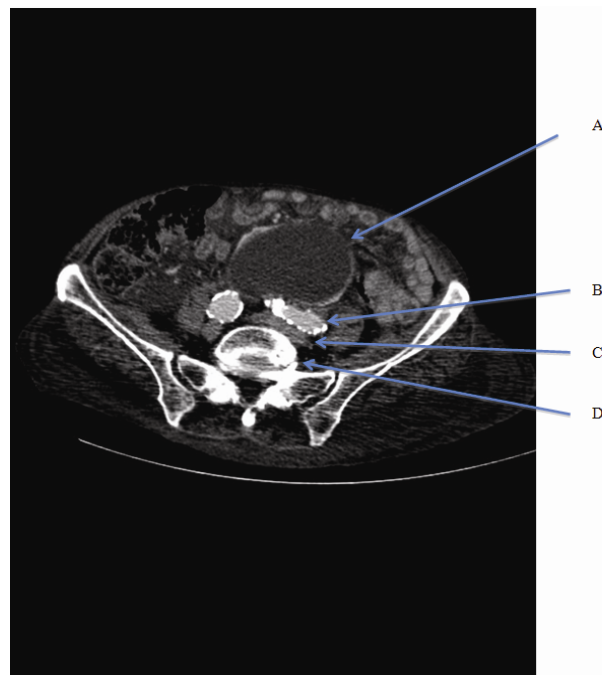


Figure 4. Transverse section showing Extra Renal Pelvis (A), Common Iliac artery (B), Common iliac vein (C), L5 (D)

After discussion at the Vascular Surgical MDT the options for treatment were: surgical/suction thrombectomy; catheter directed thrombolysis/percutaneous mechanical thrombectomy +/- stent placement; or anticoagulation. Given the patients advanced age, ongoing septicaemia, and medical co-morbidities the final MDT decision was for conservative medical treatment with anticoagulation. As the patient had no evidence of a pulmonary embolus, a decision was made not to insert an Inferior Vena Cava (IVC) filter. Sadly, she passed away a week later with worsening chest sepsis not responsive to active treatment.

3 Discussion

Proximal DVTs are defined as those superior to the popliteal vein and are not uncommon, although rarer than distal DVT. The commonest causes are immobility secondary to critical care^[1], post-surgery^[2], stroke and thrombophilia syndromes^[3]. Investigations include duplex ultrasonography or CT venography, and the commonest treatment is anticoagulation. The main concern with proximal DVTs is embolization to the pulmonary vasculature and hence the rationale for IVC filtration in selected cases.

Deep vein thrombosis formation caused by extrinsic compression of the left common iliac vein between the overriding contralateral (right) common iliac artery and adjacent lumbar vertebrae is known as May-Thurner Syndrome^[4, 5]. It is thought that the physical compression of the vein and the pulsations of the artery cause intimal thickening of the vein leading to endothelial dysfunction and turbulent flow through the vessel therefore fulfilling two of Virchow's Triad of factors that lead to thrombosis. This overlap of the left common iliac vein by the right common iliac artery means that the left leg is the more commonly affected limb. More recently, May-Thurner syndrome encompasses iliac lesions affecting both sides and is known as non-thrombotic iliac vein lesions (NIVL)^[6].

Symptoms are the same as for other DVT's- namely, acute pain, swelling of the leg and skin changes including venous ulceration.

Our case is not classical May-Thurner syndrome and would more likely be classified as an NIVL. In our case compression of the left common iliac vein, on its oblique course to the IVC, was caused by a heavily calcified ipsilateral (left) common iliac artery compressing the vein against an L5 osteophyte rather than from the contralateral (right) common iliac artery. This is an interesting pathological variant and not one reported before. Complicating this case further is the discovery of a pelvic kidney. In one case report by Eng JM, et al a child with a pelvic kidney developed a DVT with clinical findings consistent with May-Thurner Syndrome^[7]. However, on radiological review the impression was that the pelvic kidney in our patient was likely contributing to venous compression indirectly by splinting the left common iliac artery rather than by direct pressure.

It is well known that the anatomical variant of an overriding right common iliac artery causing May-Thurner is present in approximately 20% of the population having been found in 22% of cadavers at autopsy in the 1950's^[8]. The low incidence of May-Thurner in those with a confirmed DVT may be due to the fact that there are more common causes of DVT, such as prolonged immobility either from travel or bed rest, malignancy, and the oral contraceptive pill^[9]. Therefore, once a DVT is diagnosed and attributed to a more common cause, no further investigation is warranted and it's true cause may be missed. Diagnosis in the acute setting is often with ultrasonography, which is not very effective at visualising the pelvis. Imaging modalities such as CT Venography, MRI and intravenous ultrasound are rarely used without specialist input.

The treatment options for this case of May-Thurner-like Syndrome follow in the same vein as the recognised treatment of May-Thurner. If left untreated, symptoms can persist along with complications such as post-thrombotic syndrome^[10, 11]. Anticoagulation alone does not treat the underlying cause of obstructive thrombus but does prevent thrombus propagation and pulmonary embolus^[10], and systemic thrombolysis although effectively treating the clot, is associated with an unacceptable risk of major bleeding. Surgical thrombectomy alone has been shown to be associated with a high risk of recurrence with up to 70% developing re-occlusion after treatment^[12]. One study revealed good results for surgical thrombectomy followed by stenting in 8 patients with May-Thurner Syndrome^[13]. Indeed, Kolbel T, et al showed a 79% patency rate at 25 months in patients treated with stenting for NIVL with a 67% symptomatic improvement^[14].

The literature on known cases of May-Thurner-like syndrome suggests the best course of treatment is catheter-directed thrombolysis closely followed by insertion of a stent to maintain vessel patency^[15]. This has been shown to result in good patency of vessels at follow-up, and a reduction of complications, namely, post-thrombotic syndrome and major bleeding^[15, 16].

The surgical treatments in other studies have taken place in younger patients, less than 60 years old. Our patient was 87 years of age with concurrent severe community acquired pneumonia with resultant fast atrial fibrillation and acute kidney injury requiring medical HDU admission. Furthermore, she was not experiencing any symptoms other than leg swelling. After extensive discussion in the vascular MDT meeting it was decided that she was not for aggressive surgical management and was to be managed medically with anticoagulation.

References

- [1] Panitchote, A, Chaiyasoot, W, and Permpikul, C. Prevalence and incidence of proximal deep vein thrombosis in critically ill patients. *Crit Care*. 2010; 14 (Suppl 1): 359. <http://dx.doi.org/10.1186/cc8591>
- [2] Nathan, S et al. The incidence of proximal deep vein thrombosis following total knee arthroplasty in an Asian population: A Doppler ultrasound study. *Journal of Orthopaedic Surgery*. 2003; 11(2): 184-189
- [3] Rossi, E et al. The risk of symptomatic pulmonary embolism due to proximal deep venous thrombosis differs in patients with different types of inherited thrombophilia. *Thromb Haemost*. 2008 Jun; 99(6): 1030-4. <http://dx.doi.org/10.1160/TH08-02-0069>
- [4] May R, Thurner J. The cause of the predominantly sinistral occurrence of thrombosis of the pelvic veins. *Angiology*. 1957; 8 (5): 419-27. <http://dx.doi.org/10.1177/000331975700800505>
- [5] Mousa AY, AbuRahma AF. May-Thurner syndrome: update and review. *Ann Vasc Surg*. 2013 Oct; 27(7): 984-95. <http://dx.doi.org/10.1016/j.avsg.2013.05.001>

- [6] Raju S, Neglen P. High prevalence of nonthrombotic iliac vein lesions in chronic venous disease: a permissive role in pathogenicity. *J Vasc Surg.* 2006 Jul; 44(1): 136-43. <http://dx.doi.org/10.1016/j.jvs.2006.02.065>
- [7] Eng JM, et al. An unusual presentation of May-Thurner syndrome in a pediatric patient with a pelvic kidney. *J Pediatr Urol.* 2013 Feb; 9(1): e72-5. <http://dx.doi.org/10.1016/j.jpuro.2012.08.014>
- [8] Peters, M et al. May-Thurner syndrome: a not so uncommon cause of a common condition. *Proc (Bayl Univ Med Cent).* 2012 Jul; 25(3): 231-3.
- [9] Oguzkurt L, et al. Computed tomography findings in 10 cases of iliac vein compression (May-Thurner) syndrome. *Eur J Radiol.* 2005 Sep; 55(3): 421-5. <http://dx.doi.org/10.1016/j.ejrad.2004.11.002>
- [10] Ibrahim, W et al. Endovascular Management of May-Thurner Syndrome. *Ann Vasc Dis.* 2012; 5(2): 217-221
- [11] Dheer, S, Joseph, AE, Drooz, A. Retroperitoneal Hematoma Caused by a Ruptured Pelvic Varix in a Patient with Iliac Vein Compression Syndrome. *Journal of Vascular and Interventional Radiology.* 2003 March; 14(3): 387-390. <http://dx.doi.org/10.1097/01.RVI.0000058411.01661.2b>
- [12] Al-Nouri, O and Milner, R. May-Thurner Syndrome. *Vascular Disease Management.* 2011 March; 8(3).
- [13] Igari K, et al. Surgical Thrombectomy and Simultaneous Stenting for Deep Venous Thrombosis Caused by Iliac Vein Compression Syndrome (May-Thurner Syndrome). *Ann Thorac Cardiovasc Surg.* 2013 Nov 27. <http://dx.doi.org/10.5761/atcs.0a.13-00213>
- [14] Kölbel, T et al. Chronic Iliac Vein Occlusion: Midterm Results of Endovascular Recanalization. *Journal of Endovascular Therapy.* 2009 August; 16 (4).
- [15] Patel, NH et al. Endovascular management of acute extensive iliofemoral deep venous thrombosis caused by May-Thurner syndrome. *J Vasc Interv Radiol.* 2000 Nov-Dec; 11(10): 1297-302. [http://dx.doi.org/10.1016/S1051-0443\(07\)61304-9](http://dx.doi.org/10.1016/S1051-0443(07)61304-9)
- [16] Beard JD, Gaines PA, Loftus Ian. *Vascular and Endovascular Surgery.* 5th rev. ed. Amsterdam: Elsevier; 2014.