

CASE REPORT

Parathyroid hormone independent hypercalcemia in the setting of non metastatic leiomyosarcoma

Jennifer Swenski ¹, Rod Marianne Arceo-Mendoza ², Radhika Gogoi ³, Mikhail Signalov ⁴

1. Department of Obstetrics and Gynecology, Geisinger Medical Center, Danville, USA. 2. Department of Endocrinology, Loyola University Medical Center, Maywood, USA. 3. Department of Gynecology Oncology, Geisinger Medical Center, Danville, USA. 4. Department of Endocrinology, Geisinger Medical Center, Danville, USA

Correspondence: Jennifer Swenski. Address: Geisinger Medical Center 100 N. Academy Ave Danville PA, USA. Email: jmswenski@geisinger.edu

Received: January 13, 2014

Accepted: February 20, 2014

Online Published: March 13, 2014

DOI: 10.5430/crim.v1n2p25

URL: <http://dx.doi.org/10.5430/crim.v1n2p25>

Abstract

Background: We present an atypical case involving humoral hypercalcemia of malignancy arising in a patient with non-metastatic leiomyosarcoma. Cases of hypercalcemia of unknown source should prompt suspicion for rare tumors.

Case: A 56 year old woman requires hospitalization for hypercalcemia with low intact parathyroid hormone where renal ultrasound incidentally reports a uterine fibroid. Previous workup for a 9 month history of postmenopausal vaginal bleeding was found to be negative. Bone scan, computed tomography chest, mammogram, ultrasound of thyroid were negative. Dilatation and curettage revealed leiomyosarcoma. Hysterectomy causes complete resolution of her hypercalcemia.

Conclusions: Parathyroid hormone independent hypercalcemia in the setting of uterine mass should raise suspicion for paraneoplastic syndrome with biochemical and surgical workup to exclude leiomyosarcoma.

1 Background

Leiomyosarcoma is a rare malignant uterine smooth muscle tumor and comprises 30% of uterine sarcomas. These tumors usually arise anew from the myometrium with malignant transformation of an existing leiomyoma noted as a rare occurrence. Treatment is surgical and includes a total abdominal hysterectomy with a bilateral salpingo-oophorectomy. Studies have shown no proven benefit for overall survival for chemotherapy or radiation therapy. Although controversial, some studies have shown pelvic radiation to be beneficial for local tumor control ^[1].

Paraneoplastic syndromes are disorders that occur simultaneously with a benign or malignant tumor. They are not caused by direct tumor invasion or mass effect; but rather by the ability of the tumor to produce or stimulate peptides, hormones, or immunological responses. Humoral hypercalcemia of malignancy is an example of this syndrome and refers to the ectopic production of parathyroid hormone-related protein by squamous cell cancers of the lung, skin, head/neck; breast cancer, renal cell cancer, Human T-Cell lymphotropic virus associated lymphoma, ovarian, and endometrial cancer ^[2]. Humoral hypercalcemia of malignancy is suspected in the setting of parathyroid independent hypercalcemia and the presence of a neoplasm ^[3].

2 Case

A 56 year old gravida 3 para 3003 postmenopausal Caucasian woman reported for follow-up gynecological exam in September for postmenopausal bleeding for the past 9 months. Endometrial biopsy in April was negative. She stated that the vaginal bleeding continues daily. She was scheduled to undergo pelvic ultrasound; however she was hospitalized prior to ultrasound after reporting several weeks of debilitating malaise, weakness and nausea. Routine lab workup revealed an elevated serum calcium level of 16.8 mg/dL. Her Electrocardiogram revealed no QT prolongation. Additional initial work-up included a low intact parathyroid hormone of 8 pg/mL. Serum protein electrophoresis was negative. Initial chest x-ray was normal and subsequent computed tomography of the chest was significant for mild interstitial lung disease but revealed no pulmonary nodules or acute process. Mammogram was negative. Bone scan and ultrasound of her thyroid was also found to be negative. Incidental finding on renal ultrasound showed what appeared to be a large uterine fibroid. After aggressive IV hydration and administration of IV Pamidronate, she was discharged to home with scheduled follow-up with Endocrinology and Gynecology. The patient's past medical history was significant for melanoma in situ of her left arm which was completely excised and hypothyroidism. Health maintenance evaluation was up to date with a recently negative Pap smear, mammogram, and colonoscopy. Gynecological evaluation was significant for atrophic vaginal mucosa with an enlarged, approximately 9 week size uterus on bimanual pelvic exam. Cervix was visibly dilated to 1-2 cm.

A transvaginal and transabdominal pelvic ultrasound was completed. Uterus was noted to measure 14.8 cm × 7.5 cm × 8.4 cm with a thickened heterogeneous endometrial stripe, which appeared to be a mass extending into the canal and highly suspicious for endometrial malignancy.

Computed tomography abdomen and pelvis was significant for an endometrial mass approximately 8.3 cm × 6.9 cm × 5.6 cm with distention of the endometrial canal (that) probably invades more than half of the myometrial thickness. No definite extension outside the uterus and no adnexal mass was identified (see Figure 1). A diagnostic hysteroscopy, dilatation and curettage was scheduled.

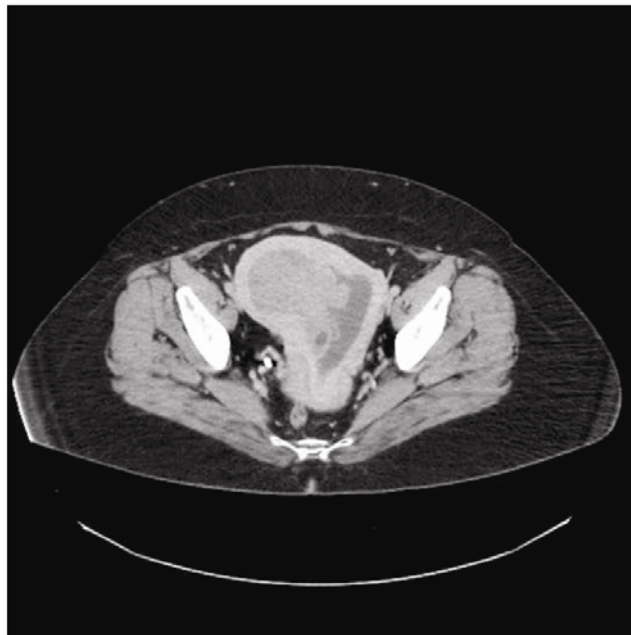

Figure 1. CT Abdomen/Pelvis with IV and Oral Contrast. Uterine mass measuring 8.3 cm × 6.9 cm × 5.6 cm consistent with endometrial neoplasm.

Outpatient Endocrinology follow-up revealed persistently elevated serum calcium of 11.9 mg/dL. 24 hour urine calcium was 0.595 g/24 hours. Intact parathyroid hormone again was found to be suppressed at 7 pg/mL. Parathyroid hormone related peptide was drawn at the national lab and found to be significantly elevated at 60 pg/mL (normal range 14-27). 25 Hydroxy Vitamin D level was 31.8 ng/mL. Suspicion was raised for a case of humoral hypercalcemia of malignancy. Taking into consideration her previous negative workup for tumors typically associated with parathyroid hormone related peptide elevation, attention was directed to the uterine mass.

Hysteroscopy showed difficulty visualizing a discrete mass or polyp, but with noted abnormal contour of the endometrial lining. Curettage performed revealed “polypoid” like tissue. Final pathology reported high grade leiomyosarcoma (see Figure 2). The patient was promptly referred to Gynecology Oncology for further evaluation and treatment. She underwent an exploratory laparotomy, total abdominal hysterectomy, bilateral salpingo-oophorectomy, and peritoneal washings. Findings at the time of surgery showed 8 weeks size uterus with normal appearing tubes and ovaries. No evidence of pelvic or peri-aortic lymphadenopathy was appreciated. Frozen section analysis of the uterus revealed a uterine leiomyosarcoma with less than 50% invasion. No evidence of extrauterine disease was identified, and at the conclusion of the procedure no gross residual disease remained. Final Pathology confirmed the diagnosis, and the stage was IB Leiomyosarcoma. On postoperative day 16, repeat lab work was performed. Hypercalcemia resolved with a serum calcium of 8.6 mg/dL. Intact parathyroid hormone was slightly elevated 68 pg/mL (normal range 15-65) likely secondary to rebound physiologic elevation following suppression. Parathyroid hormone related peptide was found to be normal at 18 pg/mL. She was subsequently evaluated by Radiation Oncology. Discussion was held regarding the controversial role of post-operative radiation on leiomyosarcoma and the lack of literature suggesting increased rate of overall survival although possible suggested improvements in local control. After lengthy discussion involving risks and benefits, the patient opted not to receive radiation.

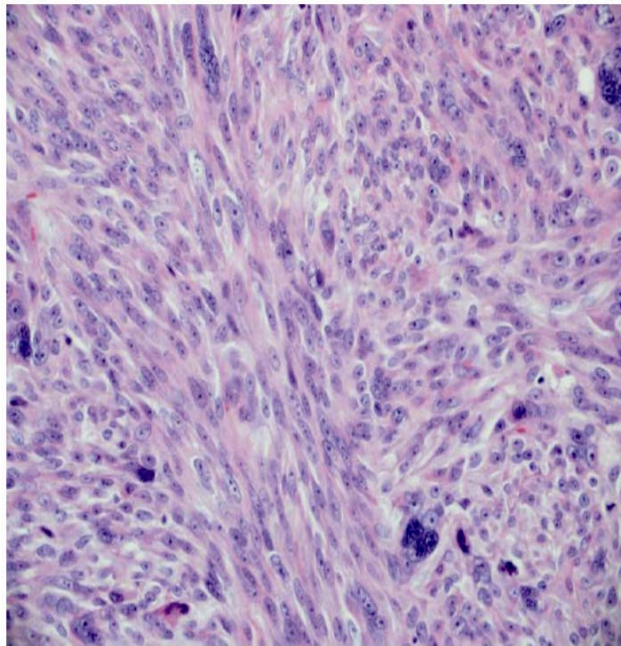


Figure 2. Frozen section of tumor fragments. Poorly differentiated tumor with spindled cell and epithelioid cell morphology consistent with high grade leiomyosarcoma. Stain: Hematoxylin and Eosin. Magnification: $\times 400$

3 Comment

An Ovid Medline search was conducted between the years of 1988 and 2011 using “Leiomyosarcoma” and “Parathyroid hormone-related protein” as keywords combined using “AND”. To the best of our knowledge, this is the first reported case of

hypercalcemia secondary to ectopic Parathyroid hormone related peptide in a patient with leiomyosarcoma without documented evidence of metastasis. This is only the third reported case of a leiomyosarcoma causing humoral hypercalcemia of malignancy. Tang et al reported a case involving a 61 year old women with metastatic leiomyosarcoma s/p tumor debulking 10 years prior to presentation of parathyroid hormone related peptide dependent hypercalcemia [4]. In addition, Nagata et al also reported humoral hypercalcemia of malignancy after lung metastasis occurred in a patient with leiomyosarcoma [5].

There are a three published case reports of leiomyoma associated hypercalcemia with increased parathyroid hormone related peptide. Tarnawa et Al reported a 32 year old pregnant women who required ICU admission for severe hypercalcemia during pregnancy which was only cured after postpartum myomectomy and was found to be due to an elevated parathyroid hormone related peptide presumed caused by the benign tumor [6].

Our case demonstrates that the presence of unexplained parathyroid hormone independent hypercalcemia requires additional evaluation to exclude rare tumors. Staining for parathyroid hormone related peptide is not currently commercially available, but could be helpful in the evaluation of such patients described above who may previously be categorized as idiopathic hypercalcemia. As demonstrated by the remission of hypercalcemia after removal of leiomyosarcoma, the management and treatment of her disease was dependent upon consideration of nontraditional causes of parathyroid hormone related peptide production [7].

Source: Patient, Geisinger Medical Center

Disclosure

The authors have nothing to disclose regarding financial support for this study or funding received for this work from any organization.

Acknowledgements

This case was presented as a poster abstract at the American Association of Clinical Endocrinologists 21st Annual Scientific and Clinical Congress on May 23-27 2012 in Philadelphia, Pennsylvania.

References

- [1] Berek, H. and N. Hacker. Smooth muscle tumors. In: Berek and Hacker editors. *GynecologyOncology*. 5th ed. Philadelphia (PA): Lippincott Williams & Wilkins; 2010. 430-433 p.
- [2] Stewart, A. F. Hypercalcemia Associated with Cancer. *New England Journal of Medicine*. 2005 January; 352: 373-379.
- [3] Fauci, A, et al. Paraneoplastic Syndromes: Endocrinology/Hematologic. *Harrison's Principles of Internal Medicine*. 17th ed. New York: The McGraw-Hill Companies, Inc.; 2008. 617-619 p.
- [4] Tang, S., et al. Parathyroid Hormone-Related Protein-Secreting Metastatic Epithelioid Leiomyosarcoma. A case report and review of the literature. *Archives of Pathology & Laboratory Medicine*. 2003 Apr; 127(4):e181-5.
- [5] Nagata, N., et al. A Case of Leiomyosarcoma Associated with Humoral Hypercalcemia of Malignancy: Demonstration of Biological and Immunological Activities of Parathyroid Hormone-Related Protein in the Tumor Extract. *Japanese Journal of Cancer Research*. 1989 Jul; 80(7):643-8.
- [6] Tarnawa E., et al. Severe Hypercalcemia Associated with Uterine Leiomyoma in Pregnancy. *Obstetrics & Gynecology*. 2011 Feb; 117(2): 473-476.
- [7] Jacobs, T. and J. Bilezikian. Clinical Review: Rare Causes of Hypercalcemia. *The Journal of Clinical Endocrinology & Metabolism*. 2005 August; 90 (11): 6316-6322.