

CASE REPORTS

Atypical Amiodarone toxicity: Iatrogenic ataxia and dysarthria in an elderly female

Amanda Warren^{*1,2}, Dana Lin^{1,2}, Ashlyn Katz^{1,2}, Pola Bozak^{1,2}

¹School of Medicine, St. George's University, True Blue, Grenada

²Department of Internal Medicine, The Brooklyn Hospital Center, Brooklyn, United States

Received: October 19, 2020

Accepted: December 23, 2020

Online Published: January 8, 2021

DOI: 10.5430/crim.v7n4p13

URL: <https://doi.org/10.5430/crim.v7n4p13>

ABSTRACT

Amiodarone is one of the most frequently used antiarrhythmic drugs on the market, treating both life-threatening ventricular arrhythmias as well as supraventricular tachyarrhythmias. Some of its most commonly known side effects include corneal deposits, cardiac toxicity, pneumonitis, thyroid hormone fluctuation, and dermatological reactions. Despite the frequency of occurrence of neurological complications secondary to Amiodarone they remain to be under-recognized by healthcare professionals. This case report aims to increase awareness of the neurological complications of Amiodarone.

Key Words: Amiodarone toxicity, Cerebellar ataxia, Neurological side effects

1. INTRODUCTION

Amiodarone has a wide range of side effects that can potentially cause toxicity to vital organs. At its extremes the agent can cause cardiac toxicity, pneumonitis, and has even led to sudden cardiac death. Given the agent's significant side effect load, the Food and Drug Administration issued 4 boxed warnings for the agent, including risk of worsened arrhythmia, life threatening arrhythmia, hepatotoxicity, and pulmonary toxicity. The medication is also famously known to cause dysfunction in thyroid metabolism as well. The extent of the side effect load of the agent demands regular patient monitoring and baseline testing to ensure changes in cardiac, pulmonary, liver function, and thyroid function tests are quickly recognized when they occur. Certainly, these are but a few of the organ systems that are affected by Amiodarone. Other well-recognized reactions to the agent that require monitoring included optic neuropathy, corneal microdeposits, and photosensitivity. One of the lesser known

adverse effects of the drug is neurotoxicity. That is likely because neurotoxicity more commonly occurs in the geriatric population, as the elderly are overall more neurologically sensitive to the medication.^[1] Due to the lack of recognition of this serious and life-altering side effect, here we document a case of amiodarone induced neurotoxicity in an elderly woman treated for paroxysmal atrial fibrillation.

2. CASE PRESENTATION

A 70 year old African American female with a past medical history of paroxysmal atrial fibrillation, hypertension (HTN), Type 2 Diabetes Mellitus (DM2), and cardiovascular accident (CVA) in 1980, with residual right sided weakness presented to the emergency department on 23 November 2019, with complaints of progressive generalized weakness and dizziness. The patient complained of unsteady gait and imbalance, which progressively reduced her ability to ambulate prompting her to seek further medical evaluation. The patient was

*Correspondence: Amanda Warren; Email: awarren@sgu.edu; Address: 121 Dekalb Ave, Brooklyn, NY 11201, United States.

previously admitted for less severe, yet similar symptoms and discharged on 18 October 2019, due to unknown etiology after testing was noted to be unremarkable.

On initial evaluation, the patient presented with significant cerebellar ataxia that she stated became pronounced two days prior to admission. She was unable to ambulate and had a severe orthostatic tremor and rotational gyration of the upper torso upon standing. Physical examination was positive for dysmetria, ataxia, and severe dysarthria. A mild resting tremor of the upper extremities was noted bilaterally. Finger-to-nose test was abnormal with significant overshooting present bilaterally. Patient maintains a wide based gait when standing. Heel-to-shin testing revealed undershooting and overshooting of target with jerky movements elicited on both sides. Patient is oriented to person, place, and time. Cranial nerve 1 (olfactory nerve) was not tested. Physical exams testing cranial nerves 2-12 demonstrated no focal neurological deficits, with the exception of cranial nerve 8. The patient was noted have right-sided sensorineural hearing loss. Musculoskeletal examination revealed strength of 4/5 in the right upper extremity, 5/5 in left upper extremity, 5/5 in lower extremities bilaterally and sensation intact throughout. Additional physical examination including respiratory, cardiovascular, gastrointestinal, and thyroid examination were unremarkable.

A full workup was completed in order to evaluate the patient's current medical status. Computed tomography (CT)

of the head without contrast, CT angiography of the brain with contrast, and CT angiography of the neck with contrast were all completed upon admission and did not show any acute pathology. The patient also had a magnetic resonance imaging (MRI) of the brain performed on 21 November 2019 by her primary care provider, which noted evidence of mild microvascular ischemic changes, but no acute pathology, and was unchanged in subsequent imaging obtained 29 November 2019, after admission. Imaging showed no evidence of central lesion. The patient's lab work remained within normal limits throughout her duration of stay in the hospital.

After further investigation, it was revealed that the patient was recently started on a loading dose of Amiodarone 200 milligram tablets 2x/day, two weeks prior to the onset of her symptoms. Amiodarone was discontinued 2 December 2019, and the patient's symptoms significantly improved. The day after stopping the medication there was evident improvement in the patient's dysarthria. Three days after discontinuing the medication all tremors had ceased and the patient was able to ambulate a short distance with assistance. The patient continues to be observed on telemetry floor after discontinuation of Amiodarone and daily electrocardiograms (EKGs) are obtained in order to monitor the patient's cardiac activity. See Figure 1 and Figure 2 for comparison. EKGs exhibited sinus tachycardia with no changes from prior. The patient's symptoms appeared to wax and wane with no identifiable pattern, but she returned to her baseline mental status.

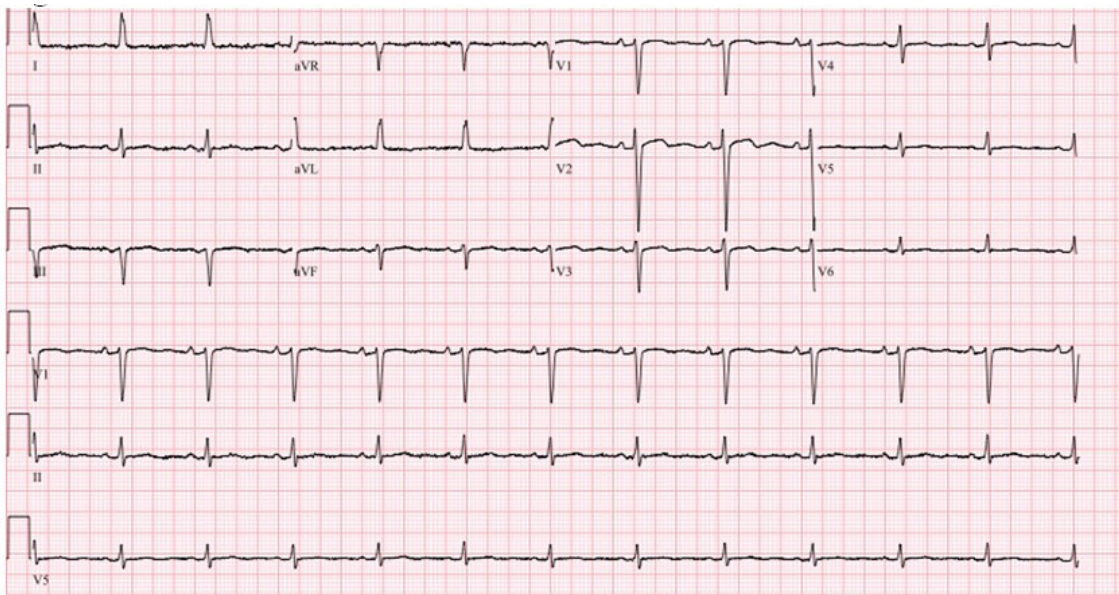


Figure 1. The EKG exhibits a normal sinus rhythm with a nonspecific T-wave abnormality. EKG also displays a ventricular rate of 72 beats per minute, PR interval of 160 milliseconds, ARS duration of 86 milliseconds, QT/QTc of 256/389 milliseconds, and P-R-T axes of 55, -17, 76.

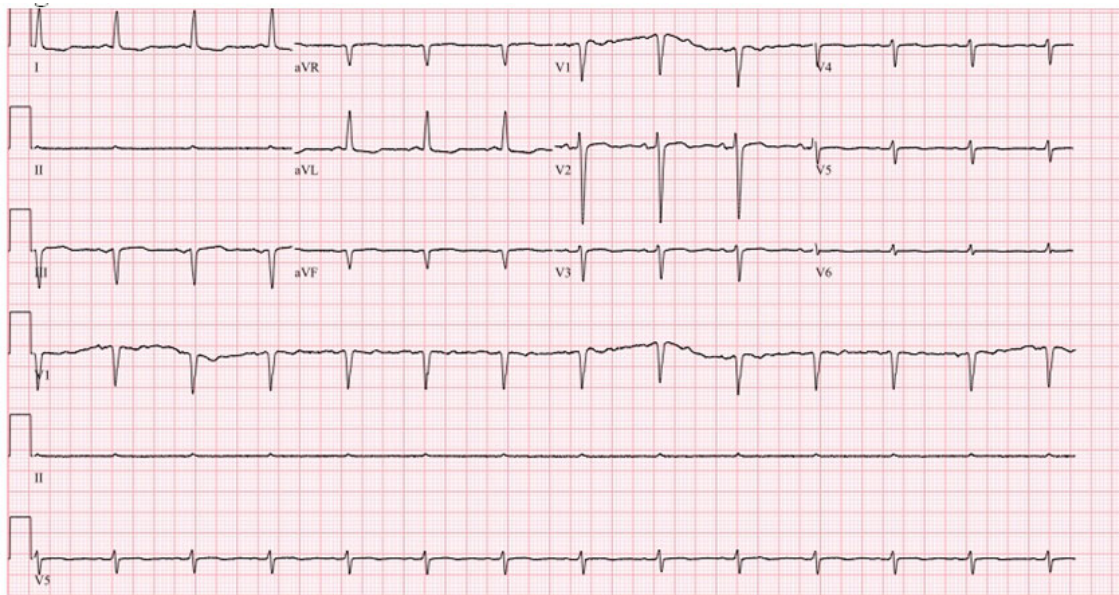


Figure 2. This EKG as compared to the one on 1 December 2019 displays an ectopic atrial rhythm with a new inferior infarct. EKG also displays a ventricular rate of 80 beats per minute, PR interval of 146 milliseconds, QRS duration of 92 milliseconds, QT/QTc of 314/362 milliseconds, and a P-R-T axes of 152, -27, 152.

3. DISCUSSION

Typical management of supraventricular tachycardias may include initial vagotonic maneuvers, IV adenosine, IV calcium channel blockers or beta blockers in order to terminate the arrhythmia and slow the ventricular response. Amiodarone can also be utilized to prevent sudden cardiac death secondary to arrhythmias and is effective in treating atrial arrhythmias. In patients with wide complex tachycardias that are hemodynamically stable, some cardiologists may opt for pharmacologic cardioversion with drugs such as amiodarone. This drug is often utilized when recurrent ventricular tachycardia or wide complex tachycardias are present with uncertain etiology. The half life of Amiodarone is roughly 25-100 days which increases its risk of potential adverse effects. Typically patients are at an increased risk of adverse effects when taking the oral form of the medication as opposed to IV, as tissue accumulation of the drug is not seen in short term use with IV amiodarone. As a result it is important to establish baseline testing and monitor patients carefully that are taking amiodarone. Amiodarone is an antiarrhythmic agent that causes a prolonged action potential of both atrial and ventricular tissue by acting as a noncompetitive antagonist of alpha- and beta-adrenergic receptors.^[2] It can be used for ventricular and supraventricular tachyarrhythmias in patients with left ventricular dysfunction, structural heart disease or coronary artery disease. Amiodarone is primarily a class 3 antiarrhythmic, which blocks potassium rectifier currents, allowing for prolonged effective refractory period in cardiac myocytes. However, unlike other class 3 agents, amiodarone

can block Calcium channels, Beta adrenergic channels and Sodium channels. These extra modes of action allow amiodarone to be used to treat a wide array of arrhythmias, but it can also cause cardiac adverse events such as hypotension, bradycardia and Torsades de pointes.^[3] Other adverse effects include corneal deposits, hypothyroidism/hyperthyroidism, dermatologic side effects, pulmonary fibrosis, liver toxicity and neurological disturbances including cerebellar dysfunction, as seen in this case.^[4] In Raeder, Podrid, and Lown's study on Side effects and Complications of Amiodarone therapy, 8.3% of patients had to discontinue amiodarone use after developing side effects involving thyroid dysfunction, visual disturbances, pulmonary infiltrates, ataxia, cardiac conduction abnormalities, and drug interactions.^[5] The mechanism for amiodarone induced neurotoxicity is not well understood, however amiodarone is known to cross the blood-brain barrier easily due to its lipophilic structure.^[6] One contemporary study reports that the mechanism could be due to bilateral vestibulopathy caused by amiodarone.^[7] Ataxia and gait disturbances as seen in this case have been reported in prior studies. Commonly seen in these patients is consumption of large doses of amiodarone and older patient age.^[8] Serum drug levels have also been found to be higher in symptomatic patients regardless of dose.^[5] Patients can still suffer from neurotoxicity and other side effects for several months after long-term use of amiodarone. After the drug has been discontinued patients tend to have marked improvements in symptoms and have a full recovery within 3-5 months. This delay in full recovery is due to amiodarone's long half-

life secondary to the drug's lipophilic nature as previously discussed.^[6]

Due to the many potential side effects of amiodarone including its neurological side effects, the lowest therapeutic dose should be used in patients. When patients who have been given amiodarone are being screened for side effects, a neurologic examination should be included for all patients, and especially those in the geriatric population, just as patients are screened for pulmonary fibrosis and liver toxicity.^[9] Another alternative to amiodarone use is the possible use of Dronedarone, a benzofuran amiodarone derivative, which has been structurally modified to be less lipophilic, have a shorter half-life, and possibly reduce many of the toxicities associated with long term amiodarone use.^[10,11] In conclusion, Amiodarone is a very effective, commonly used antiarrhythmic, with a myriad of serious side effects that can last for months after discontinuation of the drug including cerebellar ataxia, as seen in this patient.^[12] Because of this, one should weigh the pros and cons of the use of amiodarone and if used, patients should be carefully monitored to make sure they are taking the lowest effective dose and be screened adequately to avoid negative side effects.

4. CONCLUSION

Amiodarone is lipid soluble with an extensive half-life and is capable of causing a myriad of adverse effects. As a result, it is important to be aware of the maximum therapeutic dosage to catch amiodarone-induced neurotoxicity early on, as the neurotoxic side effects of the drug wear off more quickly if there is less stored in the body. It's possible that this phenomenon has a higher prevalence in the geriatric population, one of the requirements for elderly patients taking amiodarone should be to assess for ataxia, paresthesias, sensorineural hearing loss, and other neurological deficits.^[1] Patient's started on a loading dose of Amiodarone, especially in the elderly population, should be instructed to look out for associated toxicity symptoms, and advised to see their cardiologist and discontinue the drug should they appear. Patients should also be counseled on the importance of close follow up when initiating treatment with Amiodarone, as dose reduction is possible once target levels have been accomplished and to prevent incorrect dosing in patients.

CONFLICTS OF INTEREST DISCLOSURE

The authors have declared no conflicts of interest.

REFERENCES

- [1] Hindle JV, Ibrahim A, Ramaraj R. Ataxia caused by amiodarone in older people. *Age Ageing*. 2008 May; 37(3): 347-8. PMID:18385185. <https://doi.org/10.1093/ageing/afn063>
- [2] Sloskey GE. Amiodarone: a unique antiarrhythmic agent. *Clin Pharm*. 1983; 2(4): 330-340.
- [3] Kodama I, Kamiya K, Toyama J. cellular electropharmacology of amiodarone. *Cardiovascular research*. 1997; 35(1): 13-29. [https://doi.org/10.1016/S0008-6363\(97\)00114-4](https://doi.org/10.1016/S0008-6363(97)00114-4)
- [4] Hindle JV, Amin I, Radhakrishnan R. Ataxia caused by amiodarone in older people. *Age and Ageing*. 2008; 37(3): 347-348. PMID:18385185. <https://doi.org/10.1093/ageing/afn063>
- [5] Ernst AR, Philip JP, Bernard L. Side effects and complications of amiodarone therapy. *American Heart Journal*. 1985; 109(5): 975-983. [https://doi.org/10.1016/0002-8703\(85\)90238-8](https://doi.org/10.1016/0002-8703(85)90238-8)
- [6] Aronson JK. *Meyler's Side-Effects of Drugs*. 2006. 15th edition. Elsevier pg.154.
- [7] Gurkov R. Amiodarone: a newly discovered association with bilateral Vestibulopathy. *Front Neurol*. 2018; 9: 119. PMID:29559948. <https://doi.org/10.3389/fneur.2018.00119>
- [8] Orr CF, Ahlskog JE. Frequency, characteristics, and risk factors for amiodarone neurotoxicity. *Arch Neurol*. 2009; 66(7): 865-9. PMID:19597088. <https://doi.org/10.1001/archneuro.1.2009.96>
- [9] Park HS, Kim YN. Adverse effects of long-term amiodarone therapy. *Korean J Intern Med*. 2014; 29(5): 571-573. PMID:25228830. <https://doi.org/10.3904/kjim.2014.29.5.571>
- [10] Danielle G, Angela CL. Dronedarone: A New Antiarrhythmic Agent for the Treatment of Atrial Fibrillation. *Cardiology in Review*. 2009; 17(5): 230-234. PMID:19690474. <https://doi.org/10.1097/CRD.0b013e3181b15ab9>
- [11] Somani P. Basic and clinical pharmacology of amiodarone: relationship of antiarrhythmic effects, dose and drug concentrations to intracellular inclusion bodies. *J Clin Pharmacol*. 1989 May; 29(5): 405-12. PMID:2544634. <https://doi.org/10.1002/j.1552-4604.1989.tb03352.x>
- [12] Florek JB, Girzadas D. *Amiodarone*. StatPearls. Treasure Island (FL): StatPearls Publishing; 2019 Jan.