

## CASE REPORTS

# Polyarteritis nodosa: An unusual cause of life-threatening intra-abdominal bleeding

Koen Verdonk<sup>1</sup>, Jeroen G.J. Jonkman<sup>2</sup>, Adriaan Dees\*<sup>1</sup>

<sup>1</sup>Department of Internal Medicine, Ikazia Hospital, Rotterdam, The Netherlands

<sup>2</sup>Department of Radiology, Ikazia Hospital, Rotterdam, The Netherlands

**Received:** September 26, 2019

**Accepted:** November 18, 2019

**Online Published:** November 25, 2019

**DOI:** 10.5430/crim.v6n4p23

**URL:** <https://doi.org/10.5430/crim.v6n4p23>

## ABSTRACT

Intra-abdominal arterial bleeding is a life-threatening condition, warranting immediate causal therapy. Polyarteritis nodosa is a rare type of necrotizing vasculitis that affects medium-sized arteries. We present a patient with severe arterial bleeding as the first symptom of polyarteritis nodosa. Because the bleeding took place intra-abdominal instead of gastro-intestinal, there was no macroscopic blood loss. She was successfully treated with endovascular coil embolization during angiography.

**Key Words:** Polyarteritis nodosa, Intra-abdominal bleeding, Vasculitis, Coiling

## 1. INTRODUCTION

Intra-abdominal arterial bleeding is a life-threatening condition, warranting immediate causal therapy. Polyarteritis nodosa (PAN), first described in 1866, is a rare type of necrotizing systemic vasculitis that effect medium-sized arteries.<sup>[1]</sup> Gastro-intestinal manifestations are often reported in PAN. Bleeding and perforations due to ischemic vasculitis are the most feared complications and an important cause of death within the first year after PAN presentation.<sup>[2]</sup> We present a patient with severe splenic artery bleeding as the first symptom of PAN.

## 2. CASE REPORT

### 2.1 Case

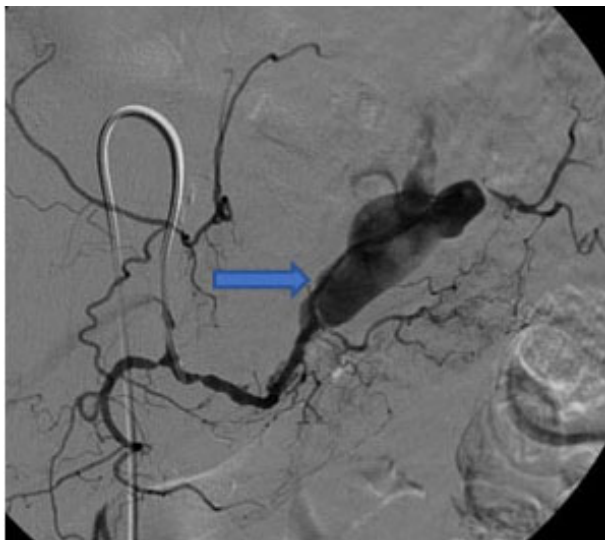
A 74-year-old woman presented at the emergency department because of loss of consciousness. Her medical history included appendectomy and cholecystectomy, and atrium fibrillation under therapeutic anticoagulation with acenocoumarol. She had reported progressive abdominal pain since a week. Furthermore, fatigue and loss of weight were

observed since several weeks. She had no signs of diarrhea, clear blood loss or melena. On admission, she appeared to be pale but hemodynamically stable. The respiratory rate was 16 beats/minute with a saturation of 98% while breathing room air, and the blood pressure was 170/60 mmHg with a pulse rate of 90 beats/min. Her consciousness (EMV score) was normal at the time of examination. Physical examination of the heart and lungs revealed no abnormalities. The abdomen was diffusely tender with normal peristalsis and no abnormal palpable masses. There was a small erythematous skin lesion on the forehead. A neurological examination was unremarkable. Initial laboratory findings revealed normocytic anemia (hemoglobin level: 4.9 mmol/L; normal: 8.5-10.0), which was significantly dropped in comparison to previous examination by her general practitioner (9.2 mmol/L). Her glucose level, kidney function and serum electrolyte tests were normal but liver enzyme tests were slightly elevated. Abdominal pain and anemia without evident signs of blood loss raised the suspicion of intra-abdominal bleeding.

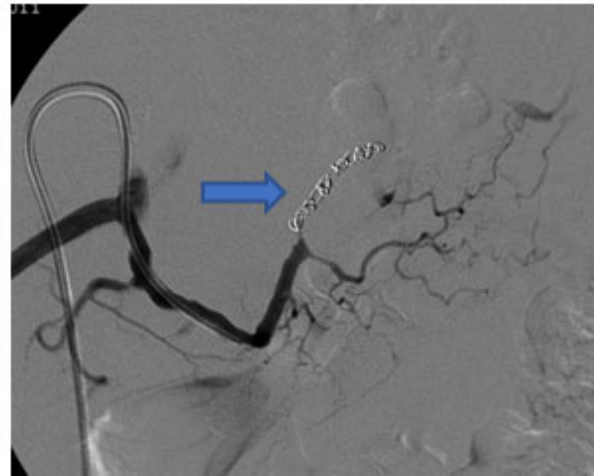
\*Correspondence: Adriaan Dees; Email: [a.dees@ikazia.nl](mailto:a.dees@ikazia.nl); Address: Department of Internal Medicine, Ikazia Hospital, Montessoriweg 1, 3083 AN, Rotterdam, The Netherlands.

### 2.2 Work up

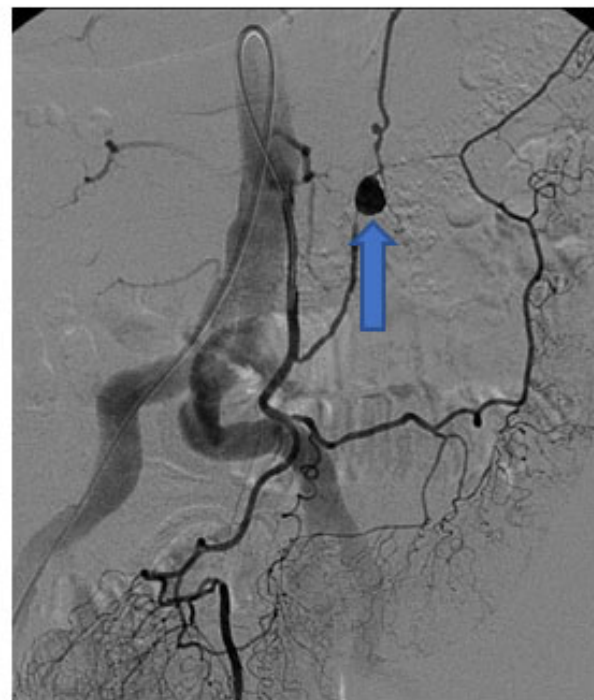
A computed tomography-scan (CT-scan) of the abdomen showed bleeding of an aneurysm of the splenic artery as well as splenic infarction and an origostenosis of the renal arteries. Angiography was performed and showed multiple aneurysms as well as typical narrowing and irregularities of the abdominal arteries. Subsequently, the bleeding site at the splenic artery was confirmed (see Figure 1) and embolized using coiling (see Figure 2). In the workup of the disease all viral (including hepatitis B and C) and autoimmune serological tests remained negative. A chest X-ray showed no abnormalities. A PET-CT scan was performed and showed no pathological uptake, although this was done after a few days of corticosteroid treatment. A biopsy of the erythematous lesion on the forehead, showed a leukocytoclastic vasculitis. According to the ACR criteria, PAN was diagnosed. Therefore treatment with prednisolone (60 mg/day) combined with cyclophosphamide (100 mg/day) was initiated.



**Figure 1.** Angiography showing aneurysmatic bleeding at the splenic artery level



**Figure 2.** Angiography showing successful coiling



**Figure 3.** Abdominal angiography after six months of follow-up, showing a new aneurysma

### 2.3 Follow up

Six months after the patient’s initial presentation, a follow-up CT-scan was performed and showed a novel aneurysma had formed (see Figure 3) in both the superior and inferior arteria mesenterica, with the latter requiring embolization by coiling to prevent further harm. The further clinical course of our patient then was uneventful, except for the development of osteoporosis and pain caused by vertebral compression fractures that were most likely caused by long-term steroid use, despite prophylactic therapy.

### 3. DISCUSSION

Abdominal pain, caused by a spontaneous rupture of an intra-abdominal artery is an exceptional presentation of PAN.<sup>[2,3]</sup> This type of vasculitis, which affects mainly middle-sized arteries, has an incidence rate between 4.4-9.7/million per year. This means that in the Netherlands, there should be only a hundred new patients per year. Approximately 5 of these patients will present with intestinal bleeding or perforation. PAN commonly affects patients in their sixties and men are 1.5 times more likely than women to be affected. Gen-

eral symptoms include fatigue, weight loss and fever, which typically appear gradually over a period of several weeks or months. Although all organs can be involved the kidneys, skin, joints, muscles, nerves, and gastrointestinal tract are most frequently affected. In addition to visceral bleeding, acute limb ischemia and necrotizing vasculitis have been reported in children.<sup>[4-6]</sup> The American College of Rheumatology (ACR) has established 10 criteria that can be useful for differentiating PAN from other diseases that cause vascular inflammation.<sup>[1]</sup> These include mycotic aneurysms, endocarditis with bacteremia embolization, giant cell arteritis or Wegener's vasculitis. However, it should be noted that the ACR criteria are not meant or validated for confirming a diagnosis. A patient is thought to have PAN if at least 3 out of 10 criteria are fulfilled. These are weight loss, skin lesions (livedo reticularis), testicular pain, muscle weakness or tenderness, neuropathies, new-onset hypertension, kidney dysfunction, a recent hepatitis B infection, visceral arteriography abnormalities and a biopsy of small- to medium-sized arteries showing polymorphonuclear cells. Classic PAN is either idiopathic or associated with the hepatitis B virus infection. Although the exact etiology remains elusive for most patients, new investigations have attempted to shed light on the pathophysiology of PAN. Recently, it was shown that loss of Adenosine Deaminase 2 (ADA2) due to a recessive missense mutation of the gene encoding ADA2 is responsible for a new auto inflammatory disease that is indistinguishable from PAN.<sup>[7]</sup> ADA1, another ADA isoform, is known

to cause severe combined immunodeficiency.<sup>[8]</sup> ADA2 loss is common in Jewish Georgian or German families. PAN is highly lethal if untreated, with a 5-year survival rate of 10%, while treatment with corticosteroids and cyclophosphamide increases the 5-year survival rate to 82%.<sup>[2,9,10]</sup> It is important to recognize PAN in time to start early treatment. HBV-negative PAN indicates therapy with prednisone and cyclophosphamide, although newer agents such as infliximab are under investigation.<sup>[6]</sup> The optimal duration of treatment is currently unknown and most studies recommend one year of treatment. In our patient the key point was the radiological image: luminal irregularities, microaneurysms and vascular embolization or occlusions are all highly suggestive of PAN. An initial presentation with spontaneous intra-abdominal bleeding is unusual, but has the risk of a lethal outcome.<sup>[11,12]</sup> This makes adequate diagnosis, by means of visceral angiography, and subsequent (interventional) treatment necessary.<sup>[13]</sup>

#### 4. CONCLUSION

Spontaneous rupture of the splenic artery due to PAN is extremely rare. In cases of an intra-abdominal arterial bleeding of unknown origin PAN should be kept in mind as a treatable cause. Untreated patients have a high mortality rate, which makes adequate diagnosis and subsequent treatment necessary.

#### CONFLICTS OF INTEREST DISCLOSURE

The authors declare no conflict of interest

#### REFERENCES

- [1] Lightfoot RW Jr, Michel BA, Bloch DA, et al. The American College of Rheumatology 1990 criteria for the classification of polyarteritis nodosa. *Arthritis Rheum.* 1990; 33: 1088-93. PMID:1975174. <https://doi.org/10.1002/art.1780330805>
- [2] Pagnoux C, Seror R, Henegar C, et al. Clinical features and outcome in 348 patients with polyarteritis nodosa: a systematic, retrospective study of patients diagnosed between 1963 and 2005 and entered into the French Vasculitis Study Group Database. *Arthritis Rheum* 2010;62:616-26. PMID:20112401. <https://doi.org/10.1002/art.27240>
- [3] Levin S, Graber J, Ehrenwald E, et al. Polyarteritis nodosa-induced pancreaticoduodenal artery aneurysmal rupture. *Int J Angiol.* 2015 Mar; 24(1): 63-66. PMID:25780330. <https://doi.org/10.1055/s-0033-1354306>
- [4] Ebert EC, Hagspiel KD, Nagar M, et al. Gastrointestinal involvement in polyarteritis nodosa. *Clin Gastroenterol Hepatol.* 2008 Sep; 6(9): 960-6. PMID:18585977. <https://doi.org/10.1016/j.cgh.2008.04.004>
- [5] Shukla A, Aggarwal A. Polyarteritis nodosa presenting as peripheral vascular disease and acute limb ischemia. *J Postgrad Med.* 2017; 63: 47-49. PMID:27853042. <https://doi.org/10.4103/0022-3859.194207>
- [6] Lerkvaleekul B, Treepongkaruna S, Ruangwattanapaisam N, et al. Recurrent ruptured abdominal aneurysms in polyarteritis nodosa successfully treated with infliximab. *Biologics.* 2019; 13: 111-116. PMID:31354239. <https://doi.org/10.2147/BTT.S204726>
- [7] Human A, Pagnoux C. Diagnosis and management of ADA2 deficient polyarteritis nodosa. *Int J Rheum Dis.* 2019 Jan; 22 Suppl 1: 69-77. PMID:29624883. <https://doi.org/10.1111/1756-185X.13283>
- [8] Thompson LF, Seegmiller JE. Adenosine deaminase deficiency and severe combined immunodeficiency disease. *Adv. Enzymol Relat Areas Mol Biol.* 1980; 51: 167-210. <https://doi.org/10.1002/9780470122969.ch4>
- [9] de Menthon M, Mahr A. Treating polyarteritis nodosa: current state of the art. *Clin Exp Rheumatol.* 2011 Jan-Feb; 29(1 Suppl 64): S110-6. Epub 2011 May.
- [10] Pagnoux C, Mendel A. Treatment of systemic necrotizing vasculitides: recent advances and important clinical considerations. *Expert Rev Clin Immunol.* 2019 Sep; 15(9): 939-949. PMID:31414912. <https://doi.org/10.1080/1744666X.2019.1656527>

- [11] Roberto M, Meytes V, Liu S. Ruptured hepatic aneurysm as first presenting symptom of polyarteritis nodosa. *Oxf Med Case Reports*. 2018 Feb 22; 2018(2): omx100. PMID:29492271. <https://doi.org/10.1093/omcr/omx100>
- [12] Jagwani AV, Fathi NG, Jailani RF, et al. Rare and unusual case of polyarteritis nodosa involving the gastrointestinal tract leading to bowel gangrene. *BMJ Case Rep*. 2017 Jan 6; 2017. PMID:28062430. <https://doi.org/10.1136/bcr-2016-217865>
- [13] Skeik N, Hyde JR, Olson SL, et al. Nonatherosclerotic Abdominal Vasculopathies. *Ann Vasc Surg*. 2019; 60: 128-146. PMID:31200053. <https://doi.org/10.1016/j.avsg.2019.04.004>