

## CASE REPORTS

# Acute pulmonary embolism concomitant with ST-elevation myocardial infarction in a patient with pancreatic cancer

Wen-Hsien Lee<sup>1,2,3,4</sup>, Meng-Kuang Lee<sup>1,3</sup>, Chih-Tsung Liu<sup>\*5</sup>

<sup>1</sup>Division of Cardiology, Department of Internal Medicine, Kaohsiung Medical University Hospital, Kaohsiung Medical University, Kaohsiung, Taiwan

<sup>2</sup>Graduate Institute of Clinical Medicine, College of Medicine, Kaohsiung Medical University, Kaohsiung, Taiwan

<sup>3</sup>Department of Internal Medicine, Kaohsiung Municipal Hsiao-Kang Hospital, Kaohsiung Medical University, Kaohsiung, Taiwan

<sup>4</sup>Faculty of Medicine, College of Medicine, Kaohsiung Medical University, Kaohsiung, Taiwan

<sup>5</sup>Department of Internal Medicine, Tungs' Taichung MetroHarbor Hospital, Taichung, Taiwan

**Received:** December 11, 2017

**Accepted:** February 1, 2018

**Online Published:** March 5, 2018

**DOI:** 10.5430/crim.v5n1p43

**URL:** <https://doi.org/10.5430/crim.v5n1p43>

## ABSTRACT

Acute pulmonary embolism (PE) and ST-elevation myocardial infarction (STEMI) have different etiology; however, PE might be concomitant with STEMI in rarely seen patient cases. Here, we present a 62-year-old male with pancreatic cancer who had acute PE and STEMI.

**Key Words:** Pulmonary embolism, ST-elevation myocardial infarction, Acute coronary syndrome

## 1. INTRODUCTION

Acute pulmonary embolism (PE) and ST-elevation myocardial infarction (STEMI) are life-threatening diseases in patients with acute chest pain.<sup>[1,2]</sup> Although PE and STEMI have different pathophysiology, PE might be concomitant with STEMI in rarely seen patient cases.

## 2. CASE REPORT

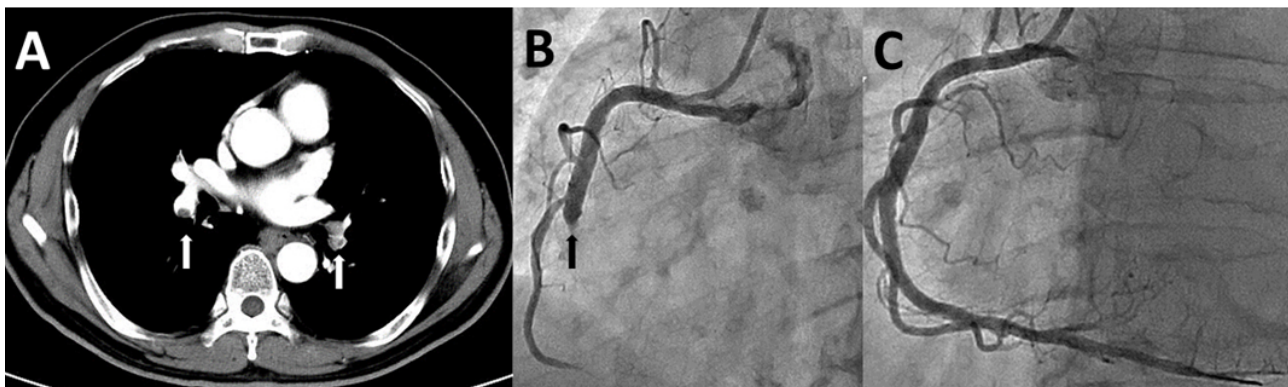
Here, we present a 62-year-old male with pancreatic cancer who had acute PE and STEMI. He did not have hypertension, hyperlipidemia, diabetes mellitus, and any cardiovascular diseases, and did not take regular medication before this acute episode. His family did not have premature cardiovascular diseases either. He had previously had

pancreatic cancer, but he had not received any chemotherapy, radiotherapy and surgical treatment before this acute episode. This time, he presented with shortness of breath and right lower-leg swelling for 2 days. Physical examination revealed heart rate 86/min, respiratory rate 18/min, blood pressure 120/80 mmHg, grade III/VI pansystolic murmur over left lower sternal border, and right lower-leg swelling. The laboratory tests were as follows: cardiac troponin I 0.01 µg/L (normal range < 0.04 µg/L), brain natriuretic peptide 20.8 ng/L (normal range < 100 ng/L), D-dimer 19.3 mg/L (normal range < 0.5 mg/L), creatinine 0.96 mg/dl (normal range 0.6 to 1.5 mg/L), protein C 87% (normal range 80% to 132%), protein S 109% (normal range 55% to 130%), anti-thrombin 100% (normal range 85% to 118%), collating factor

\*Correspondence: Chih-Tsung Liu; Email: [darrow940183@gmail.com](mailto:darrow940183@gmail.com); Address: No. 699, Sec. 8, Taiwan Blvd., Taichung City 435, Taiwan.

VIII 166% (normal range 60% to 150%), anti- $\beta$ 2 glycoprotein 0.9 U/ml (normal negative), homocysteine 11.4  $\mu$ mol/L (normal range 5.4 to 16.2  $\mu$ mol/L), and carcinoembryonic antigen 261.78 ng/ml (normal < 5.0 ng/ml). Initially, the 12 lead electrocardiogram showed sinus rhythm and no ischemic change. The chest computed tomography (CT) scan revealed acute pulmonary embolism involved bilateral pulmonary arteries (see Figure 1A white arrows). The echocardiography showed right ventricular dilation and mild tricuspid valve regurgitation. Due to hemodynamic stability, our patient received subcutaneous enoxaparin in combination with oral warfarin.<sup>[1]</sup> After treatment for 5 days, he had sudden onset of typical cardiac chest pain and cold sweating. The 12-lead electrocardiogram showed sinus rhythm and ST-segment elevation on lead II, III, aVF. The laboratory tests were as follows: creatinine kinase 52 IU/L (normal range 26 to 170 IU/L), creatinine kinase MB 1.8 ng/ml (normal range 0.4 to 6.3 ng/ml), cardiac troponin I 0.002  $\mu$ g/L (normal

range < 0.04  $\mu$ g/L), and prothrombin time 25.8 (normal range 8 to 12 second). The emergent coronary angiogram showed total occlusion of middle right coronary artery (see Figure 1B black arrow). We injected tirofiban through a right coronary guiding catheter and were quickly wired through to the target lesion. We also performed thrombus aspiration, which showed red thrombus. Finally, we successfully deployed a bare metal stent (see Figure 1C) and Thrombolysis In Myocardial Infarction flow was grade 3. The secondary echocardiography showed no obvious intra-cardiac shunting defect and no endocarditis. However, he refused to allow the transesophageal echocardiographic (TEE) examination to be performed. Five days later, he was discharged and received triple antithrombotic therapy including aspirin 100 mg per day, clopidogrel 75 mg per day, and warfarin 2.5 mg per day. His INR (international normalized ratio) level was maintained at 2.0 to 3.0 during follow-up.



**Figure 1.** A: Contrast-enhanced chest-computed tomography scan showed filling defects over bilateral pulmonary arteries. B: The coronary angiogram showed total occlusion of middle-right coronary artery initially. C: Restored full coronary flow after coronary intervention with stent implantation.

### 3. DISCUSSION

In the aspect of pathophysiology, acute PE is frequently accompanied with deep venous thrombosis and STEMI commonly caused from rupture of coronary plaques.<sup>[1,2]</sup> In a recent literature review, thromboembolic events are frequently seen in patients with malignancy and in the setting of anti-cancer therapies.<sup>[3,4]</sup> Patients with pancreatic cancer also have higher risk of venous thrombosis than do patients with other underlying gastro-intestinal malignancies in the United States and Korea.<sup>[5,6]</sup> On the other hand, the one-year prevalence of cancer was 5.2% in patients with unprovoked venous thrombosis within one year.<sup>[7]</sup> The possible pathophysiology of cancer-related thromboembolic events are multifactorial and include inflammation, pro-thrombotic properties, hypercoagulable status, and clinical comorbidity.<sup>[8]</sup> Characteristics of prothrombotic or hypercoagulable state in patients with

cancer are caused from imbalance between the coagulation and fibrinolytic systems.<sup>[9-11]</sup> Over-expression of tissue factor of coagulation pathway in cancer results in increase of vascular endothelial growth factor and decrease of the angiogenesis inhibitor thrombospondin.<sup>[11]</sup>

Although the incidence of patients with malignancy-diagnosed deep venous thrombosis or PE is about 20%,<sup>[12]</sup> patients presenting with cancer and acute myocardial infarction (AMI) are rare. Women and young men with venous thromboembolism have higher risk of arterial thrombotic disease than those without venous thromboembolism in Tromsø's study.<sup>[13]</sup> Some cases with gastro-intestinal, hematological, and germinal system malignancy have been reported as having AMI.<sup>[12]</sup> Dieckmann, et al. demonstrated that a majority patients diagnosed with testicular cancer and AMI did

not have traditional atherosclerotic risk factors and coronary plaque.<sup>[14]</sup> These cancer conditions with AMI were probably caused from acute thromboembolic events rather than from coronary atherosclerotic stenosis.<sup>[14]</sup>

Severe systemic arterial and venous thromboembolic events have also been reported in patients with pancreatic cancer.<sup>[15,16]</sup> However, few cases are concomitant with both conditions. The mechanism involving acute PE and AMI are not fully understood. The causes of venous and arterial thrombotic diseases underlie traditional atherosclerotic risk factors such as advanced aged, obesity, hypertension, dyslipidemia, and diabetes.<sup>[13]</sup> The possible mechanism of both venous and arterial embolism may result from direct cancer vascular invasion, mucin-mediated thrombosis, intra-cardiac or intra-vascular embolization, activation of coagulation cascade by tissue factor, thrombin, inflammatory cytokines, and

endothelial and platelet adhesion molecules.<sup>[12-14,17]</sup> Other non-traditional risk factors for venous and arterial thrombosis were increased level of homocysteine, coagulation factors VIII, IX, XI, and von Willebrand factor.<sup>[12-14]</sup>

Our presenting patient had high level of collating factor VIII but did not have an obvious intra-cardiac shunting from transthoracic echocardiography. Although our patient refused TEE examination, TEE was strongly recommended with acute PE and AMI for occult intra-cardiac embolism. Our patient concomitance with PE and STEMI might be related to hyper-coagulation status. Triple antithrombotic therapy was expected to have prominent efficacy for hyper-coagulability, but side effect of bleeding tendency should be considered.<sup>[2,12]</sup>

## CONFLICTS OF INTEREST DISCLOSURE

The authors declare no conflicts of interest.

## REFERENCES

- [1] Tapson VF. Acute pulmonary embolism. *N Engl J Med.* 2008; 358: 1037-52. PMID:18322285. <https://doi.org/10.1056/NEJMra072753>
- [2] Levine GN, Bates ER, Bittl JA, et al. 2016 ACC/AHA Guideline Focused Update on Duration of Dual Antiplatelet Therapy in Patients With Coronary Artery Disease: A Report of the American College of Cardiology/American Heart Association Task Force on Clinical Practice Guidelines: An Update of the 2011 ACCF/AHA/SCAI Guideline for Percutaneous Coronary Intervention, 2011 ACCF/AHA Guideline for Coronary Artery Bypass Graft Surgery, 2012 ACC/AHA/ACP/AATS/PCNA/SCAI/STS Guideline for the Diagnosis and Management of Patients With Stable Ischemic Heart Disease, 2013 ACCF/AHA Guideline for the Management of ST-Elevation Myocardial Infarction, 2014 AHA/ACC Guideline for the Management of Patients With Non-ST-Elevation Acute Coronary Syndromes, and 2014 ACC/AHA Guideline on Perioperative Cardiovascular Evaluation and Management of Patients Undergoing Non-cardiac Surgery. *Circulation.* 2016; 134: e123-55. PMID:27026020. <https://doi.org/10.1161/CIR.0000000000000404>
- [3] Khorana AA, Carrier M, Garcia DA, et al. Guidance for the prevention and treatment of cancer-associated venous thromboembolism. *J Thromb Thrombolysis.* 2016; 41: 81-91. PMID:26780740. <https://dx.doi.org/10.1007/s11239-015-1313-4>
- [4] Khorana AA, O'Connell C, Agnelli G, et al. Incidental venous thromboembolism in oncology patients. *J Thromb Haemost.* 2012; 10: 2602-4. PMID:23362525. <https://doi.org/10.1111/jth.12023>
- [5] Puligondla C, Kumar R, Parasa S. Venous and Arterial Thromboembolism Related Hospitalizations Among Patients with Gastrointestinal Malignancy in United States - Data from Nationwide Sample. *Blood.* 2016; 128: 4993. Available from: <http://www.bloodjournal.org/content/128/22/4993?ssoc-checked=true>
- [6] Kim KH, Yoon SY, Yoon J, et al. Venous Thromboembolism (VTE) In Patients With Pancreatic Cancer. *Blood.* 2013; 122: 4801. Available from: <http://www.bloodjournal.org/content/122/21/4801>
- [7] van Es N, Le Gal G, Otten HM, et al. Screening for Occult Cancer in Patients With Unprovoked Venous Thromboembolism: A Systematic Review and Meta-analysis of Individual Patient Data. *Ann Intern Med.* 2017; 167: 410-417. PMID:28828492. <https://doi.org/10.7326/M17-0868>
- [8] Falanga A, Russo L, Verzeroli C. Mechanisms of thrombosis in cancer. *Thromb Res.* 2013; 131 Suppl 1: S59-62. PMID:23452745. [https://doi.org/10.1016/S0049-3848\(13\)70024-0](https://doi.org/10.1016/S0049-3848(13)70024-0)
- [9] Blann AD, Dunmore S. Arterial and venous thrombosis in cancer patients. *Cardiol Res Pract.* 2011; 2011: 394740. PMID:21403876. <https://dx.doi.org/10.4061/2011/394740>
- [10] Connolly GC, Khorana AA. Emerging risk stratification approaches to cancer-associated thrombosis: Risk factors, biomarkers and a risk score. *Thromb Res.* 2010; 125 Suppl 2: S1-7. PMID:20433985. [https://doi.org/10.1016/S0049-3848\(10\)00227-6](https://doi.org/10.1016/S0049-3848(10)00227-6)
- [11] Khorana AA, Fine RL. Pancreatic cancer and thromboembolic disease. *Lancet Oncol.* 2004; 5: 655-63. PMID:15522652. [https://doi.org/10.1016/S1470-2045\(04\)01606-7](https://doi.org/10.1016/S1470-2045(04)01606-7)
- [12] Caine GJ, Stonelake PS, Lip GY, et al. The hypercoagulable state of malignancy: pathogenesis and current debate. *Neoplasia.* 2002; 4: 465-73. PMID:12407439. <https://doi.org/10.1038/sj.neo.7900263>
- [13] Lind C, Flinterman LE, Enga KF, et al. Impact of incident venous thromboembolism on risk of arterial thrombotic diseases. *Circulation.* 2014; 129: 855-63. PMID:24270266. <https://doi.org/10.1161/CIRCULATIONAHA.113.004168>
- [14] Dieckmann KP, Gerl A, Witt J, et al. Myocardial infarction and other major vascular events during chemotherapy for testicular cancer. *Ann Oncol.* 2010; 21: 1607-11. PMID:20067918. <https://doi.org/10.1093/annonc/mdp597>
- [15] Majumder S, Thom T, Dasanu CA. Catastrophic arteriovenous thromboembolism as initial manifestation of pancreatic cancer. *JOP.* 2012; 13: 231-4. PMID:22406609. Available from: <http://www.serena.unina.it/index.php/jop/article/view/672/855>

- [16] Elikowski W, Lazowski S, Malek M, et al. Uncommon presentation of venous thromboembolism and fatal systemic emboli in a patient with nonbacterial thrombotic endocarditis due to pancreatic cancer. *Kardiol Pol.* 2010; 68: 678-83. PMID:20806201. Available from: [http://www.kardiologiapolska.pl/en/darmowy\\_pdf.phtml?id=95&indeks\\_art=2466](http://www.kardiologiapolska.pl/en/darmowy_pdf.phtml?id=95&indeks_art=2466)
- [17] Wasek WC, Samul W, Ryczek R, et al. Unique case of ST-segment-elevation myocardial infarction related to paradoxical embolization and simultaneous pulmonary embolization: Clinical considerations on indications for patent foramen ovale closure in non-guidelines land. *Circulation.* 2015; 131: 1214-23. PMID:25825398. <https://doi.org/10.1161/CIRCULATIONAHA.114.009846>