

CASE REPORTS

Uncommon spreading of primary malignant paraganglioma in a patient with *SDHB* mutation

Ivana Jochmanová^{1,2}, Marek Felšöci¹, Ivica Drahovská³, Karel Pacak², Ivica Lazúrová*¹

¹1st Department of Internal Medicine Medical Faculty, P.J. Šafárik University, Košice, Slovakia

²Section on Medical Neuroendocrinology, Eunice Kennedy Shriver National Institute of Child Health and Human Development, National Institutes of Health, Bethesda, Maryland, USA

³1st Department of Radiodiagnosics and Imaging Methods, P.J. Šafárik University, Košice, Slovakia

Received: February 27, 2017

Accepted: April 27, 2017

Online Published: May 22, 2017

DOI: 10.5430/crim.v4n2p63

URL: <https://doi.org/10.5430/crim.v4n2p63>

ABSTRACT

Pheochromocytomas (PHEOs) or paragangliomas (PGLs) are rare neuroendocrine tumors arising from adrenal medulla or from chromaffin cells outside the adrenal gland including parasympathetic ganglia, respectively. Here we describe a case of a 56-year-old man evaluated for left hip pain. The anatomical and functional imaging showed a pelvic tumor spreading through the foramen obturatum to the proximal part of the left hip, histologically confirmed as PGL. On biochemical evaluation elevated plasma catecholamine and metanephrine levels were found. The diagnosis of metastatic PGL was done based on additional lesions found in bones, liver, and retroperitoneal lymphatic nodes. Treatment with systemic cyclophosphamide, vincristine, and dacarbazine (CVD) chemotherapy was initiated and with a substantial decrease in tumor burden. Spreading of PGL (PHEO) through the foramen obturatum infiltrating the left hip is very uncommon and has not been described previously.

Key Words: Paraganglioma, Pheochromocytoma, Foramen obturatum, Femur, *SDHB* mutation

1. INTRODUCTION

Pheochromocytomas (PHEOs) and paragangliomas (PGLs) are rare neuroendocrine tumors arising from adrenal medulla, or extra-adrenal sympathetic or parasympathetic paraganglia, respectively.^[1,2] Common sites of these tumors include mediastinum, retroperitoneum or head and neck region. Head and neck PGLs are usually non-functional but PHEOs and functional PGLs are catecholamine secreting tumors.^[2,3] Malignant PGLs or PHEOs usually metastasize to the bones, retroperitoneum or liver, rarely to other organs. Spreading of primary tumors can be seen to the retroperitoneal organs including pancreas and kidney and to the pelvic region. Although metastases to the hip were described in some cases,

spreading of primary tumor through the foramen obturatum has not been described in the previous literature.

In this report, we present the case of metastatic extra-adrenal PGL spreading through the foramen obturatum to the proximal left hip region.

2. CASE PRESENTATION

A fifty-six-year-old male with a 10-year history of arterial hypertension presented with the diagnosis of metastatic PGL. At the age of 53 he started to experience left hip pain and subsequently he was referred to the orthopedic department, where further imaging was performed. Ultrasound (US) and magnetic resonance imaging (MRI) showed a large pelvic

*Correspondence: Ivica Lazúrová; Email: ivica.lazurova@upjs.sk; Address: Department of Internal Medicine Medical Faculty, P.J.Šafárik University Košice, Trieda SNP 1, 04011 Košice, Slovak Republic.

tumor spreading through the foramen obturatum to the proximal part of the left hip. The patient underwent tumor biopsy and histological finding of the lesion was interpreted as PGL.

Other symptoms, in addition to constant left hip pain, included severe persistent hypertension (for the last 8–10 years), slight exercise intolerance and frequent night sweats, for the past three years. His blood pressure (BP) ranged from 117/75 mmHg to 220/125 mmHg in the last two years prior to the PGL diagnosis. Antihypertensive medication before diagnosis included calcium channel blockers, ACE inhibitors, and beta blockers. The family history was negative for the presence of severe hypertension or oncological diseases; however, patient's mother suddenly died of an unknown cause when he was six years old.

At hospital admission, the patient was conscious, hydrated, and without dyspnea. Lung auscultation findings were normal. Heart auscultation revealed tachycardia with a heart rate of 100/min and a BP of 140/100 mmHg. Abdominal palpation was normal, without palpable lesion, lower extremities

were without pathological findings.

On evaluation, biochemistry showed an elevation of plasma norepinephrine to 3,984 pg/ml (80–498 pg/ml), plasma dopamine to 3,363 pg/ml (3–46 pg/ml), plasma fractionated normetanephrine to 3,138 pg/ml (18–112 pg/ml), chromogranin A to 5,200 ng/ml (≤ 225 ng/ml), urinary norepinephrine to 1,805 $\mu\text{g}/24$ h (15–80 $\mu\text{g}/24$ h), and urinary dopamine to 3,475 $\mu\text{g}/24$ h (65–400 $\mu\text{g}/24$ h).

On anatomical imaging (computed tomography, CT, and magnetic resonance imaging, MRI) metastatic PGL was found (see Figures 1 and 2). After anatomical imaging, several functional imaging examinations were performed which confirmed the diagnosis of metastatic PGL into liver, retroperitoneal lymphatic nodes, and bones. Localization and size of tumors before treatment was shown on ^{123}I -metaiodobenzylguanidine (^{123}I -MIBG) scan. ^{18}F -fluorodeoxyglucose positron emission tomography (FDG-PET) confirmed the lesions found on the ^{123}I -MIBG scan.

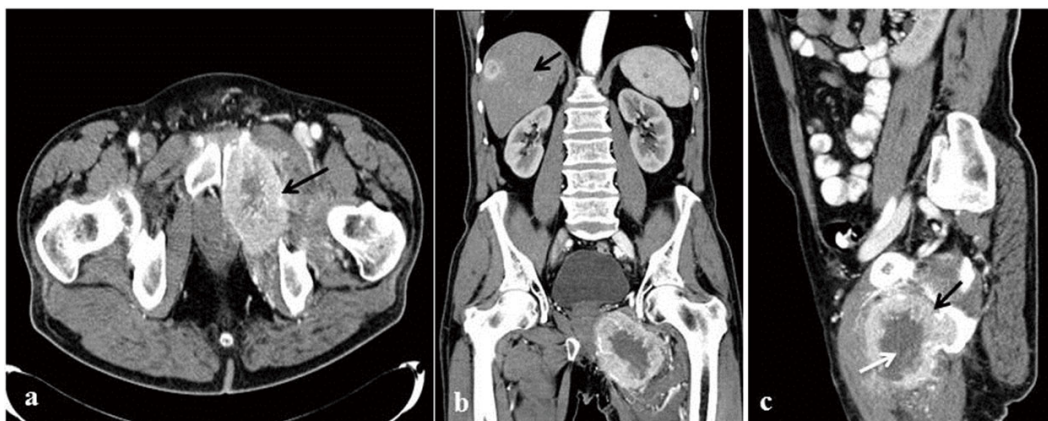


Figure 1. CT imaging. a) axial, c) sagittal, postcontrast image shows PGL metastatic to the os pubis l. sin. (arrow) before treatment with a large osteolytic lesion in the ramus inferior and in the ventral part of the ramus superior of the os pubis l. sin. Tumor infiltrate transverse dimensions are 7.9 cm \times 19.8 cm, vertical dimension is 10.3 cm. Inner part of neoplasm is necrotic (white arrow), peripheral part is highly vascularised with lamellar calcifications on the surface (black arrow). Tumor has spread through foramen obturatum and infiltrates surrounding muscular structures. b) Coronal CT image confirmed presence of metastatic lesions in the right lobe of liver (arrow). On the other images metastases to retroperitoneum and skeleton were found, as follows: 6 cm \times 5 cm lobulated and/or conglomerate mass in or near the pancreas head with possible minimal associated periaortic and/or peripancreatic adenopathy compatible with neoplasm, approximate 8 cm \times 7 cm left ischium lytic lesion with extension into soft tissues compatible with metastasis, and spine and vascular calcification upper thoracic spine foci of uncertain significance.

Genetic testing was also performed and the mutation in the succinate dehydrogenase B (*SDHB*) gene was found in this patient.

Surgical treatment was not recommended because of high risk and impossibility of removing the primary tumor from the bone. After reviewing the patient's scans and pathology

report, systemic chemotherapy using cyclophosphamide, vincristine, and dacarbazine (CVD) was started. This treatment led to a marked improvement in the clinical, laboratory as well as local findings which were confirmed by repeated CT and ^{123}I -MIBG scans. Two years after CVD treatment patient is doing well and blood pressure and heart rate are stable on alpha- and beta-blockers.

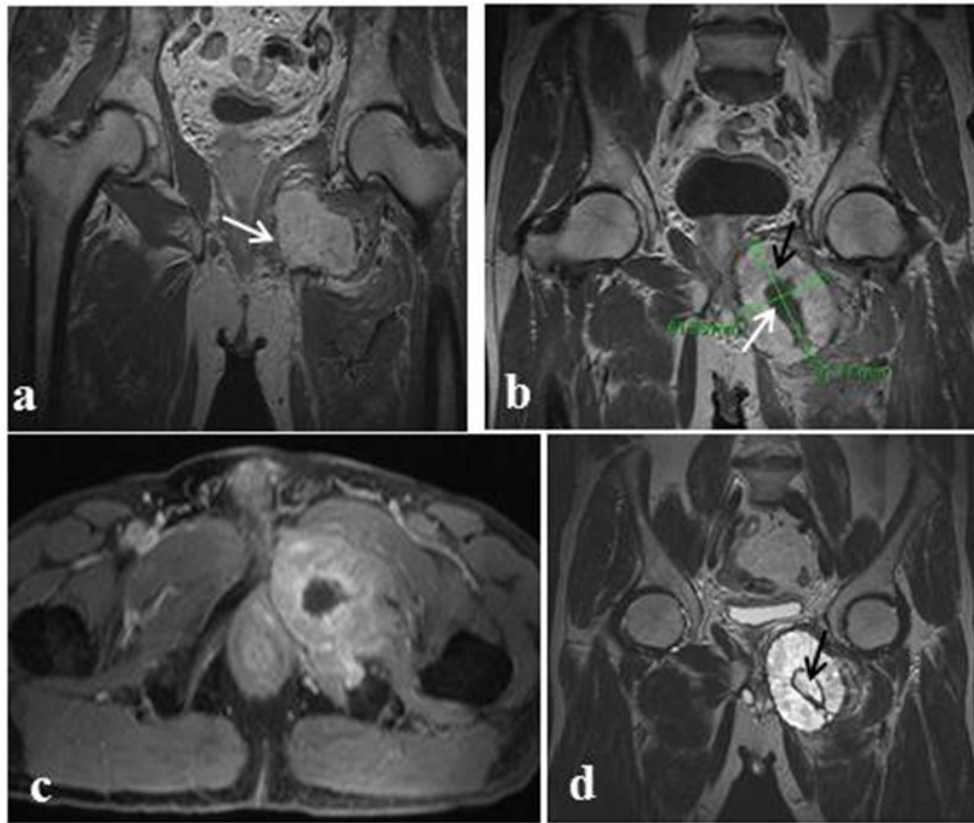


Figure 2. MRI scan. a), b) Gadolinium-enhanced coronar T1-weighted image of ovoid lobulated metastatic PGL lesion (arrow) with typical multiple serpentinosis areas and so-called flow voids – the high vascularization inside the tumor. b) Postcontrast high vascularization in the periphery (black arrow) with higher signal and with central avascular necrosis (white arrow) of the tumor. c) Poscontrast axial T1-weighted image of metastatic lesion in the ramus inferior of os pubis I. sin. Spread of the tumor through foramen obturatum and infiltration of muscular structures of the proximal part of the left hip is seen. d) Coronar T2-weighted image showing a hyperintensive signal with central necrosis and a hemosiderin margin inside the lesion (arrow).

3. DISCUSSION

Extra-adrenal PGLs are rare neuroendocrine tumors and their typical locations are sympathetic tissues including the organ of Zuckerkandl, the sympathetic plexus of the urinary bladder, the kidneys and the heart, and the sympathetic ganglia of the mediastinum.^[4] The other common location is the parasympathetic tissue of the head and neck.^[1] PGL diagnosis is based on the clinical presentation, biochemical evaluation (elevation of urinary/plasma catecholamines and their O-methylated metabolites), localization of the tumor by a combination of anatomical and functional imaging, and, if possible, tumor histology.^[5]

Spreading of pelvic PGL in the hip region is an extremely rare entity and was documented only by some authors. Glassman et al.^[6] described a case of pathological fractures of both hips due to metastases of malignant PHEO. Similarly, Ubayama et al.^[7] reported patient with a pathological fracture of the right femur in a patient subsequently diagnosed

with malignant PGL. Some others later reported cases of patients with PHEOs or PGLs with lytic lesions to the femur in a majority of cases on the left side. In the report of Young et al.^[8] the lesion was treated with local external radio-therapy. In the older report of McCarthy et al.^[9] solitary metastasis to the left femur was resolved by hip disarticulation after removal of the primary tumor. Our case report differs from the previous because the femoral lesion in our patient seemed to be a primary lesion spreading through the foramen obturatum to the left femur and infiltrating it. It is not clear if the primary lesion originated from the left adrenal gland (PHEO) or from paraaortic ganglia (PGL) because surgical treatment has not been done and anatomical imaging studies were not able to detect the left adrenal gland. Nevertheless according to our best knowledge this is the first case of unusual spreading of a primary tumor through the foramen obturatum to the hip.

The patient described in our case has a *SDHB* mutation which

represents a 34% – 70% risk of malignancy.^[10,11] The overall 5-year survival of such patients ranges from 40% to 72%.^[12] Metastases in our patient were detected in the liver, retroperitoneum, and skeleton.

In this report we describe a very rare case of aggressively growing PGL with spreading of the primary tumor through the foramen obturatum to the left hip. Such spreading has not yet been described in the previous literature and it may be the result of long-term unrecognized disease. This could

be a very good example indicating that early recognition of PGL is very important to avoid its massive enlargement and uncommon spreading making surgical treatment impossible.

ACKNOWLEDGEMENTS

This work was supported, in part, by the Intramural Research Program of the NIH, NICHD.

CONFLICTS OF INTEREST DISCLOSURE

The authors have declared no conflicts of interest.

REFERENCES

- [1] DeLellis RA, Lloyd RV, Heitz PU, et al. Pathology and genetics of tumours of endocrine organs. Lyon: IARC Press; 2004. 320 p.
- [2] Martucci VL, Pacak K. Pheochromocytoma and paraganglioma: diagnosis, genetics, management, and treatment. *Curr Probl Cancer*. 2014 Jan-Feb; 38(1): 7-41. PMID:24636754 <https://doi.org/10.1016/j.crrproblcancer.2014.01.001>
- [3] Kantorovich V, King KS, Pacak K. SDH-related pheochromocytoma and paraganglioma. *Best Pract Res Clin Endocrinol Metab*. 2010 Jun; 24(3): 415-24. PMID:20833333 <http://dx.doi.org/10.1016/j.beem.2010.04.001>
- [4] Timmers HJ, Gimenez-Roqueplo AP, Mannelli M, et al. Clinical aspects of SDHx-related pheochromocytoma and paraganglioma. *Endocr Relat Cancer*. 2009 Jun; 16(9): 391-400. PMID:19190077 <http://dx.doi.org/10.1677/ERC-08-0284>
- [5] Lenders JW, Duh QY, Eisenhofer G, et al. Pheochromocytoma and paraganglioma: an endocrine society clinical practice guideline. *J Clin Endocrinol Metab*. 2017 Jun; 99(6): 1915-42. <http://dx.doi.org/10.1210/jc.2014-1498>
- [6] Glassman AH, Kean JR, Martino JD, et al. Subtrochanteric pathological fracture of both femora secondary to malignant pheochromocytoma. A case report. *J Bone Joint Surg Am*. 1990 Dec; 72(10): 1554-8. PMID:2254367 <https://doi.org/10.2106/00004623-199072100-00021>
- [7] Ubayama Y, Gotoh M, Yamawaki S, et al. A case of malignant paraganglioma arising from the retroperitoneum. *Gan No Rinsho*. 1987 Apr; 33(4): 442-8. PMID:3033348
- [8] Young AL, Baysal BE, Deb A, et al. Familial malignant catecholamine-secreting paraganglioma with prolonged survival associated with mutation in the succinate dehydrogenase B gene. *J Clin Endocrinol Metab*. 2002 Sep; 87(9): 4101-5. PMID:12213855. <https://doi.org/10.1210/jc.2002-020312>
- [9] McCarthy EF, Bonfiglio M, Lawton W. A solitary functioning osseous metastasis from a malignant pheochromocytoma of the organ of Zuckerkandl. *Cancer*. 1977 Dec; 40(6): 3092-6. [https://doi.org/10.1002/1097-0142\(197712\)40:6<3092::AID-CNCR2820400650>3.0.CO;2-N](https://doi.org/10.1002/1097-0142(197712)40:6<3092::AID-CNCR2820400650>3.0.CO;2-N)
- [10] Timmers HJ, Kozupa A, Eisenhofer G, et al. Clinical presentations, biochemical phenotypes, and genotype-phenotype correlations in patients with succinate dehydrogenase subunit B-associated pheochromocytomas and paragangliomas. *J Clin Endocrinol Metab*. 2007 Mar; 92(3): 779-86. PMID:17200167. <https://doi.org/10.1210/jc.2006-2315>
- [11] Fishbein L. Pheochromocytoma and Paraganglioma: Genetics, Diagnosis, and Treatment. *Hematol Oncol Clin North Am*. 2016 Feb; 30(1): 135-50. PMID:26614373 <http://dx.doi.org/10.1016/j.hoc.2015.09.006>
- [12] Ayala-Ramirez M, Feng L, Johnson MM, et al. Clinical risk factors for malignancy and overall survival in patients with pheochromocytomas and sympathetic paragangliomas: Primary tumor size and primary tumor location as prognostic indicators. *J Clin Endocrinol Metab*. 2011 Mar; 96(3): 717-25. <http://dx.doi.org/10.1210/jc.2010-1946>