

CASE REPORTS

Complete heart block in pregnancy

Wesley Fiser^{*1}, Kevin Hayes², Hakan Paydak¹

¹University of Arkansas for Medical Sciences, Arkansas, USA

²Texarkana Cardiology Associates, Texarkana, TX, USA

Received: December 11, 2016

Accepted: February 16, 2017

Online Published: February 27, 2017

DOI: 10.5430/crim.v4n2p22

URL: <https://doi.org/10.5430/crim.v4n2p22>

ABSTRACT

A pregnant woman presented with increasing exertional dyspnea and was found to have complete heart block with a junctional escape rhythm. The complete heart block did not resolve with exercise testing, suggesting infranodal disease. A presumptive diagnosis of mild viral myocarditis was made, having been exposed to her toddler with a viral exanthem days before. After giving steroids to preemptively accelerate fetal lung maturity and several days of close observation, the AV block resolved. She was discharged in stable condition without need for temporary or permanent pacing and later delivered a healthy infant.

Key Words: Pregnancy, 3rd degree AV block, Junctional escape rhythm

1. INTRODUCTION

Maternal complete heart block in pregnancy is a rare entity. If a reversible cause of complete heart block is not found, then permanent pacemaker or use of transvenous pacing during labor may be indicated if the patient is symptomatic.

2. CASE

A 32-year-old woman with no past medical history presented in the 26th week of pregnancy with increasing exertional dyspnea and lightheadedness without syncope. She reported having a rash on her palms and soles about ten days prior to onset of the above symptoms, following a diagnosis of hand, foot, and mouth disease in her toddler, who had a similar viral exanthem including oral ulcerations. Upon evaluation the patient appeared comfortable and in no distress; vital signs showed bradycardia in the 40s with normal blood pressure. Physical exam was remarkable for bradycardia with otherwise regular heart tones, no murmurs, normal jugular venous pressure, and a gravid uterus. An electrocardiogram (ECG) demonstrated sinus with third degree AV block and junctional escape rhythm (see Figure 1); she had no prior

ECG for baseline comparison. The patient was admitted for close observation but did not immediately require temporary pacing measures because of stable blood pressure.

Laboratory data showed mild leukocytosis (12k, 71% PMN, 21% lymph), troponin I 0.24 ng/ml (reference normal < 0.04), CRP 6.2 mg/L, ESR 19 mm/hr, TSH 2.36, ANA < 1:80, and negative Lyme serology. Fetal heart tones were reassuring without fetal bradycardia. She received two doses of empiric betamethasone for fetal lung maturity, in case premature delivery occurred with use of atropine. Transthoracic echocardiogram showed no evidence of structural heart disease. On hospital day #2, the third degree AV block persisted, and assessment of both chronotropic competence and the level of AV block were made by exercise treadmill testing (per modified Bruce protocol) in order to determine whether back up pacing might be required. During exercise she maintained normal blood pressure, but the rhythm remained in complete heart block while the junctional rhythm accelerated to 109 bpm (see Figure 2). She did not experience symptoms during exercise; the test was terminated once chronotropic competence was demonstrated.

* **Correspondence:** Wesley Fiser; Email: wmfiser@uams.edu; Address: 4301 W Markham Street, Slot 532, Little Rock, Arkansas 72205-7199, USA.

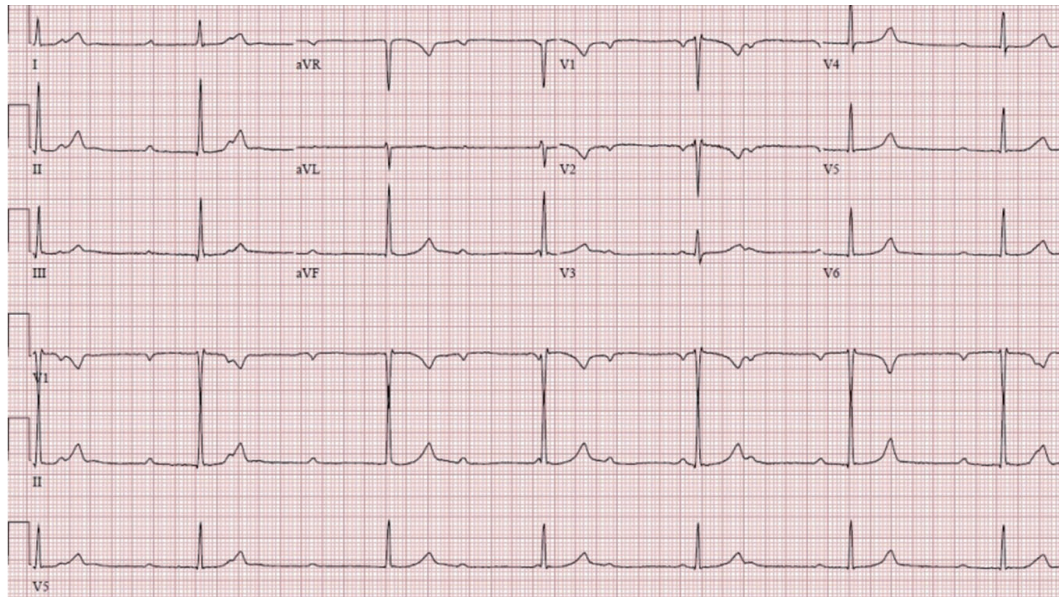


Figure 1. ECG at presentation: 3rd degree AV block and AV dissociation with junctional escape rhythm

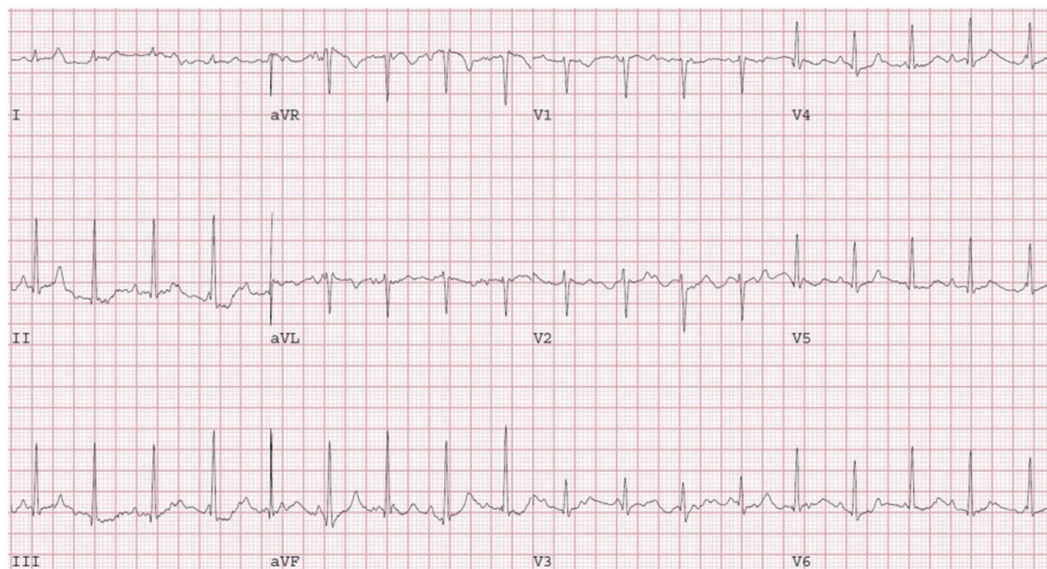


Figure 2. ECG during peak exercise: persistent 3rd degree AV block and AV dissociation with accelerated junctional rhythm of 109 bpm

After seven days of telemetry observation, she began to show improved AV nodal 1:1 conduction with only episodic AV dissociation without symptoms. Daily fetal monitoring remained reassuring, and she was discharged home in good condition. At time of two-week follow up, electrocardiogram showed normal sinus rhythm with 1:1 AV conduction, and the patient was completely symptom-free. Holter ECG at one month follow up showed normal sinus rhythm with normal heart rate variability (average 69 bpm) and no AV block. The remainder of her pregnancy progressed without

complication, and she underwent schedule induction at 38 weeks and 6 days, delivering a healthy infant by spontaneous vaginal delivery. There were no episodes of maternal heart block during labor or the peripartum period.

3. DISCUSSION

Complete heart block in pregnancy is rare, and reversible causes must be readily identified. The narrow differential diagnosis includes: initial presentation of maternal congenital complete heart block, associated with maternal connective tis-

sue disorders; hypothyroidism; and myocarditis. If the ECG shows narrow ventricular escape complexes (junctional) and the atrioventricular (AV) conduction improves with atropine or exercise, then the block is most likely within the AV node. These features are often indicative of a temporary and reversible AV block, and pacing may not be indicated. On the contrary, if the AV conduction worsens with atropine or exercise, the level of block is more likely to be at the level of the His bundle, and pacing methods may be required.

In our patient, AV conduction did not improve with exercise, rather the junctional escape rhythm became faster. An identifiable cause of heart block was not found. Her recent viral exanthem following exposure to her toddler, which preceded the onset of symptoms, could have caused a mild viral myocarditis from an adenovirus or enterovirus (not tested). The clinical history suggested that this woman developed mild viral myocarditis, leading to peri-AV nodal edema and transient complete heart block. The use of steroids for accelerated fetal lung maturity and time led to restoration of normal sinus rhythm with 1:1 conduction.

Temporary or permanent pacing may be indicated in the setting of symptomatic complete heart block with associated syncope, which our patient did not experience. The most comprehensive review of pacing strategies in complete heart block during pregnancy by Hidaka et al. suggests that most cases of asymptomatic complete AV block can be safely

managed during labor without temporary pacing.^[1] However, the symptomatic patient near term may require insertion of a temporary pacemaker as well as epidural anesthesia and assisted delivery to minimize cardiac demand during labor. Permanent pacing is reserved for women who remain in symptomatic complete AV block in the post-partum period or who develop bradycardia-related symptoms (syncope) during early pregnancy. Pacing is not necessarily indicated when no symptoms are present.^[2] Evaluation of chronotropic competence can also be achieved with atropine and is a key step to determine whether a pacemaker will be necessary.^[3] Atropine was avoided in this patient due to uncertainty of its effect upon the fetus, and a similar evaluation of chronotropic competency was established with moderate exercise.

4. CONCLUSION

Complete heart block in pregnancy is a rare entity that is often due to a reversible underlying condition, which should be readily identified. Response to atropine and exercise help to delineate the locus of conduction block. Our patient was thought to have mild viral myocarditis leading to peri-AV nodal edema and complete heart block that did not improve with exercise. Her symptoms fully resolved within days of presentation.

CONFLICTS OF INTEREST DISCLOSURE

The authors have no competing interests to declare.

REFERENCES

- [1] Hidaka N, Chiba Y, Fukushima K, et al. Pregnant Women with Complete Atrioventricular Block: Perinatal Risks and Review of Management. *Pacing and Clinical Electrophysiology*. 2011; 34(9): 1161-1176. PMID:21797903 <https://doi.org/10.1111/j.1540-8159.2011.03177.x>
- [2] Sundararaman L, Cohen JH, Ranasinghe JS. Complete Heart Block in Pregnancy: case report, analysis, and review of anesthetic management. *Journal of Clinical Anesthesia*. 2016; 33: 58-61. PMID:27555134 <https://doi.org/10.1016/j.jclinane.2016.01.021>
- [3] Mohapatra V, Panda A, Behera S, et al. Complete Heart Block in Pregnancy: a report of emergency cesarean section in a parturient without pacemaker. *Journal of Clinical and Diagnostic Research*. 2016; 10(10). <https://doi.org/10.7860/jcdr/2016/20173.8606>