

## CASE REPORT

# Postoperative *Clostridium tertium* septicemia in a non-neutropenic pediatric patient

Toshihiro Yasui \*<sup>1</sup>, Mitsutaka Wakuda<sup>2</sup>, Junichi Ishii<sup>2</sup>, Tatsuya Suzuki<sup>1</sup>, Fujio Hara<sup>1</sup>, Shunsuke Watanabe<sup>1</sup>, Naoko Uga<sup>1</sup>, Atsuki Naoe<sup>1</sup>

<sup>1</sup>Department of Pediatric Surgery, Fujita Health University, Toyoake, Japan

<sup>2</sup>Department of Joint Research Laboratory of Clinical Medicine, Fujita Health University, Toyoake, Japan

**Received:** December 27, 2015

**Accepted:** February 15, 2016

**Online Published:** February 29, 2016

**DOI:** 10.5430/crcp.v3n2p22

**URL:** <http://dx.doi.org/10.5430/crcp.v3n2p22>

## ABSTRACT

*Clostridium tertium* (*C. tertium*) septicemia is rare, and most cases are observed in neutropenic patients. Our case was a non-neutropenic 7-month-old male who underwent anorectal surgery. On postoperative day 2, his body temperature increased to 40.0°C and gram-positive bacilli were isolated from the aerobic blood culture. We started empiric antibiotic therapy with meropenem. Because the strain was initially identified as *Listeria grayi*, we switched to ampicillin following susceptibility testing. However, the sequence analysis of the 16S-rRNA gene showed 99% similarity to *C. tertium*. Here we review the characteristics and management of *C. tertium* septicemia in non-neutropenic patients.

**Key Words:** *Clostridium tertium*, Bacteremia, Septicemia, Non-neutropenic patients, Pediatric patients

## 1. INTRODUCTION

*Clostridium* species are gram-positive, spore-forming anaerobic bacilli found in soil and the gut of humans and various animals.<sup>[1]</sup> Bacteremia caused by this organism is rare and occurs following intra-abdominal sepsis associated with trauma or surgery; however, the bacteremia may also occur in case of gastrointestinal disorders, pregnancy, and malignancies.<sup>[2]</sup>

*Clostridium tertium* (*C. tertium*) has been identified to comprise the normal flora of the lower intestine and was first described in 1917 by Henry who isolated it from war wounds.<sup>[3]</sup> However, the pathogenicity of this organism was unrecognized until the first report of *C. tertium* bacteremia in 1963.<sup>[4]</sup> Although *C. tertium* has been isolated from blood in most reported cases of *C. tertium* infection, it has also been im-

plicated in spontaneous bacterial peritonitis, brain abscesses, nasopharyngeal carcinoma, and pneumonia.<sup>[2,4-10]</sup> However, the pathogenicity of this organism remains unclear.<sup>[10]</sup> *C. tertium* can easily be misidentified because of its non-toxin-producing, aerotolerant, and gram-variable properties, which are different to those of other clostridia. Almost all the reported cases of *C. tertium* bacteremia have occurred in neutropenic patients without any obvious source of infection.<sup>[2,5-7,9,10]</sup> In contrast, bacteremia in non-neutropenic patients is rare,<sup>[2,4,7,8]</sup> and Table 1 summarizes all the known cases. A fatal case involving a non-neutropenic patient has been documented;<sup>[8]</sup> hence, a rapid diagnosis is desirable.

To the best of our knowledge, we report the first case of postoperative *C. tertium* septicemia in a non-neutropenic pediatric patient with anorectal anomaly.

\*Correspondence: Toshihiro Yasui; Email: t-yasui@fujita-hu.ac.jp; Address: Department of Pediatric Surgery, Fujita Health University School of Medicine, 1-98 Dengakugakubo, Kutsukake-cho, Toyoake, Aichi 4701192, Japan.

**Table 1.** Characteristics of non-neutropenic patients who were infected with *Clostridium tertium*

Year	Patients (n)	Age (years)	Primary Disease	Antimicrobial Therapy	Duration of Therapy	Outcome
1963	2	7	Pneumonia	Penicillin	10 days	Alive
		7	Pneumonia	Penicillin tetracycline	3 days	Alive
1987	1	N.D.	Abdominal surgery	Penicillin	N.D.	Alive
1993	1	57	Ulcerative colitis	Ticarcillin/Clavulanic acid Gentamicin	4 days	Alive
2001	3	43	End-stage liver disease	N.D.	N.D.	Died
		24	Systemic lupus erythematosus	N.D.	N.D.	Died
		28	Crohn's disease	Ciprofloxacin Clindamycin	N.D.	Alive
2005	1	51	Mechanical ileus	Mezlocillin Metronidazole	1 day	Died
2015	1	0	Anorectal agenesis without fistulas	Meropenem Ampicillin	14 days	Alive

Note. N.D. = no details

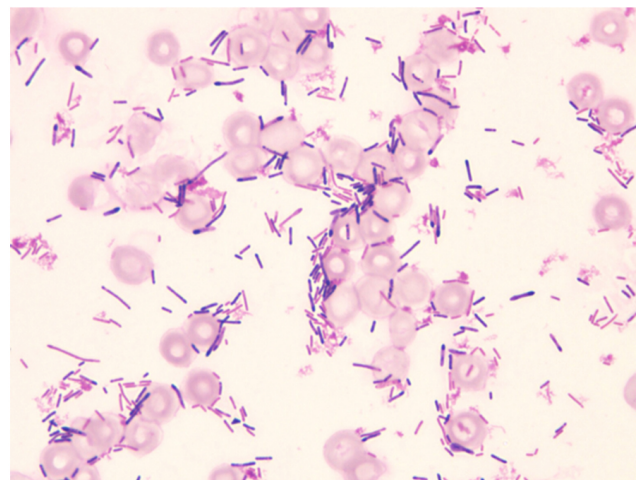
## 2. CASE PRESENTATION

This case describes a 7-month-old male who was born at 40 3/7 weeks of gestation by cesarean section because of delivery complications. The patient's birth weight was 2,968 g, and he was immediately diagnosed with rectum atresia and transferred to our hospital. Because of the presence of a high rectum, an emergency colostomy of the transverse colon was performed. Two weeks following the colostomy, a distal colostogram revealed anorectal agenesis without any fistulas.

When the patient turned 7-month old, he was subjected to radical surgery comprising laparoscopy-assisted anorectoplasty of the transverse colon as well as ileostomy because the distal colon was very short and it was difficult to pull it down to the anus. The operative time was 15 h and 25 min, and the blood loss was 68 g. We administered cefmetazole (during the operation, 25 mg/kg every 4 h; following the operation, 25 mg/kg every 8 h) from the beginning of the operation to the postoperative day 1 to prevent surgical-site infection.

On postoperative day 2, his body temperature increased to 40.0°C and his heart rate rose to > 170 beats/min. His extremities were cold and required fluid resuscitation. The white blood cell count was 9,700 cells/ $\mu$ l, platelet count was  $24.7 \times 10^4/\mu$ l, C-reactive protein level was 38.5 mg/dl, and procalcitonin level was 4.74 ng/ml. We suspected septicemia and obtained blood and anal wound cultures. We started empiric antibiotic therapy with meropenem (40 mg/kg/day $\times$ 3). On the following day, gram-positive bacilli were isolated from the aerobic blood culture (see Figure 1). On postoperative day 5, his vital condition was stable and his body temperature became normal by postoperative day 8. On postoperative day 7, the strain was initially identified as *Listeria grayi*; thus, we switched from meropenem to ampicillin (65 mg/kg/day $\times$ 3) following susceptibility testing. The total

antibiotic therapy duration was 14 days. The anal wound culture produced *Escherichia coli*, *Enterococcus faecalis*, and *Klebsiella pneumoniae*, all of which had no tolerance. The patient was dismissed from our hospital 30 days following the operation.



**Figure 1.** Pediatric case of *C. tertium* septicemia. Gram-positive and -negative rods were cultured from the blood. Although various types were observed, a single colony was cultured on aerobic agar. *C. tertium* is difficult to diagnose based on only Gram staining because of the various observed types.

The blood culture system used was VersaTREK<sup>TM</sup> REDOX<sup>TM</sup> (Thermo Scientific, Yokohama, Japan). The culture was reported as positive within 24 h, and the organism was identified as an aerobic gram-positive bacillus, presumably a *Corynebacterium* or *Bacillus* species. The organism was cultured on aerobic agar, Try/Soy Blood Agar (Sheep) No. 2 (Kyokuto Pharmaceutical Industrial Co., Ltd., Tokyo, Japan), and API<sup>®</sup> Coryne (Sysmex BioMerieux Co., Ltd., Tokyo, Japan) identified the organism as *L. grayi*. However,

sequence analysis of the 16S-rRNA gene revealed only 87% similarity to *L. grayi*, whereas the sequence had 99% similarity to *C. tertium* (AB618789)(see Figure 2). *C. tertium* was observed to grow well on the anaerobic Brucella HK Agar (Rabbit) (Kyokuto Pharmaceutical Industrial Co., Ltd., Tokyo, Japan), and could be identified using Rap ID ANA II (AMCO Inc., Tokyo, Japan). Susceptibility tests are shown in Table 2.

**Table 2.** Susceptibility tests using Dry Plate "EIKEN" (Eiken Chemical Co., Ltd., Tokyo, Japan)

**a.** MICs under aerobic conditions. Most of the antibiotics were sensitive to *C. tertium*

Antibiotics	µg/ml	Sensitive (S) Resistant (R)
PCG	0.5	S
ABPC	2	S
CEZ	4	S
CTM	> 16	R
CTX	> 16	R
CPR	> 16	R
FMOX	< 0.25	S
CCL	> 16	R
CFTM	> 16	R
IPM	0.25	S
MINO	< 0.5	S
EM	1	S
CLDM	4	S
LVFX	< 0.5	S
CAM	0.5	S
ST	10	S

**b.** MICs under anaerobic conditions. Most of the antibiotics were sensitive to *C.tertium*.

Antibiotics	µg/ml	Sensitive (S) Resistant (R)
PIPC	16	S
CZOP	> 32	R
CMZ	0.5	S
FMOX	< 0.25	S
SBT/CPZ	8	S
IPM	2	S
MINO	< 0.13	S
CLDM	8	S
TFLX	< 0.25	S
LMOX	8	S

Note. PCG: Penicillin G, ABPC: ampicillin, CEZ: cefazolin, CTM: cefotiam, CTX: cefotaxime, CPR: ceftiofur, FMOX: flomoxef, CCL: cefaclor, CFTM: cefteteram, IPM: imipenem, MINO: minocycline, EM: erythromycin, CLDM: clindamycin, LVFX: levofloxacin, CAM: clarithromycin, ST: sulfamethoxazole-timethoprim, PIPC: piperacillin, CZOP: cefozopran, CMZ: cefmetazole, SBT/CPZ: sulbactam/cefoperazone, TFLX: tosufloxacin, LMOX: latamoxef

### 3. DISCUSSION

*C. tertium* is different from other *Clostridium* species because it can be cultured under aerobic conditions.<sup>[4]</sup> Because of

the fact that *C. tertium* is observed as both gram-positive and -negative bacilli, it can be misidentified as *Corynebacterium* or *Bacillus* species; thus, it usually takes considerable time to identify the species using classical bacteriological techniques.<sup>[2-10]</sup> Hence, in our case, we initially misidentified *C. tertium* as *L. grayi*.

Because *C. tertium* bacteremia is rare and the organism does not produce toxins, thereby having an unclear pathogenicity, some clinicians disregard the significance of isolating it from blood cultures.<sup>[6,10]</sup> However, fatal cases of *C. tertium* bacteremia have been reported<sup>[2,5,8]</sup> and we believe that treatment must be initiated upon the identification of the bacterium in blood cultures. To date, although most documented cases have involved neutropenic patients,<sup>[2,5-7,9-11]</sup> cases involving non-neutropenic patients have also been described.<sup>[2,4,7,8]</sup> Salvador *et al.*<sup>[11]</sup> reported that *C. tertium* could be rapidly identified using a novel mass spectrometry technology (matrix assisted laser desorption ionization time-of-flight). In this case, we believe that *C. tertium* was the cause of septicemia because the organism was independently cultured and that the bacterium identified in the anal wound cultures was different. Bacterial translocation was likely the port of entry, caused by immunodeficiency following the long duration of the operation and fasting from the day before the operation. To the best of our knowledge, the patient described in this case is the youngest patient with *C. tertium* septicemia among both neutropenic and non-neutropenic patients. Only 10 cases involving non-neutropenic patients have been documented, all of which were related to chronic inflammatory bowel diseases such as ulcerative colitis, liver cirrhosis, and immunosuppression, including systemic lupus erythematosus, surgery, and trauma.<sup>[2,4,7,8]</sup> Therefore, in this case, abdominal surgery was considered as a risk factor.

If non-neutropenic patients are infected by *C. tertium*, rapid intervention is critical to avoid fatalities.<sup>[2,8]</sup> Because of its antibiotic resistance profile being different from that of other *Clostridium* species, a standard *C. tertium* infection treatment remains to be established.<sup>[8-10]</sup> Although most cases with febrile neutropenia have been treated using third-generation cepheims, these agents have almost no effect on *C. tertium*, which is also non-susceptible to beta-lactams.<sup>[5,7,8]</sup> Leegaard *et al.*<sup>[9]</sup> reported that *C. tertium* is sensitive to PCG, although susceptibility patterns may differ depending on geography. In our case, we successfully treated the patient with ampicillin. Susceptibility testing revealed that PCG, CEZ, FMOX, and IPM were effective. Although the duration of antibiotic therapy typically ranges from 15 to 27 days,<sup>[10]</sup> we treated the patient over a period of just 14 days. Hence, it may be possible to shorten the treatment period.

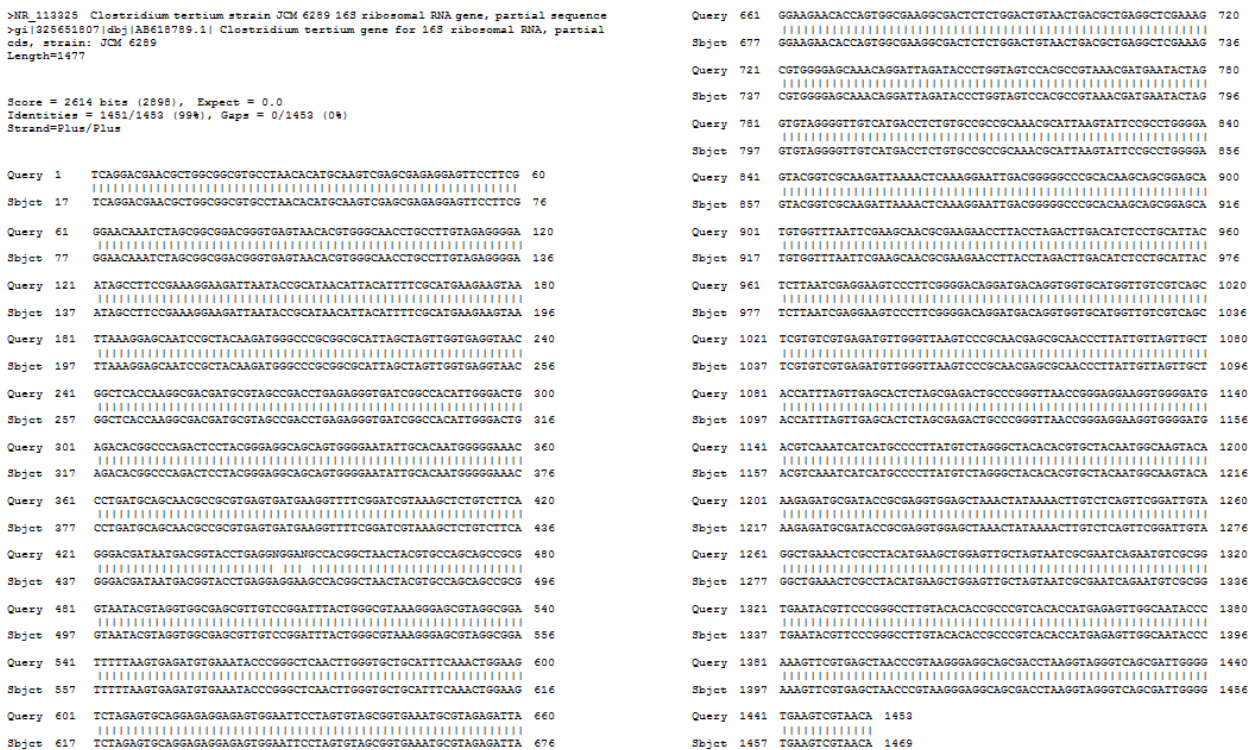

Figure 2. Compared with *C. tertium* strain JCM 6289 16S ribosomal RNA gene. The sequence had 99% similarity.

#### 4. CONCLUSION

This case revealed that *C. tertium* septicemia may occur in a non-neutropenic pediatric patient. In addition, it highlighted the fact that *Clostridium* infection diagnosis should not be dismissed, even if a strain is cultured only in aerobic conditions. Because antibiotic susceptibility testing may exhibit geographical variation, its dosing should be adjusted according to the reference of institutional susceptibility tests.

#### ACKNOWLEDGEMENTS

The authors wish to thank M. Wakuda and J. Ishii for their technical assistance. The authors would like to thank Enago for the English language review.

#### CONFLICTS OF INTEREST DISCLOSURE

The authors declare no conflicts of interest.

#### REFERENCES

- [1] Murray PR, Baron EJ, Jorgensen JH, et al. Manual of Clinical Microbiology 9th edition. Washington, DC: ASM Press. 2007; 1: 889-910. <http://dx.doi.org/10.1186/1471-2261-3-9>
- [2] Miller DL, Brazer S, Murdoch D, et al. Significance of Clostridium tertium bacteremia in neutron and nonneutropenic patients: review of 32 cases. Clin Infect Dis. 2001; 32: 975-8. PMID: 11247721. <http://dx.doi.org/10.1086/319346>
- [3] Henry H. An investing of the cultural reactions of certain anaerobes found in wounds. J Pathol Bacteriol. 1917; 21: 344-85. <http://dx.doi.org/10.1002/path.1700210304>
- [4] King BM, Ranck BA, Daugherty FD, et al. Clostridium tertium septicemia. N Engl J Med. 1963; 269: 467-9. PMID: 14032818. <http://dx.doi.org/10.1056/NEJM196308292690909>
- [5] Speirs G, Warren RE, Rampling A. Clostridium tertium septicemia in patients with neutropenia. J Infect Dis. 1988; 158: 1336-40. PMID: 3198941. <http://dx.doi.org/10.1093/infdis/158.6.1336>
- [6] Coleman N, Speirs G, Khan J, et al. Neutropenic enterocolitis associated with Clostridium tertium. J Clin Pathol. 1993; 46: 180-3. PMID: 8459041. <http://dx.doi.org/10.1136/jcp.46.2.180>
- [7] Gosbell IB, Johnson CG, Newton PJ, et al. Clostridium tertium bacteremia: 2 cases and review. Pathology. 1996; 28: 70-3. PMID: 8714277. <http://dx.doi.org/10.1080/00313029600169573>
- [8] Tappe D, Dirks J, Müller R, et al. Fatal Clostridium tertium septicemia in a nonneutropenic patient. J Infect. 2005; 50: 76-80. PMID: 15603846. <http://dx.doi.org/10.1016/j.jinf.2004.04.005>
- [9] Leegaard TM, Sandven P, Gaustad P. Clostridium tertium: 3 case reports. Scand J Infect Dis. 2005; 37: 230-2. PMID: 15849058. <http://dx.doi.org/10.1080/00365540410020910>
- [10] Vanderhofstad M, André M, Lonchay C, et al. Clostridium tertium bacteremia: contamination or true pathogen? A report of two cases and a review of the literature. Int J Infect Dis. 2010; 14S: 335-7. PMID: 20598605. <http://dx.doi.org/10.1016/j.ijid.2010.03.004>
- [11] Salvador F, Porte L, Durán L, et al. Breakthrough bacteremia due to Clostridium tertium in a patient with neutron fever, and identification by MALDI-TOF mass spectrometry. Int J Infect Dis. 2013; 17: 1062-3. PMID: 23823278. <http://dx.doi.org/10.1016/j.ijid.2013.03.005>