

CASE REPORT

Severe hypercholesterolemia effectively lowered with hemodialysis: a case report

Nicolas Bakinde, John Ekong, Iwayemi Olayeye, Claudia Fotzeu

Morehouse School of Medicine, United States

Correspondence: Iwayemi Olayeye. Address: 720 West View Drive Southwest Atlanta Georgia, United States. E-mail: iolayeye@msm.edu

Received: February 10, 2015

Accepted: April 16, 2015

Online Published: June 12, 2015

DOI: 10.5430/crcp.v2n3p95

URL: <http://dx.doi.org/10.5430/crcp.v2n3p95>

Abstract

Background: Hypercholesterolemia is a known risk factor for cardiovascular morbidity and mortality. Reviews of current literature suggest a linear correlation between the level of low density lipoprotein cholesterol (LDL-C) and the risk of cardiovascular disease. There are no guidelines that specifically address the management of severe hypercholesterolemia related to an underlying pathology or that observed in familial hypercholesterolemia.

Case report: A 49-year-old African American man presented with painless jaundice, generalized itching, and a 30 lbs weight loss in three months. Multiple xanthoma like lesions were noted on his arms. His hepatic panel was normal. His levels of total cholesterol and low density lipoprotein cholesterol were elevated to more than 1,000 mg/dl each. Serum alkaline phosphatase, total bilirubin, and direct bilirubin were elevated at 1,715 U/L, 7.2 mg/dl, and 4.5 mg/dl, respectively. The level of high density lipoprotein cholesterol was undetectable. Anti-mitochondrial antibodies and hepatitis serologies were negative. There was no clinical evidence to suggest familial hypercholesterolemia. Imaging studies of his abdomen were negative for hepatic biliary dilation. A liver biopsy revealed stage 3 fibrosis. His severe hypercholesterolemia was treated with ezetimibe, since statin was contraindicated in this case. In addition to liver fibrosis, the patient developed renal failure that required intermittent hemodialysis. His LDL cholesterol (LDL-C) and total cholesterol (TC) levels trended down with an absolute reduction of 70%.

Conclusion: The treatment of patients with severe hypercholesterolemia should aim at reducing the LDL-C level. We suggest that hemodialysis contributed to the significant reduction of LDL cholesterol level in our case; and therefore might be a potential tool for reducing high LDL-C levels in these patients.

Key words

Hypercholesterolemia, Ezetimibe, Hemodialysis, Fibrotic liver disease

1 Introduction

Hypercholesterolemia is a known risk factor for cardiovascular morbidity and mortality. Reviews of current literature suggest a linear correlation between the level of low density lipoprotein cholesterol (LDL-C) and the risk of cardiovascular disease. There are currently no guidelines that specifically address the management of severe hypercholesterolemia related to an underlying pathology or observed in familial hypercholesterolemia. Here, we present a case of severe hypercho-

lesterolemia effectively lowered by hemodialysis in a patient who had absolute contraindication to statin therapy and refractory to Ezetimibe.

2 Case report

A 49-year-old African American male with a medical history of well-controlled hypertension, diabetes mellitus type 2, and a surgical history significant for splenectomy at the age of 7 (patient did not remember the reason for the splenectomy) who presented to the emergency room complaining of a thirty-pound unintentional weight loss over the past three months despite good appetite, and easy access to food. He also complained of a painless jaundice, generalized itching, and weakness associated with feeling of incomplete bowel emptying. He had no abdominal pain, nausea, or vomiting, and denied any changes in stool caliber, early satiety, dysphagia or odynophagia. He also denied having fever, any recent travel, or sick contact.

Family history was remarkable for gallbladder cancer, diabetes mellitus type 2, and hypertension in his mother. The patient denied use of alcohol, tobacco or any recreational drugs.

The physical examination revealed a middle-aged, ill appearing, non obese man with a blood pressure of 138/86 mmHg, heart rate of 81 beats per minute, respiratory rate of 18 breaths per minute, temperature of 35.7°C, and serum oxygen saturation of 98% on room air. The cardiovascular and pulmonary exams were grossly normal. The abdominal exam showed a non-distended, non-tender abdomen without an enlarged liver. The patient had yellowish tinged skin with multiple scratch marks. There were also multiple xanthoma-like lesions on his arms.

His levels of total cholesterol and low density lipoprotein cholesterol were elevated to more than 1,000 mg/dl each. Serum alkaline phosphatase, bilirubin total and direct were elevated at 1,715 U/L, 7.2 mg/dl, and 4.5 mg/dl, respectively. The level of high density lipoprotein cholesterol was undetectable. Anti-mitochondrial antibodies were negative as well as hepatitis B, C, and E. There was no clinical evidence to suggest familial hypercholesterolemia. Imaging studies of his abdomen were negative for hepatic biliary dilation. A needle biopsy of the liver revealed a grade IV portal/periportal activity with severe interface inflammation. His severe hypercholesterolemia was treated with ezetimibe, since statin was contraindicated due to his active liver disease.

Laboratory examinations on initial admission revealed the following values (the lipid panel is presented separately).

Table 1. Selected laboratory data on admission

Parameter	Value	Normal range
Glucose (mg/dl)	134	70-125
Serum urea nitrogen (mg/dl)	11	8-22
Serum creatinine (mg/dl)	0.8	
Total protein level (mg/dl)	5	6.0-8.3
Albumin (mg/dl)	1.2	3.5-5.0
Total serum bilirubin (mg/dl)	7.2	0.3-1.6
Direct bilirubin (mg/dl)	4.5	< 0.6
Serum AST (u/L)	100	10-42
Serum ALT (u/L)	75	17-63
Serum alkaline phosphatase (u/L)	1,715	38-126

Note. AST: aspartate aminotransferase, ALT: alanine aminotransferase

The patient was admitted to the general medical floor for the work up of painless jaundice. He received symptomatic treatment for the pruritus.

Serial lipid panels are shown in Table 1 and plotted in Figure 1.

In order to determine the tissue source of increased alkaline phosphatase (ALP) activity serum alkaline phosphatase isoenzymes were obtained once during the course of the disease and showed the following pattern: intestinal isoenzymes 3%, bone isoenzymes 10%, liver isoenzymes 46%, macrohepatic isoenzymes 41%. Gamma-glutamyl transferase was elevated at 294 U/L.

Table 2. Serial cholesterol levels T

Days after initial encounter that resulted in hospital admission	T. Chol (mg/dl)	TG (mg/dl)	HDL-C (mg/dl)	LDL-C (mg/dl)
Day 0 (day of first admission)	1,112	225	< 5	1,062
Day 1	1,188	215	< 5	1,140
Day 4	1,132	255	< 5	1,076
Day 8	1,096	247	< 5	1,042
Day 32 (second admission)	972	358	< 5	895
Day 100 (third admission)	741	325	< 5	671
Day 101	556	285	< 5	494
Day 104	500	239	< 5	447
Day 105	527	243	< 5	473
Day 109 (fourth admission)	331	158	10	289

Note. Chol (total cholesterol), TG (triglycerides), HDL-C (high density lipoprotein cholesterol), LDL (low density lipoprotein cholesterol).

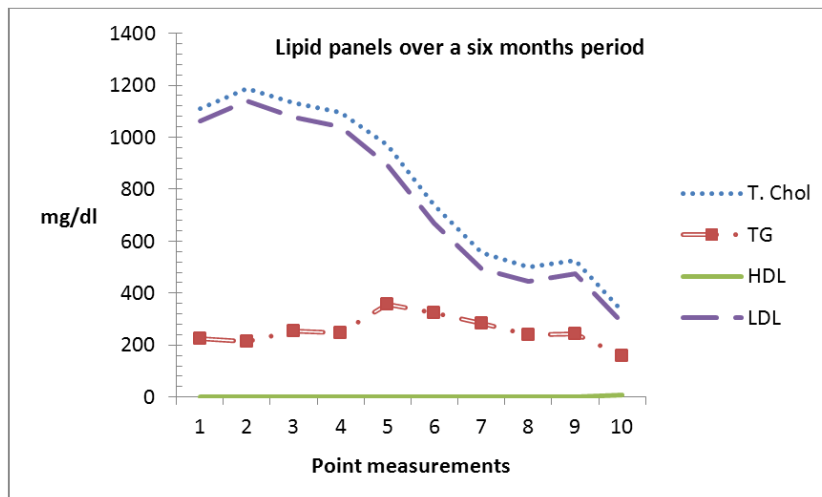


Figure 1. Patient's lipid panels over a six months period

Further laboratory studies revealed a negative viral hepatitis serology (B, C, E), anti-smooth muscle antibody and mitochondrial antibody. HIV serology was also negative as well as serum IgG4, ANA screen was negative. Autoantibodies: dsDNA, SSA, SSB, SM, RNP, JO-1, SCL-70 Centromere-B, and histone were negative. Serum IgG, IgA, IgM were all normal. SPEP was also reported as normal. UPEP was negative for Bence Jones proteins.

Serial electrocardiograms obtained during hospital stay revealed normal sinus rhythm. A magnetic resonance imaging of the abdomen with and without contrast revealed a normal pancreas, a surgically absent spleen and no intrahepatic or extra hepatic biliary abnormalities.

A needle biopsy of the liver revealed a grade IV portal/periportal activity with severe interface inflammation. A grade II lobular activity was also reported with a stage 3 fibrosis.

The clinical course ultimately progressed to renal failure, requiring intermittent hemodialysis. The LDL cholesterol levels progressively trended down with hemodialysis sessions, from over 1,100 mg/dl to about 289 mg/dl over a six months period, an absolute reduction of more than 70%. A similar reduction was noted for total cholesterol levels. Serum alkaline phosphatase also steadily decreased to less than 200 during the course of the disease while bilirubin total and direct remained high at about 11 and 7, respectively, on average. The HDL cholesterol and triglyceride levels remained unchanged. The patient's clinical course, which comprised multiple hospital stays of variable lengths with subspecialty consults, was complicated by end-stage renal failure, hepatic encephalopathy with fatal outcome. No autopsy was performed in accordance with family wishes.

3 Discussion

Cases of hypercholesterolemia of this magnitude in adults without history of familial hypercholesterolemia are rare. The ACC/AHA (American College of Cardiology/American Heart Association) has set guidelines for the management and prevention of high cholesterol levels ^[1], but there are no guidelines addressing principles of management of severe hypercholesterolemia with respect to CAD like those seen in familial hypercholesterolemia cases or those associated with an underlying disease process. Does all high cholesterol level pose a threat to cardiovascular health?

A Canadian study reported a case of severely elevated LDL levels in a middle age, obese, woman with concurrent diabetes mellitus and hypertension. During workup, an Endoscopic Retrograde Cholangiopancreatography (ERCP) revealed an obstructed ampulla of vater that was subsequently relieved and led to the return of lipid levels to baseline ^[2]. Our patient on the other hand, had no evidence of biliary obstruction on Magnetic Resonance Cholangiopancreatography (MRCP). He also had no anti-mitochondrial antibody (AMA). A needle biopsy of the liver revealed a grade IV portal/periportal activity with severe interface inflammation. Although AMA was negative, his lipid profile looked similar to that of patients with PBC. Hepatitis B, C and E were ruled out per serology and there was no evidence to suggest a familial origin of his dyslipidemia since he had almost normal lipid levels three months prior to presentation. Though the disproportionate elevation of serum alkaline phosphatase (more than 10 times the normal) to aminotransferases was suggestive of some form of sclerosing cholangitis as possible underlying etiology, magnetic resonance imaging of the abdomen with and without contrast revealed no obliteration of the intrahepatic or extrahepatic biliary tree and the liver biopsy was not supportive as it failed to demonstrate the highly specific "onion skin" pattern fibrous changes. The diagnosis of primary sclerosing cholangitis (PSC) could therefore not be made with certainty. We entertained the diagnosis of an AMA negative primary biliary cirrhosis (PBC) versus PSC- autoimmune (overlap syndrome). In many cases, hypercholesterolemia may occur secondary to underlying organ pathology like hepatitis B, biliary obstruction, nephrotic syndrome, chronic kidney disease, or hypothyroidism. In our case, the low albumin in our report could be attributed to malnutrition as evidenced by low prealbumin at 10 mg/dl (normal 17-34). We hypothesize, in keeping with observations from Longo *et al.* (2001) ^[3] that in our specific case (and given the lipoprotein pattern - very high LDL but low HDL) malnutrition in conjunction with cholestatic liver disease is the probable culprit for the hypercholesterolemia. There are recommended therapeutic options and dietary guidelines by the ACC/AHA for evaluation and management of hypercholesterolemia ^[1]. Guidelines specifically designed to address severe hypercholesterolemia such as the type seen in our patient have yet to be defined. Though statins are recommended by the ACC/AHA as first-line therapeutics for lowering LDL-C, their use has limitations ^[1]. Our patient could not receive a statin due to abnormal liver function. He was instead started on ezetimibe because of its LDL-C lowering effect particularly in the setting of advanced liver fibrosis ^[4]. Another option for reducing LDL-C in our patient was by LDL apheresis, a technique that has proven to significantly reduce low-density lipoprotein cholesterol in patients with severe hypercholesterolemia and slow the progression of atherosclerosis ^[5]. This option was impractical in light of the high cost and the limited availability ^[6]. In addition to ezetimibe, our patient was started on intermittent hemodialysis later during his clinical course when he developed renal failure. Soon after the first hemodialysis sessions, his total and LDL-C levels showed a sharp downward trend. These acute changes could not be attributed to ezetimibe alone. This suggests that hemodialysis was a major contributor to the significant reduction of LDL-C in our case.

In regards to cardiovascular risk, it is unclear whether the risk of CHD correlates to infinity with such elevations in LDL levels. In cases of severely high LDL levels, medical management with statins may not be feasible due to contraindications. Moreover, most statins were studied among patients with an LDL-C level between 100 mg/dl – 400 mg/dl [7] and familial hypercholesterolemia managed with statin only noted a 35%-40% level reduction which would not have normalized our patient's cholesterol level.

The cause of dyslipidemia may not always be known; therefore, management should be aimed toward reducing LDL-C levels. Awan *et al.*, 2009 [2] suggest that the cardiovascular risk associated with the increase in LDL-C directly correlates with the time of exposure and the severity of the lipoprotein disorder suggesting that prompt lowering of LDL level is crucial. Until we can design a double blinded randomized trial to assess the cardiovascular risk and proper management of hypercholesterolemia in the magnitude presented here, these questions will remain unanswered.

4 Conclusion

Our patient's clinical picture was suggestive of PSC. His LDL-C level was > 1,000 which is extremely rare and as such no studies have been conducted among this patient population. There is a known association between high LDL and the development of cardiovascular atherosclerotic disease necessitating the prompt treatment of hypercholesterolemia. Numerous experimental, epidemiologic, and clinical studies have clearly demonstrated the effects of high LDL-C levels on the cardiovascular system and led to establishment of expert recommendations for the management of dyslipidemia, however little is known about the efficacy of current recommended treatment in patients with LDL-C greater than 1,000.

Although statins are the drug of choice for the management of hypercholesterolemia, most statins were studied among patients with an LDL-C level between 100 mg/dl – 400 mg/dl. It is very unlikely that statins alone could normalize an LDL level of > 1,000. To date, only very few cases of severely elevated LDL cholesterol levels have been reported and as such, there are no published management guidelines. Based on the findings of our case report, hemodialysis significantly lowered our patient's LDL-C, suggesting that hemodialysis could play an important role in the management of hypercholesterolemia in this patient population. We do not think that the decease of the patient compromises the findings of this case report.

Further studies are needed to further evaluate the utility of hemodialysis in severely elevated hypercholesterolemia.

Competing interests

The authors have no relevant conflicts of interest to disclose regarding the preparation of this manuscript.

References

- [1] Stone NJ, Robinson J, Lichtenstein AH, *et al.* 2013 ACC/AHA Guideline on the Treatment of Blood Cholesterol to Reduce Atherosclerotic Cardiovascular Risk in Adults: A Report of the American College of Cardiology/American Heart Association Task Force on Practice Guidelines. *J Am Coll Cardiol.* 2013; Available from: <http://circ.ahajournals.org/content/early/2013/11/11/01.cir.0000437738.63853.7a.full.pdf>
- [2] Awan Z, Bailey D, Hafiane A, *et al.* Acquired severe hypercholesterolemia and hypoalphalipoproteinemia. *Journal of Clinical Lipidology.* 2009; 3: 393-397. PMID: 21291840. <http://dx.doi.org/10.1016/j.jacl.2009.10.001>
- [3] Longo M, Crosignani A, Podda M. Hyperlipidemia in chronic cholestatic liver disease. *Current Treatment Options in Gastroenterology.* 2001; 4(2): 111-114. PMID: 11469968. <http://dx.doi.org/10.1007/s11938-001-0022-6>
- [4] Filippatos TD, Elisaf MS. Role of ezetimibe in non-alcoholic fatty liver disease. *World J Hepatol.* 2011 Oct 27; 3(10): 265-267. PMID: 22059109. <http://dx.doi.org/10.4254/wjh.v3.i10.265>
- [5] Orsoni A, Villard EF, Bruckert E, *et al.* Impact of LDL apheresis on atheroprotective reverse cholesterol transport pathway in familial hypercholesterolemia. *J Lipid Res.* 2012 Apr; 53(4): 767-775. PMID: 22338009. <http://dx.doi.org/10.1194/jlr.M024141>

- [6] Washington, D. C.: U.S. Congress, Office of Technology Assessment, OTA-HCS-23: Health Technology Case Study 23: The Safety, Efficacy, and Cost Effectiveness of Therapeutic Apheresis. This case study was performed as a part of OTA's assessment of Medical Technology and Costs of the Medicare Program, 1983. Available from:
<https://www.princeton.edu/~ota/disk2/1985/8506/850601.PDF>
- [7] Baruch L, Chiong VJ, Agarwal S, *et al.* Discordance of Non-HDL and Directly Measured LDL Cholesterol: Which Lipid Measure is Preferred When Calculated LDL Is Inaccurate? *Cholesterol*. 2013; 2013: 502948. Epub 2013 Apr 23. Available from:
<http://www.ncbi.nlm.nih.gov/pmc/articles/PMC3655460/>