

CASE REPORT

Mesenchymal hamartoma of the larynx: A rare case report and review of literature

Jumana A. Amir¹, Salwa S. Sheikh²

1. Medical College, University of Dammam, Dhahran, Saudi Arabia. 2. Pathology Services Division, Johns Hopkins Aramco Health Care, Dhahran, Saudi Arabia.

Correspondence: Jumana A. Amir. Address: P.O. Box: 12113, Dhahran 31311, Saudi Arabia. E-mail: j.amir523@gmail.com

Received: January 31, 2015

Accepted: March 26, 2015

Online Published: March 31, 2015

DOI: 10.5430/crcp.v2n3p40

URL: <http://dx.doi.org/10.5430/crcp.v2n3p40>

Abstract

Hamartoma of the larynx is a rare benign developmental anomaly that must be distinguished from other neoplastic and non-neoplastic lesions of the larynx. Most cases come to medical attention due to symptoms related to airway obstruction. Only one case is reported in literature where the lesion was associated with vocal cord paralysis. We herein, present a 68 years old woman who was admitted to the hospital with hoarseness, dysphagia, and left vocal cord paralysis. A laryngeal lesion was identified and on biopsy was diagnosed to be mesenchymal hamartoma. Although it was incompletely excised, the patient has no evidence of recurrence or relapse of her symptoms seven years post-operatively.

Key words

Larynx, Hamartoma, Upper airway, Vocal cord

1 Introduction

Hamartomas are rare benign non-neoplastic developmental anomalies that form tumor-like nodules or masses consisting of mature tissue elements indigenous to the site they arise from. The tissue elements either present in abnormal proportions or show a haphazard disorganized arrangement. Hamartomas can involve any part of the body including lungs, liver, spleen and pancreas. Head and neck hamartomas are extremely uncommon and those arising from the larynx, in particular, are considered rare. To the best of our knowledge, no more than 35 cases of laryngeal hamartomas have been reported in literature thus far. We report a case of laryngeal hamartoma in a 68 year old woman who presented with hoarseness, dysphagia, and vocal cord paralysis.

2 Case presentation

A 68 year old female presented to the ear, nose, and throat (ENT) service with left ear ache, dysphagia, hoarseness, and deafness of two weeks duration. Upon examination, she was found to have left otitis media and left vocal cord paralysis. Computer tomography (CT) scan of the neck and mediastinum was done which revealed thickened and swollen prominent left epiglottic fold. The patient underwent panendoscopy with oroendotracheal intubation. Using a suspension laryngoscope and microscope, examination of the larynx was done. The left subglottic area showed a fleshy nodular mass

measuring approximately 2 cm in size. The left arytenoid and aryepiglottic area looked swollen and prominent. Biopsies were taken from the left subglottic area, left arytenoid & aryepiglottic prominence, left lateral wall of the nasopharynx that appeared full, and fossa of Rosenmuller. Rigid bronchoscopy was done and showed no abnormalities. Rigid esophagoscopy was done to examine the post cricoid area. No lesion was identified in the esophagus. The patient tolerated the procedure well and was discharged home with no complications. Histopathological examination of the left arytenoid mass showed a well delineated lesion consisting predominantly of haphazardly distributed clusters of mature adipose tissue and lobules of nodular chondroid tissue. Scattered in-between, there were many nerves and variably-sized blood vessels present in a myxoid background with focal areas of mild chronic inflammation and edema (see the figure). These features were diagnostic of a benign mesenchymal hamartomata involving the left arytenoid. Biopsies from the left subglottic area showed only myxoid changes and edema. All the remaining biopsies showed no significant histopathologic findings. Although the lesion was not completely excised, there is no evidence of recurrence and the patient is asymptomatic seven years after her surgery.

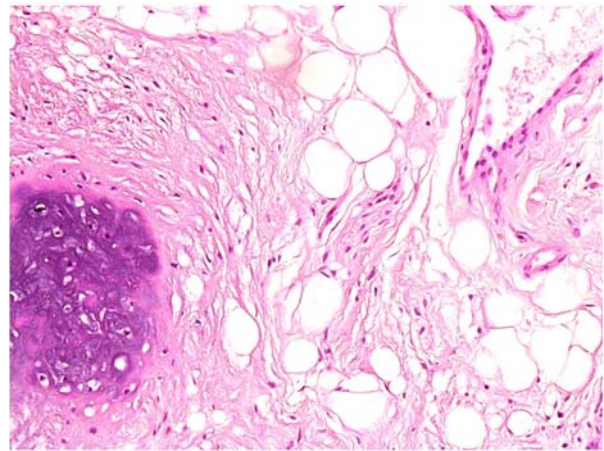


Figure. Histopathology shows nodular chondroid tissue, haphazardly distributed clusters of mature adipose tissue, abundant nerves and vessels in a background of myxoid changes.

3 Discussion

According to the World Health Organization (WHO) classification and definition, “Hamartoma is defined as a developmental anomaly characterized by the formation of a tumor-like mass composed of mature tissue elements that are normally present in the location where it is found but occurring in abnormal proportions or arrangement”^[1]. The term “hamartoma” is derived from the Greek word “hamartanein” which means “to go wrong”^[2]. In 1904 Albrecht introduced the term “hamartoma” to distinguish the hamartoma, a tumor-like malformation, from a true neoplasm^[3]. Multiple hamartomas involving different locations are referred to as “Pleiotropic hamartomas”.

Hamartomas are benign lesions that may occur throughout the body involving any organ such as liver, lung, kidney, spleen, and pancreas. Hamartomas of the head and neck are uncommonly seen and are occasionally described in the sinonasal tract, nasopharynx, oropharynx, oral cavity, larynx, hypopharynx, cervical esophagus, ear, parotid gland, trachea, parathyroid gland, and eye^[2]. Hamartomas of the larynx are however, extremely rare especially if inadequately described cases in the literature are excluded. Thus far, less than 35 cases of well-documented laryngeal hamartomas are reported in literature. This entity is more commonly seen in males with two peaks of involvement, one during early childhood, and the other involving middle age group (26-75 years old).

The clinical presentation of laryngeal hamartoma is identical to any other laryngeal lesion with symptoms mostly related to the site rather than the nature of the lesion itself. Most patients present with dysphonia or dysphagia, respiratory obstruction, choking, cough, hoarseness, or stridor^[4]. Only one case is reported to be associated with vocal cord paralysis^[5]. Although rarely seen in the larynx, hamartoma should be kept in mind as a differential diagnosis of an obstructing lesion of the upper airway. Clinically, the differential diagnoses of a laryngeal lesion include benign laryngeal

polyp or nodule, cyst, and benign or malignant neoplasm. These lesions can be easily identified and distinguished histologically. A laryngeal polyp shows prominent myxoid changes at an early stage and more hyalinization and fibrosis at later stages. A laryngeal cyst shows a cystic structure with a definitive epithelial lining. Tumors, in general, exhibit solid growth of neoplastic epithelial cells, with malignant tumors often showing cytologic atypia, nuclear pleomorphism, and increased mitotic figures.

Hamartomas are submucosal lesions that are mostly not encapsulated and have ill-defined margins. These lesions are characterized by disorganized and haphazard growth of mature tissue elements that may include epithelial or mesenchymal tissue. Hamartomas that contain mesodermal cells and lack epithelial components are referred to as "Mesenchymal hamartomas". "Glandular or epithelial hamartomas", on the other hand, refer to those containing epithelial or glandular tissue admixed with the mesodermal elements^[4].

Histopathologically these lesions should be distinguished from other lesions exhibiting haphazard proliferation of a variety of mature cellular elements such as choristomas, teratomas, and rhabdomyomas. In pediatric age group, it is crucial to distinguish hamartomas from congenital lesions like choristomas and teratomas. Choristoma or heterotopia is a benign developmental anomaly where there is proliferation and growth of mature tissue that is not indigenous to the anatomic site the lesion is arising from. This is in contrast to the hamartoma where there is growth of mature tissue that is native to the organ of involvement. Teratoma is a germ cell tumor that shows proliferation of cells mostly derived from all three germ cell layers. This neoplasm may be benign, with proliferation of mature or normal cells and tissue, or malignant exhibiting proliferation of immature tissue elements^[2, 4].

The presence of skeletal muscle fibers in some hamartomas may bring rhabdomyoma into the differential diagnosis. Rhabdomyoma is a rare benign tumor of striated skeletal muscle fibers. It is divided into cardiac and extra-cardiac types. The extracardiac forms of rhabdomyoma are subclassified into three distinct categories; adult type, fetal type, and genital type. The adult type is mostly seen in the head and neck region of older men usually above the age of 40 and is characterized by proliferation of large polygonal cells with abundant eosinophilic, granular, or vacuolated cytoplasm with focal cross-striations^[6]. If it involves the tongue or pharynx, it may present with hoarseness, difficulty in breathing, or difficulty in swallowing. Fetal rhabdomyoma is mostly seen in children between birth and three years of age involving the subcutaneous tissue of the head and neck region. Histologically, there is spindle cell proliferation with elongated cells that have indistinct cytoplasm. These cells resemble the striated muscle fibers seen during intrauterine development, and hence are called fetal type. The third type, genital rhabdomyoma, most often involves the vagina or vulva of young to middle-aged women and presents as a polypoid or cyst-like mass^[7]. Histopathologic examination reveals a mixture of fibroblast-like cells and clusters of mature appearing cells with distinct cross-striations that are present in a background of varying amounts of collagen and mucoid material. Cardiac rhabdomyomas, on the other hand, typically develop in utero and are often detected by prenatal ultrasound. They are considered as hamartomatous lesions that are often seen in pediatric age group and are frequently associated with tuberous sclerosis, sebaceous adenomas, and hamartomas of kidneys and other organs^[8].

The recommended management of laryngeal hamartomas is conservative with complete excision of the lesion. Rare cases with hemilaryngectomy have been published in literature^[9]. Recurrence is reported in 20% of cases and is usually associated with incomplete excision of the lesion^[5]. Overall prognosis is excellent, however, one patient had a fatal outcome due to breathing difficulty^[10].

To the best of our knowledge, no more than 35 well-documented cases of laryngeal hamartomas have been reported in literature^[2-5, 11-18].

We herein, present an interesting and rare case of a 68 years old woman with a mesenchymal laryngeal hamartoma causing vocal cord paralysis. She had incomplete excision of the lesion, and remains asymptomatic seven years after her initial diagnosis.

References

- [1] Sobin L, Shanmugaratnam K. The world health organization histological classification of tumours of the upper respiratory tract and ear. A commentary on the second edition. *Cancer*. 1993; 71: 2689-2697.
- [2] Rinaldo A, Minnara G, Fischer C, *et al.* Hamartoma of the larynx: a critical review of the literature. *Ann Otol Rhinol Laryngol*. 1998; 107: 264-267. PMID: 9525251. <http://dx.doi.org/10.1177/000348949810700314>
- [3] Albrecht E. Ueber hamartoma. *Verh Dtsch Ges Pathol*. 1904; 7: 153-157.
- [4] Triglia J, Paganelli A, Roman S, *et al.* A very large laryngeal hamartoma in a 4 year-old child: Diagnosis and management. *International Journal of Pediatric Otorhinolaryngology Extra*. 2011; 6: 282-284. <http://dx.doi.org/10.1016/j.pedex.2011.01.004>
- [5] Colon J, Jang D, Signore A, *et al.* Hamartoma of the Larynx: A Report of Two Cases. *The Laryngoscope*. 2011; 121: S128-S128. <http://dx.doi.org/10.1002/lary.22005>
- [6] Katenkamp D, Hansen T. Rhabdomyoma of the head and neck: morphology and differential diagnosis. *Virchows Archiv*. 2005; 447: 849-854. PMID: 16133368. <http://dx.doi.org/10.1007/s00428-005-0038-8>
- [7] Iversen U. Two cases of benign vaginal rhabdomyoma. *Case reports. APMIS*. 1996; 104: 575-578. PMID: 8920811. <http://dx.doi.org/10.1111/j.1699-0463.1996.tb04913.x>
- [8] Kelekci S, Yazicioglu H, Yilmaz B, *et al.* Cardiac rhabdomyoma with tuberous sclerosis: a case report. *J Reprod Med*. 2005; 50: 550-552. PMID: 16130856.
- [9] McGill T, Crockett D, Archer S. Hamartoma of the larynx: report of two cases and review of the literature. *International Journal of Pediatric Otorhinolaryngology*. 1988; 16: 237-243. [http://dx.doi.org/10.1016/0165-5876\(88\)90035-3](http://dx.doi.org/10.1016/0165-5876(88)90035-3)
- [10] Lyons T, Variend S. Posterior cleft larynx associated with hamartoma: a case report and literature review. *J Laryngol Otol*. 1988; 102: 471-472. PMID: 3294316. <http://dx.doi.org/10.1017/S0022215100105389>
- [11] Windfuhur J. Laryngeal hamartoma. *Acta Otolaryngol*. 2004; 124: 301-308. <http://dx.doi.org/10.1080/00016480310014831>
- [12] Makitie A, Lehtonen H, Back L, *et al.* Hamartoma of the larynx: an unusual cause of dyspnea. *Ann Otol Rhinol Laryngol*. 2003; 112: 841-843. PMID: 14587973. <http://dx.doi.org/10.1177/000348940311201003>
- [13] Buckmire R. Bilateral Obstructing Laryngeal Epithelial Adenomatous Hamartomas. *Archives of Otolaryngology - Head and Neck Surgery*. 2005; 131: 259-261. PMID: 15781770. <http://dx.doi.org/10.1001/archotol.131.3.259>
- [14] Franchi A, Baggi R, Mirabile L, *et al.* Glandular hamartoma of the larynx: Report of a case. *Auris Nasus Larynx*. 2008; 35: 149-151. PMID: 17851000. <http://dx.doi.org/10.1016/j.anl.2007.03.015>
- [15] Asal K, Ceylan A, Akyol G, *et al.* Hamartoma of the larynx: an unusual cause of upper airway obstruction. *European archives of oto-rhino-laryngology*. 2004; 261: 435-438. PMID: 14624305.
- [16] Wang E, Li D, Chen W. Laryngeal hamartoma: a case report and review of literature. *Zhonghua Er Bi Yan Hou Tou Jing Wai Ke Za Zhi*. 2011; 46: 518-519. PMID: 21924109.
- [17] Karahan F, Acar B, Acar M, *et al.* Laryngeal Fibrous Hamartoma Presenting With Airway Obstruction at Birth. *Journal of Craniofacial Surgery*. 2013; 24: e383-e384. PMID: 23851877. <http://dx.doi.org/10.1097/SCS.0b013e31829031fd>
- [18] Rizzi M, Mckay E, Cheng J. Congenital laryngeal hamartoma with ectopic thymus causing airway compromise in a neonate. *International Journal of Pediatric Otorhinolaryngology Extra*. 2013; 8: e13-e15. <http://dx.doi.org/10.1016/j.pedex.2012.11.003>