

## CASE REPORT

# Heterotopic thyroid tissue of the uvula

Wilson I. B. Onuigbo<sup>1</sup>, I. J. Okorafor<sup>2</sup>

1. Department of Pathology, Medical Foundation and Clinic, Enugu, Nigeria. 2. Department of Surgery, St Simon's Clinic, Enugu, Nigeria.

**Correspondence:** Prof. Wilson Onuigbo. Address: Department of Pathology, Medical Foundation and Clinic, Enugu, Nigeria. E-mail: wilson.onuigbo@gmail.com

**Received:** July 29, 2014

**Accepted:** September 28, 2014

**Online Published:** October 24, 2014

**DOI:** 10.5430/crcp.v2n1p72

**URL:** <http://dx.doi.org/10.5430/crcp.v2n1p72>

## Abstract

It is acknowledged that the uvula's "structure's function appears in the literature in only the briefest fashion". It has also been declared that "Disorders of the palatal uvula are one of the least highlighted areas of medical literature". Therefore, we present a most rare case of heterotopic thyroid tissue found in this organ in Nigeria. It is an addition to the worldwide appreciation of this unique entity.

## Key words

Thyroid, Uvula, Heterotopias, Epidemiology, Nigeria

## 1 Introduction

A case study of the literature reveals the acknowledged paucity of articles on diseases of the uvula<sup>[1, 2]</sup>. Neither the encyclopedic Ackerman's Surgical Anatomy<sup>[3]</sup> nor the celebrated Muir's Textbook of Pathology<sup>[4]</sup> index it. With regard to the Internet search, the most striking finding was in respect of the paper by Sahu, Agarwal and Husain *et al.*<sup>[5]</sup> Apart from their 19 citations, the message was immense thus: "Thyroid ectopia has been described in the anterior tongue, submandibular region, larynx, trachea, parotid gland, posterolateral area of the neck, within the branchial cyst and at the carotid bifurcation. Esophagus, mediastinum, pericardium, lateral wall of heart (right ventricle), lungs, diaphragm and axilla are the sites described in the chest. In the abdomen, ectopic thyroids are reported in the liver, gallbladder, pancreas, duodenum, porta hepatis and adrenal gland. Pelvic ectopic thyroids are seen in the vagina."

Therefore, from Nigeria, we present a case in which its lesion was found to be in the uvula which was not mentioned in their long list.

## 2 Case report

### 2.1 Clinical history

A 32-year-old man presented with recurrent sore throat, foreign body sensation and lump in the throat, which made him hawk to clear the throat since 10 years. He experienced several attacks yearly with associated heavy snoring, occasional choking sensation disturbing the sleep, mouth breathing and dryness of the throat. On examination, he was apparently healthy looking, not pale but afebrile, anicteric, and not in any respiratory distress. The oral cavity and oropharynx

revealed moderately large hyperemic tonsils with abnormally enlarged uvula. There was hyperemia of the faucial pillars and soft palate as well as granular pharyngeal walls. The neck, the thyroid gland, nasal and aural examinations did not reveal any significant abnormalities.

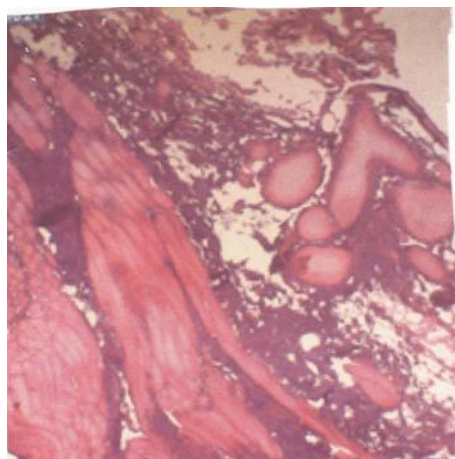
The investigations carried out showed: Normal chest X-ray and X-ray paranasal sinuses; Genotype, AA; Blood group, ORh + ve; ESR, 8 mm/hr (Westergreen); Hb, 14 gm; WBC, 4,400/mm<sup>3</sup>; Neutrophils, 71%; Lymphocytes, 28%; Platelet count, 216,000/mm<sup>3</sup> (100,000-400,000); and HIV Screening, Negative to I & II antibodies. Thyroid function tests were normal. Ultrasound of the neck showed normal thyroid gland. The abdominopelvic sonogram, liver function test, renal function test and the other investigations ruled out any lesions anywhere in the body.

The surgical treatment comprised bilateral tonsillectomy and uvulectomy. His recovery has been uneventful for almost two years.

## 2.2 Pathology

The junior author, IJO, submitted material for pathologic examination. It consisted of four brownish fragments measuring up to 1.5 cm across.

Histological examination by the senior author, WIBO, revealed the presence of striated muscle fibres with juxtaposed colloid follicles. The individual cells showed no abnormalities (see the figure). Also noted were nonspecific chronic inflammatory cells and fibrotic elements.



**Figure.** Striated muscle fibers and thyroid follicles as well as stroma infiltrated with inflammatory cells. (H&E  $\times$  400).

## 3 Discussion

Heterotopy is the result of developmental anomaly [6]. In this case, there was the presence of normal thyroid tissue well outside its cervical position. The presence of striated muscle fibres is due undoubtedly to the thyroid lesion being a portion of the uvula architecture. Surgical treatment resulted in cure. At follow-up almost two years after, the patient's recovery has been uneventful.

As our search of the literature revealed published examples from countries as distant apart as Himalaya [5], Czech Republic [7], India [8], Italy [9], Japan [10], Korea [11], Turkey [12], and USA [13, 14], we deem it interesting to add our Nigerian case. Moreover, it is in keeping with the advice from a British Research Group [15] to the effect that a histopathology data pool is useful in epidemiological analysis. It is from such a pool that the present paper surfaced. Indeed, it represents the sole example in the pool established by the senior author in 1970.

## References

- [1] Richardson GS, Pullen EM. The uvula. Its structure and function and its importance. *Arch Otolaryngol.* 1948; 47: 379-394. <http://dx.doi.org/10.1001/archotol.1948.00690030401001>
- [2] Achalli S, Bhat S, Shetty SR, Babu SG, Suvama R. Deformities of the uvula in the oral cavity-a case series. *Iran Red Crescent Med J.* 2012; 14: 676-679. PMID: 23285421.
- [3] Rosai J. *Ackerman's Surgical Pathology.* 8th Ed., St Louis: Mos. 1996.
- [4] Mac Sween RMN, Whaley K. *Muir's Textbook of Pathology.* 13th Ed, London: Arnold. 1997.
- [5] Sahu S, Agarwal P, Husain M, *et al.* Right supraclavicular ectopic thyroid: An unusual site of presentation. *Internet J. Surg.* 2006; 13(1).
- [6] Garcia MG, Avila CG, Arranz JSP, Garcia JG. Heterotopic brain tissue in the oral cavity. *Oral Surg Oral Med Oral Pathol.* 1988; 66: 218-222. [http://dx.doi.org/10.1016/0030-4220\(88\)90096-5](http://dx.doi.org/10.1016/0030-4220(88)90096-5)
- [7] Astl J, Betka J, Vleck P. Heterotopy of thyroid tissue – A modified therapeutical approach. *Neuroendocrinol Letters.* 2001; 22: 263-269. PMID: 11524634.
- [8] Mysorekar VV, Dandekar CP, Sreevathsa MR. Ectopic thyroid tissue in the parotid salivary gland. *Singapore Med. J.* 2004; 45: 437-438. PMID: 15334289.
- [9] Fumarola A, Trimboli P, Cavaliere R, *et al.* Thyroid papillary carcinoma arising in ectopic thyroid tissue within a neck branchial cyst. *World J. Surg. Oncol.* 2006; 4: 24. PMID: 16672060. <http://dx.doi.org/10.1186/1477-7819-4-24>
- [10] Hagiuda J, Kuroda I, Tsukamoto T, *et al.* Ectopic thyroid in an adrenal mass: a case report. *BMC Urol.* 2006; 6: 18. PMID: 16899136. <http://dx.doi.org/10.1186/1471-2490-6-18>
- [11] Baik SH, Choi JH, Lee HM. Dual ectopic thyroid. *Eur Arch Otorhinolaryngol.* 2002; 259: 105-107. PMID: 11954930. <http://dx.doi.org/10.1007/s00405-001-0419-9>
- [12] Karapolat S, Bulut I. Ectopic posterior mediastinal thyroid: a case report. *Cases J.* 2008; 1: 53. PMID: 18644151. <http://dx.doi.org/10.1186/1757-1626-1-53>
- [13] Pavlenko A, Mirani N, Harrison L, Heller DS. A 51-year-old woman with an inguinal mass. *Arch. Pathol. Lab. Med.* 2005; 129: e212-e213. PMID: 16329739.
- [14] Damiano A, Glickman AB, Rubin JS, Cohen AF. Ectopic thyroid tissue presenting as a midline neck mass. *Int. J. Pediatr Otorhinolaryngol.* 1996; 34: 141-148. [http://dx.doi.org/10.1016/0165-5876\(95\)01229-X](http://dx.doi.org/10.1016/0165-5876(95)01229-X)
- [15] Macartney JC, Rollason TP, Codling BW. Use of a histopathology data pool for epidemiological analysis. *J Clin Pathol.* 1980; 33: 351-355. PMID: 7400335. <http://dx.doi.org/10.1136/jcp.33.4.351>