

## CASE REPORT

# A confluence of rarities: post sedation neuroexcitation following adrenal perineurioma resection

Vivek Somasundaram\*<sup>1</sup>, Matthew C. Hernandez<sup>2</sup>, Blake A. Ebner<sup>3</sup>, Andrew L. Folpe<sup>3</sup>, Joaquin J. Garcia<sup>3</sup>, Travis J. McKenzie<sup>2</sup>

<sup>1</sup>Mayo Clinic Alix School of Medicine, United States

<sup>2</sup>Mayo Clinic Department of Surgery, United States

<sup>3</sup>Mayo Clinic Department of Pathology, United States

**Received:** August 19, 2021

**Accepted:** October 5, 2021

**Online Published:** November 8, 2021

**DOI:** 10.5430/crcp.v8n1p40

**URL:** <https://doi.org/10.5430/crcp.v8n1p40>

## ABSTRACT

Adrenal masses are frequently discovered incidentally and warrant further workup to explore the etiology of the mass. We present the case of a patient who had an incidentally discovered nonfunctional adrenal mass, which was determined to be a perineurioma. This is the first case report, to our knowledge of a perineurioma occurring in this location. Additionally, we report an episode of post sedation excitation, or “propofol frenzy” in the same patient to add to the clinical spectrum of presentation of this phenomenon.

**Key Words:** Adrenal, Perineurioma, Propofol frenzy, Post sedation excitation

## 1. INTRODUCTION

Perineuriomas are peripheral nerve sheath tumors made of perineurial cells that can either occur intraneurally, or extraneurally as a soft tissue tumor.<sup>[1]</sup> First distinguished from neurofibromas in 1978, these masses tend to present in patients who are middle aged and can cause neurological symptoms secondary to mass effect.<sup>[1,2]</sup> These masses also tend to present most often in the subcuticular layer and on the extremities or trunk.<sup>[3,4]</sup> We would like to present what we believe is the first reported case of a soft tissue perineuronal tumor presenting as an adrenal mass in the literature. Though there have been previous reports of retroperitoneal soft tissue perineuriomas, we believe that this is the first reported case of an adrenal soft tissue perineuriomas in the literature.<sup>[5]</sup>

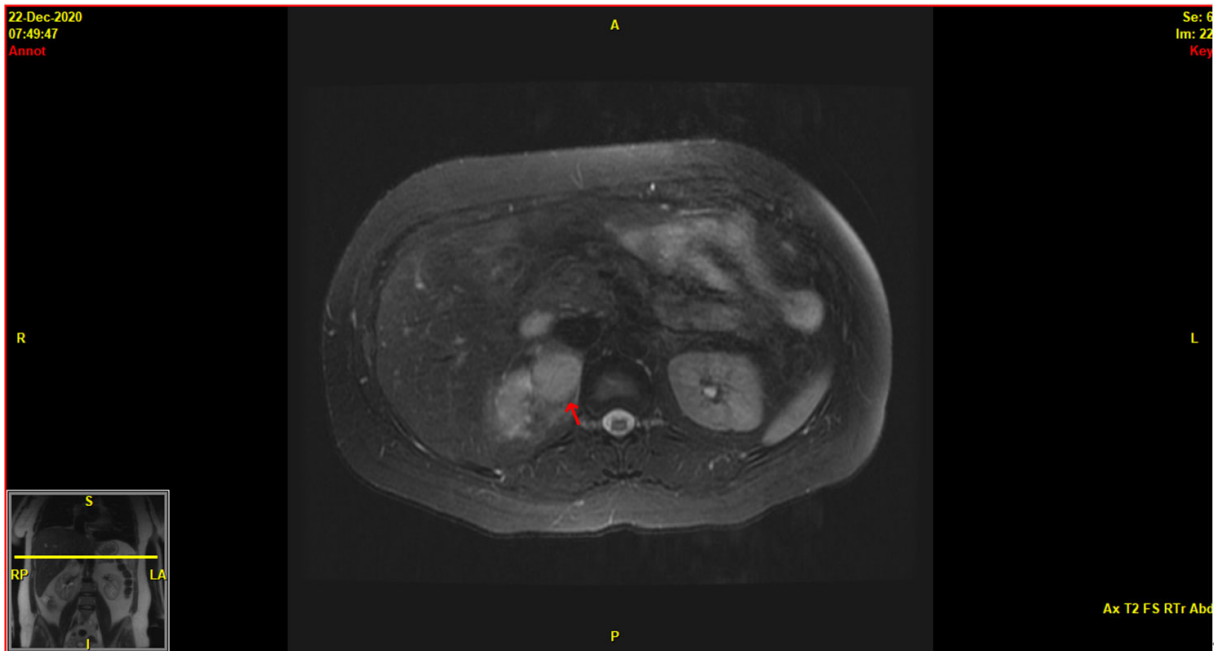
Additionally, we report a case of seizure like activity believed to be caused by propofol following emergence from anes-

thesia following resection of this mass in the same patient. Though this phenomena is well documented in the literature, we wanted to include this episode to add an additional presentation of seizure like phenomena associated with propofol to the literature.<sup>[6-9]</sup>

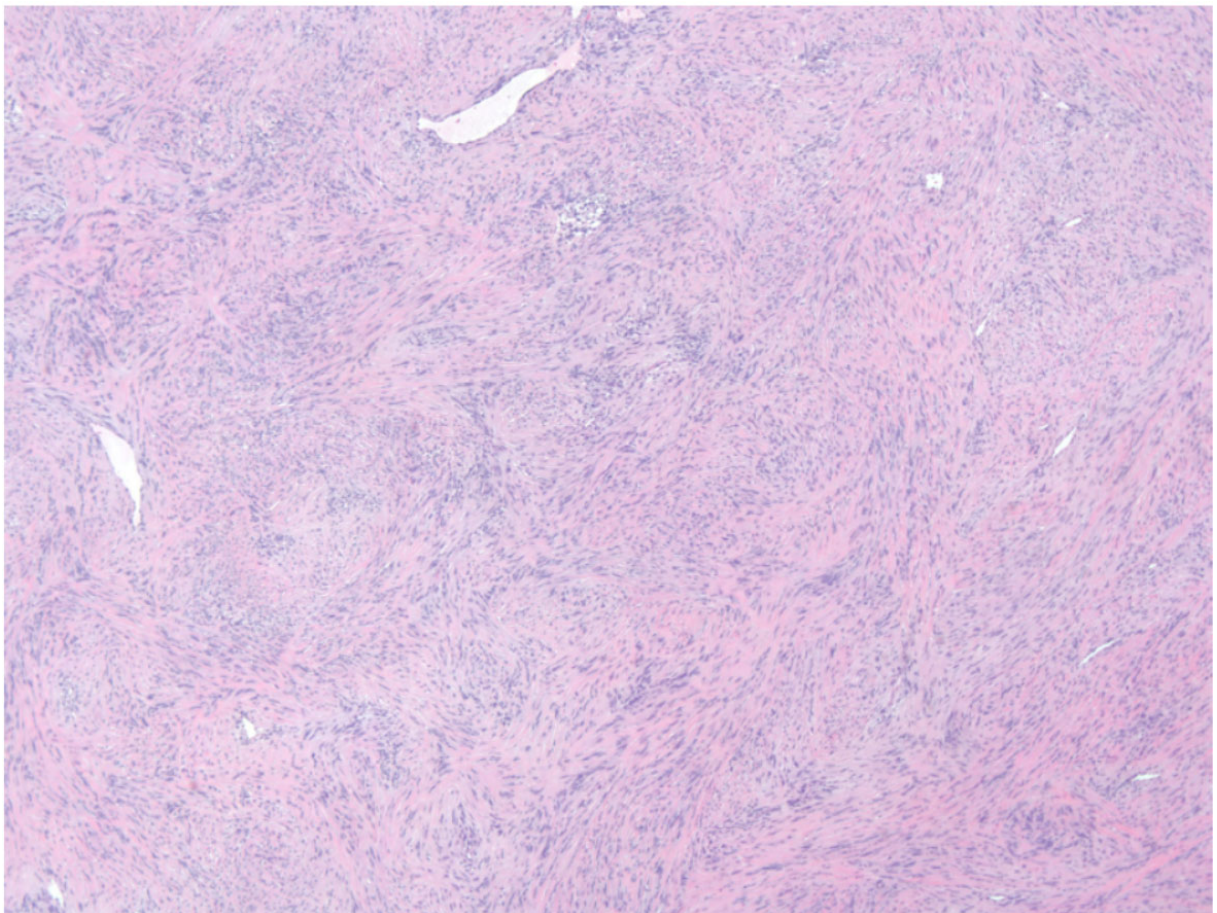
## 2. CASE PRESENTATION

After an episode of post-partum intra-abdominal hemorrhage, a CT scan with and without contrast were obtained in a 30-year-old female and a 3.3 cm adrenal mass was found incidentally. The mass demonstrated mild contrast enhancement at 42 Hounsfield units and did not meet the criteria for an adenoma. Past medical history for the patient included depression, hypothyroidism, occipital encephalomalacia, low-grade mucinous appendiceal neoplasm (LMAN) and treated Hodgkin’s lymphoma. Her medications included 125 mcg of levothyroxine and 100 mg of sertraline daily.

\*Correspondence: Vivek Somasundaram; Email: [somasundaram.vivek@mayo.edu](mailto:somasundaram.vivek@mayo.edu); Address: Mayo Clinic Alix School of Medicine, United States



**Figure 1.** MRI Imaging Adrenal Gland. MRI imaging showing right adrenal mass with a heterogeneously increased T2 signal, diffusion restriction, no fat and moderate vascularity



**Figure 2.** Light microscopy of Adrenal Perineurioma. High resolution microscopy image (Hematoxylin and eosin stain, 4x magnification) of the resected adrenal perineurioma. Tumor cells (indicated by arrowheads) and scale bar equals 500  $\mu$ m

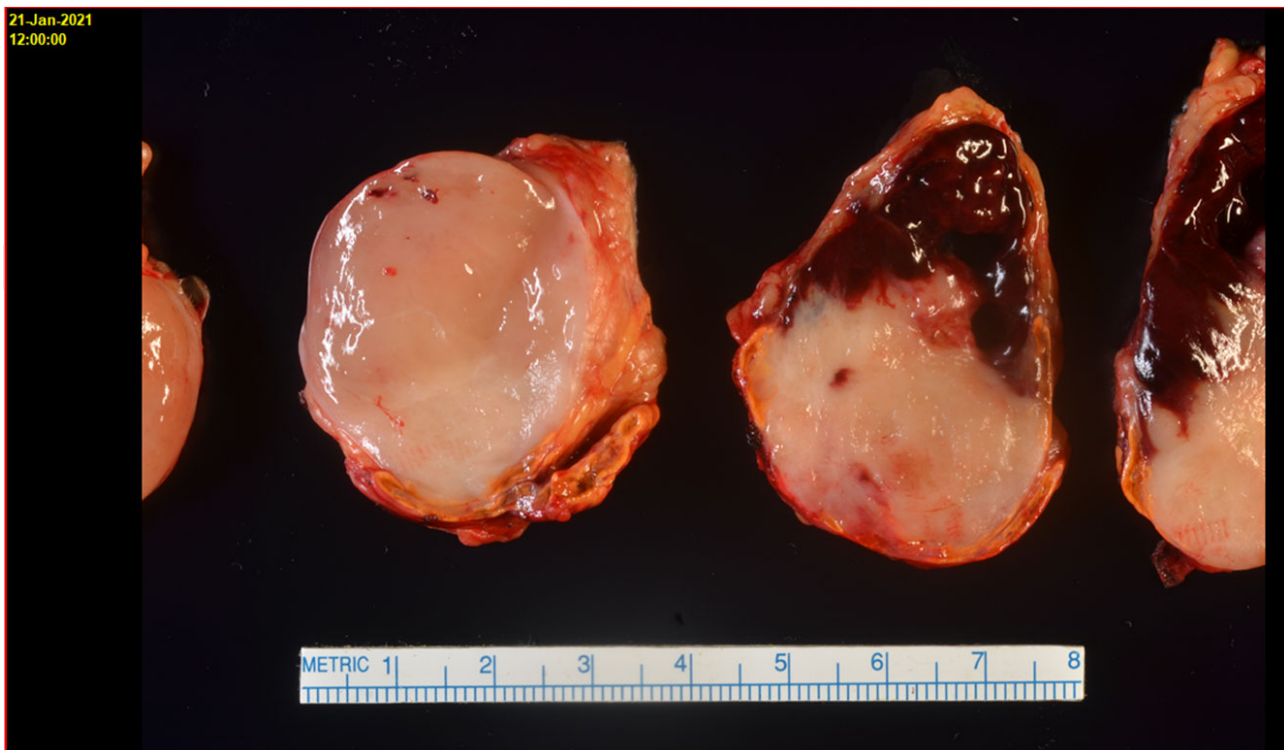
At an interval of 20 months from discovery of the adrenal mass, an MRI with contrast was performed. This demonstrated growth of the mass from 3.3 to 4.9 cm and had a heterogeneously increased T2 signal, diffusion restriction, and no fat and moderate vascularity. Biochemical analysis did not demonstrate elevated plasma metanephrines, cortisol excess, androgen excess, or aldosterone excess. A metabolomic urine profile also indicated this mass was not likely to be an adrenal cortical cancer.

Though the mass was nonfunctional, the increase in mass warranted surgical intervention to remove the adrenal gland and to characterize the mass. As a result, the patient underwent a posterior laparoscopic right adrenalectomy for management of the adrenal mass under general anesthesia. Anesthetic agents included propofol, fentanyl, lidocaine, and vecuronium. Postoperatively, the patient was vitally stable with a temperature of 36 degrees C, HR 105 beats per minute, RR 16 breaths per minute, BP 117/81 mmHg and SPO2 97% on room air at 11:30 am. However, about 8 minutes later the patient became hypertensive to 152/107 and tachycardic to 122 bpm and experienced tonic clonic like movement with

posturing and reduced consciousness. Oxygen saturation was stable during this time and point of care glucose was 102 mg/dL.

10 mg of labetalol and 30 mg of propofol were administered with resolution of the motor activity and hemodynamics. A few minutes later the motor activity occurred again and resolved after an additional 30 mg bolus of propofol. About 10 minutes later, the patient had another episode of repetitive movement, which was resolved with an additional 30 mg bolus of propofol (1,210) and 2 mg of midazolam (1,208). The ECG, basic metabolic panel, and venous blood gas are remarkable for an increased lactate at 3.3 mmol/L, a mildly elevated alanine and aspartate aminotransferases at 63 U/L and 74 U/L respectively, and a mild leukocytosis to 11.3x10<sup>9</sup> cells/L.

Grossly, the excised adrenal mass showed a well-circumscribed tan brown mass with an area of hemorrhage in the adrenal medulla. Immunohistochemistry performed on the lesion determined the lesion was positive epithelial membrane antigen, and negative for S100, and CD34 indicating the adrenal mass is made of perineural tissue.



**Figure 3.** Gross cross section of adrenal gland. Cross sectional image of resected adrenal mass showing a tan brown lesion with an area of hemorrhage.

### 3. DISCUSSION

The pathology indicating that this patient's adrenal mass being a perineurioma is exceedingly rare. This case presents what we believe is the first reported case of a soft tissue perineuronal tumor presenting as an adrenal mass in the literature. Though there have been previous reports of retroperitoneal soft tissue perineuriomas, we believe that this is the first reported case of an adrenal soft tissue perineuriomas in the literature.<sup>[5]</sup>

Perineuriomas are peripheral nerve sheath tumors made of perineurial cells that can either occur intraneurally, or extraneurally as a soft tissue tumor.<sup>[1]</sup> First distinguished from neurofibromas by Lazarus et al in 1978, these masses tend to present in patients who are middle aged and can cause neurological symptoms secondary to mass effect.<sup>[1,2]</sup> These masses also tend to present most often in the subcuticular layer and on the extremities or trunk.<sup>[3,4]</sup> Though they are usually benign, a study done at the Mayo Clinic by Hirose et al found perineuriomas are a rare source of malignant peripheral nerve sheath tumors, with the study ascribing perineural differentiation to 4% of the tumors studied.<sup>[10]</sup> Intraneural perineuriomas tend to have a predilection for middle aged women, and cause symptoms secondary to mass effect.<sup>[1]</sup> Extraneural perineuriomas, on the other hand, do not have a preferred age or sex. These tumors often remain asymptomatic but surgical resection is the preferred treatment for masses that cause neurological deficits or pain, and they do not seem to recur after resection.<sup>[1]</sup> The most frequent clinical presentation of a retroperitoneal nerve sheath or nerve associated tumor is back or pelvic pain. Multiple components including tumor extension, surgical risk, symptom severity, suspected histology ultimately determine the treatment plan for these patients.<sup>[11]</sup>

There is considerable heterogeneity to these lesions on light microscopy, and they can be hypocellular or hypercellular with stroma that can range anywhere from dense and collagenous to loose and myxoid.<sup>[4]</sup> Either immunohistochemistry or electron microscopy is preferred to identify perineuriomas upon excision. Perineuronal tumors are positive for epithelial cell membrane antigen and claudin-1, a tight junction protein, and negative for neurofilaments and S100 proteins, which are a family of proteins with calcium binding properties. Schwannomas, on the other hand are positive for S100, and neurofilaments, and negative for epithelial cell membrane antigen.<sup>[1]</sup> Though perineuriomas can express CD34, this is not necessary for classification of the lesion.<sup>[12]</sup> In our patient, the immunohistochemistry showed positive epithelial membrane antigen, negative S100 protein, and claudin are unexpected. The negative CD34 does not exclude this lesion from being a perineurioma; however, claudin usually is pos-

itive in these lesions. In our patient, microscopy showed a hypercellular neoplastic lesion with tumor cells arranging in predominately storiform architecture. The tumor cells directly abutted the normal adrenal tissue. Distinct areas of tumor with a myxoid appearance were focally present in the lesion. At high power magnification, the spindle shaped tumor cells demonstrate wavy nuclei with tapered ends.

Finally on gross pathology, a well-circumscribed orange tan lesion was identified within the medulla. This lesion also had areas of hemorrhage, which is also unusual for perineuriomas.<sup>[4]</sup>

Interestingly, the radiological components of this mass are very different than the attributes of retroperitoneal perineurioma reported by Yasumoto et al.<sup>[5]</sup> The attributes of the mass on imaging in that study showed a homogenous hypodense mass with enhancement of 12 Hounsfield units and high intensity on T2 weighted MRI<sup>(5)</sup>. Of note, the radiological differential diagnosis for a soft tissue perineurioma on imaging as detailed by Yasumoto includes neurilemmomas, neurofibromas, ganglioneuromas, and cellular myxomas.<sup>[5]</sup> Due to the presence of hemorrhage on gross cross section in our tumor, it is reasonable to state the presence or absence of hemorrhage is not particularly helpful in ruling out the lesion. This is quite different than the imaging qualities of the perineurioma in our case and demonstrates the varied presentation of this tumor on CT and MRI imaging. The presentation reinforces that a perineurioma should be considered in the differential for a contrast enhancing mass on CT that is T2 hyperintense and nonfunctional on workup.

Unlike adrenal perineuriomas, propofol induced seizure like phenomena have been well reported in the literature, with Walder et al performing the only systematic review of cases to date.<sup>[6-8,13]</sup> In this systematic review, Walder found that most of these cases occurred either during induction of or emergence from anesthesia, suggesting that changing concentrations of propofol also play a role in this neuroexcitation.<sup>[13]</sup> The distinction between seizures and seizure like phenomena is an important one to make clinically, as propofol is often used to treat refractory status epilepticus. In such cases, like the one we present here, a clinician may use propofol to resolve a seizure-like episode and unwittingly propagate further episodes of neuroexcitation. Though this differentiation can be done based on clinical evaluation of the episodes, and an EEG should be done if diagnosis is still unclear as myoclonic seizures have been reported after propofol as well.<sup>[7,14]</sup> EEG was not done for our patient; therefore we cannot definitively rule out that this was a seizure. However, the motor movements and clinical presentation are more consistent with post sedation neuro-excitation versus a seizure.

Despite the episodes resolving in our case after administration of midazolam, there have been no studies to evaluate this treatment and therefore the current recommendation is to provide supportive care of the patient by treating sequelae of these episodes like lactic acidosis and dehydration.<sup>[7]</sup>

In closing, though perineuriomas are exceedingly rare this case demonstrates the necessity of a thorough workup for an incidentally discovered adrenal mass. This workup is vital in ensuring the prevention of overtreatment and we hope that this case will help broaden the differential diagnosis of

nonfunctional adrenal masses. Also, though the literature may ascribe certain immunohistochemical and imaging characteristics for perineuriomas, there is still a wide variability of these non-functional adrenal masses. Finally, we hope that this presentation of propofol frenzy will aid clinicians in thoroughly evaluating and treating patients who have post sedation neuroexcitation after propofol administration.

## CONFLICTS OF INTEREST DISCLOSURE

The authors declare that they have no conflicts of interest.

## REFERENCES

- [1] James MG. Peripheral nerve tumors. In: Jeremy M Shefner M, PhD, Robert Maki, MD, PhD, April F Eichler, MD, MPH editor. UpToDate, Waltham, MA (Accessed on March 16, 2021).
- [2] Lazarus SS, Trombetta LD. Ultrastructural identification of a benign perineurial cell tumor. *Cancer*. 1978; 41(5): 1823-9. PMID: 647630. [https://doi.org/10.1002/1097-0142\(197805\)41:5<1823::AID-CNCR2820410525>3.0.CO;2-J](https://doi.org/10.1002/1097-0142(197805)41:5<1823::AID-CNCR2820410525>3.0.CO;2-J)
- [3] Hornick JL, Fletcher CD. Soft tissue perineurioma: clinicopathologic analysis of 81 cases including those with atypical histologic features. *Am J Surg Pathol*. 2005; 29(7): 845-58. PMID: 15958848. <https://doi.org/10.1097/01.pas.0000155166.86409.d2>
- [4] Macarenco RS, Ellinger F, Oliveira AM. Perineurioma: a distinctive and underrecognized peripheral nerve sheath neoplasm. *Arch Pathol Lab Med*. 2007; 131(4): 625-36. PMID: 17425397. [https://doi.org/10.1043/1543-2165\(2007\)131\[625:PADAUP\]2.0.CO;2](https://doi.org/10.1043/1543-2165(2007)131[625:PADAUP]2.0.CO;2)
- [5] Yasumoto M, Katada Y, Matsumoto R, et al. Soft-tissue perineurioma of the retroperitoneum in a 63-year-old man, computed tomography and magnetic resonance imaging findings: a case report. *J Med Case Rep*. 2010; 4: 290. PMID: 20738883. <https://doi.org/10.1186/1752-1947-4-290>
- [6] Islander G, Vinge E. Severe neuroexcitatory symptoms after anaesthesia—with focus on propofol anaesthesia. *Acta Anaesthesiol Scand*. 2000; 44(2): 144-9. PMID:10695906. <https://doi.org/10.1034/j.1399-6576.2000.440203.x>
- [7] Carvalho DZ, Townley RA, Burkle CM, et al. Propofol Frenzy: Clinical Spectrum in 3 Patients. *Mayo Clin Proc*. 2017; 92(11): 1682-7. PMID: 29101936. <https://doi.org/10.1016/j.mayocp.2017.08.022>
- [8] Hickey KS, Martin DF, Chuidian FX. Propofol-induced seizure-like phenomena. *J Emerg Med*. 2005; 29(4): 447-9. PMID: 16243205. <https://doi.org/10.1016/j.jemermed.2005.05.009>
- [9] Tam MK, Irwin MG, Tse ML, et al. Prolonged myoclonus after a single bolus dose of propofol. *Anaesthesia*. 2009; 64(11): 1254-7. PMID: 19825064. <https://doi.org/10.1111/j.1365-2044.2009.06035.x>
- [10] Hirose T, Scheithauer BW, Sano T. Perineurial malignant peripheral nerve sheath tumor (MPNST): a clinicopathologic, immunohistochemical, and ultrastructural study of seven cases. *Am J Surg Pathol*. 1998; 22(11): 1368-78. PMID: 9808129. <https://doi.org/10.1097/00000478-199811000-00007>
- [11] Heinen C, Schmidt T, Kretschmer T. Decision Making in Retroperitoneal Nerve Sheath and Nerve-Associated Tumors: A Modular Approach. *Neurosurgery*. 2020; 87(3): E359-E69. PMID: 32109286. <https://doi.org/10.1093/neuros/nyaa020>
- [12] Fox MD, Gleason BC, Thomas AB, et al. Extra-acral cutaneous/soft tissue sclerosing perineurioma: an under-recognized entity in the differential of CD34-positive cutaneous neoplasms. *J Cutan Pathol*. 2010; 37(10): 1053-6. PMID: 20412342. <https://doi.org/10.1111/j.1600-0560.2010.01549.x>
- [13] Walder B, Tramer MR, Seeck M. Seizure-like phenomena and propofol: a systematic review. *Neurology*. 2002; 58(9): 1327-32. PMID: 12017156. <https://doi.org/10.1212/wnl.58.9.1327>
- [14] Jeon HW, Kang JH, Kim HS, et al. A case of propofol-induced delayed-onset refractory myoclonic seizures. *J Clin Neurol*. 2007; 3(3): 154-7. PMID: 19513284. <https://doi.org/10.3988/jcn.2007.3.3.154>